DIAGNOSI ANATOMOPATOLOGICA ED ASPETTI MOLECOLARI

Dr. Luca Albarello

U.O. di Anatomia Patologica

Ospedale San Raffaele - Milano

Presezzo, 13/10/2018

1) DIAGNOSI DI ISTOTIPO +
PARAMETRI PROGNOSTICI

2) STADIAZIONE PATOLOGICA

3) PARAMETRI PREDITTIVI

Adenocarcinoma scarsamente differenziato del grosso intestino (rif. a) infiltrante il connettivo periviscerale.
Margini di resezione su pezzo chirurgico e margine radiale indenni da neoplasia.
Metastasi in 4 su 32 linfonodi periviscerali.

- Neuroinvasione: assente (rif. f).
- Distanza minima dal margine di scollamento circonferenziale (margine radiale) (rif. g): 12 mm.
- Profondità di infiltrazione del connettivo periviscerale: 7 mm (rif. h).

Valutazione dell'espressione immunoistochimica delle proteine del sistema enzimatico MMR ("DNA Mismatch Repair", deputato alla correzione di appaiamenti scorretti delle basi nel DNA) su tessuto neoplastico.
- MSH2 (clone G219-1129): cellule carcinomatose con immunoreattività preservata;
- MLH1 (clone M1): cellule carcinomatose con immunoreattività non preservata;
- MSH6 (clone 44): cellule carcinomatose con immunoreattività preservata;
- PMS2 (clone EPR3947): cellule carcinomatose con immunoreattività non preservata.
Si osserva espressione di PD-L1 nel 20% della componente neoplastica.
(Valutazione dell'espressione di PD-L1 con anticorpo clone 22C3 su sezione istologica in paraffina; piattaforma Ventana):

Stadio TNM (rif. i): pT3(V1), pN2a, G3.

Riferimenti metodologici:
(a) WHO Classification of Tumours. IARC 2010.
(b) Valutazione espressa come: espansiva, infiltrativa (Jass, 1987).
(c) Valutazione espressa come: assente, lieve, moderata, marcata (modificato da Jass, 1987).
(d) Valutazione espressa come: assente, presente (Graham, 1990).
(e) Score di riferimento: 0-9 foci/250x = basso grado; >=10 foci/250x = alto grado (Ueno, 2004).
(f) Valutazione espressa come: osservata; non osservata.
(g) Distanza misurata microscopicamente ed espressa in millimetri (Nagtegaal, Am J Surg Pathol, 2002).
(h) Profondità misurata in mm (UICC, TNM Supplement, 4th edition, pag. 194).
(i) UICC: TNM 8th Edition - 2017.



o:

WORL… IZATION
CLAS… MOURS

WHO Classifi… estive System

Intern… Cancer

Epithelial tumours	
Premalignant lesions	
Adenoma	8140/0
Tubular	8211/0
Villous	8261/0
Tubulovillous	8263/0
Dysplasia (intraepithelial neoplasia), low grade	8148/0*
Dysplasia (intraepithelial neoplasia), high grade	8148/2
Serrated lesions	
Hyperplastic polyp	
Sessile serrated adenoma/polyp	8213/0*
Traditional serrated adenoma	8213/0*

Premalignant epithelial tumours

(WHO 2010)

Macroscopic classification

- Sessile
- Pedunculated

Microscopic classification

- *Adenoma*
  - tubular
  - villous
  - tubulovillous

- *"Serrated" lesions*
  - Hyperplastic polyp (HP)
  - Sessile Serrated Adenoma / Polyp (SSA/P)
  - Traditional Serrated Adenoma (TSA)

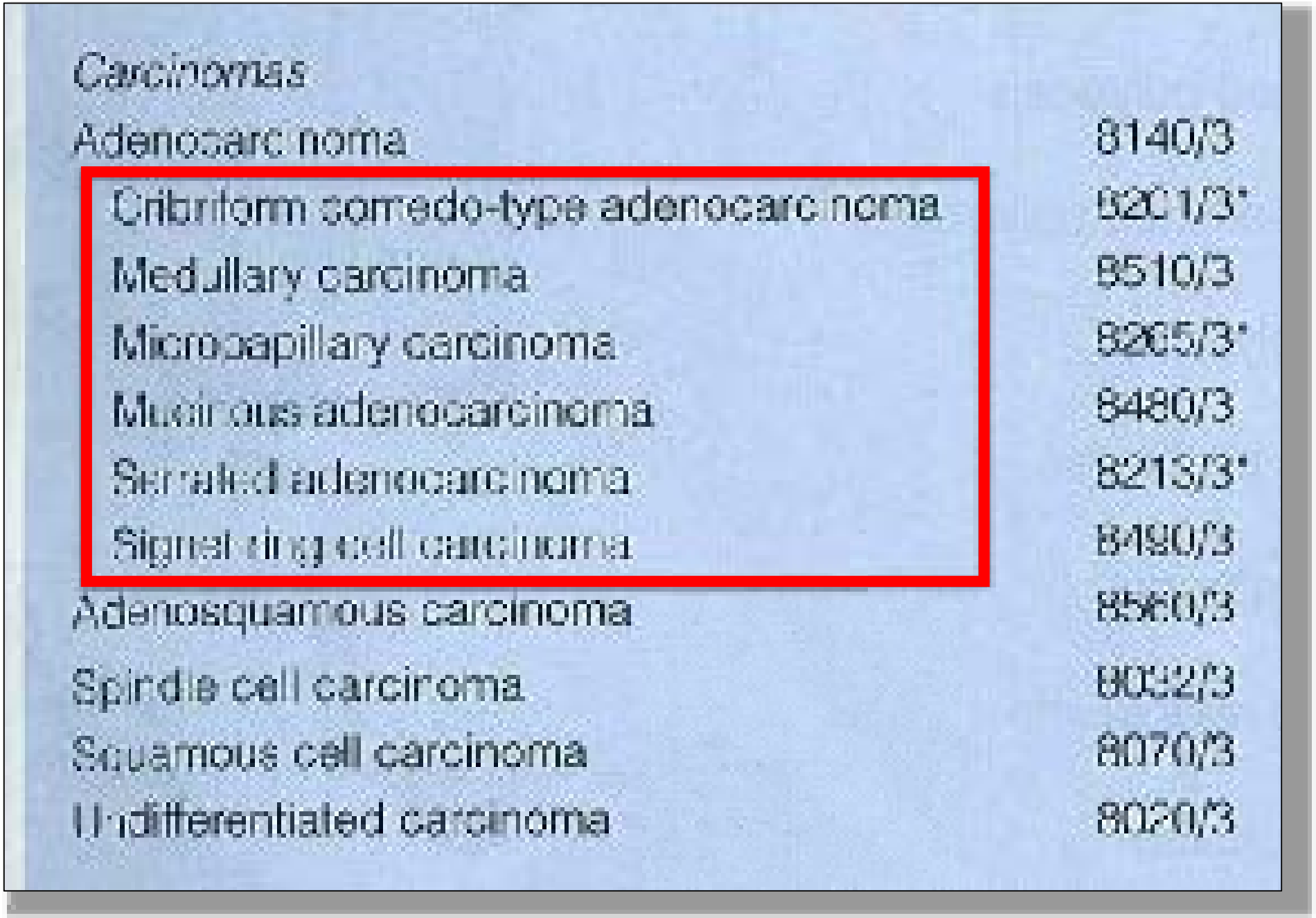
Carcinomas
Adenocarcinoma 8140/3
Cribriform comedo-type adenocarcinoma 8201/3*
Medullary carcinoma 8510/3
Microcapillary carcinoma 8265/3*
Mucinous adenocarcinoma 8480/3
Serrated adenocarcinoma 8213/3*
Signet ring cell carcinoma 8490/3
Adenosquamous carcinoma 8560/3
Spindle cell carcinoma 8032/3
Squamous cell carcinoma 8070/3
Undifferentiated carcinoma 8020/3

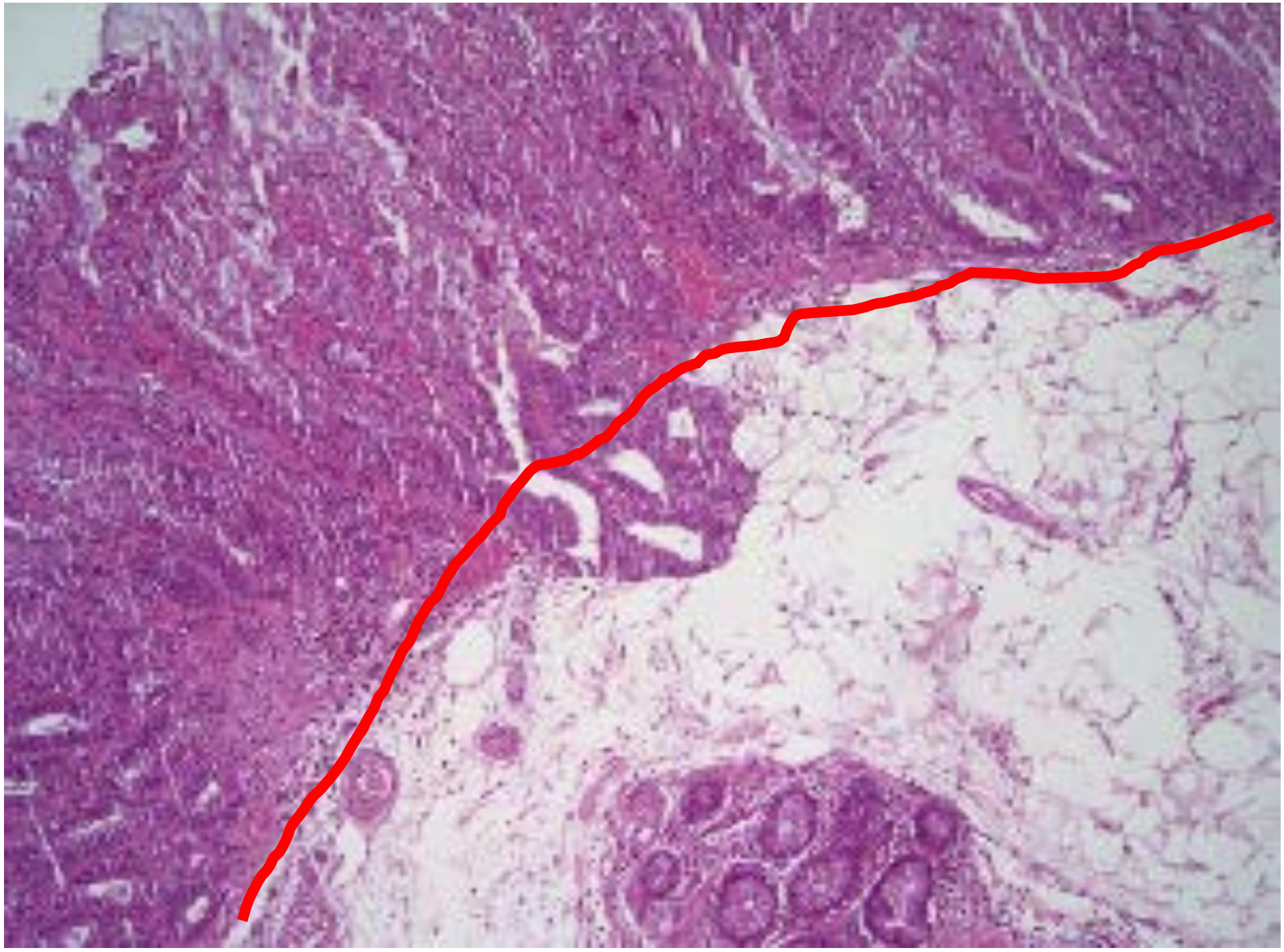

Nella patologia neoplastica epiteliale del grosso intestino

ADENOCARCINOMA INFILTRANTE DEL GROSSO INTESTINO

MUCOSAE.

Problema del “superamento della membrana basale”…
Problema dei linfatici della lamina propria…

Si valutano i seguenti caratteri istoprognostici.

- **Modalità di crescita:** espansiva (rif. b).
- **Infiltrato linfoide peritumorale:** moderato (rif. c).
- **Reazione desmoplastica stromale:** moderata (rif. c).
- **Reazione Crohn's-like:** presente (rif. d).
- **Budding peritumorale:** alto grado (13 foci/250x) (rif. e).
- **Angioinvasione:** presente (rif. f).
- **Linfoinvasione:** assente (rif. f).
- **Neuroinvasione:** assente (rif. f).
- **Distanza minima dal margine di scollamento circonferenziale (margine radiale)** (rif. g)**:** 12 mm.
- **Profondità di infiltrazione del connettivo periviscerale:** 7 mm (rif. h).

Riferimenti metodologici:
(a) WHO Classification of Tumours. IARC 2010.
(b) Valutazione espressa come: espansiva, infiltrativa (Jass, 1987).
(c) Valutazione espressa come: assente, lieve, moderata, marcata (modificato da Jass, 1987).
(d) Valutazione espressa come: assente, presente (Graham, 1990).
(e) Score di riferimento: 0-9 foci/250x = basso grado; >=10 foci/250x = alto grado (Ueno, 2004).
(f) Valutazione espressa come: osservata; non osservata.
(g) Distanza misurata microscopicamente ed espressa in millimetri (Nagtegaal, Am J Surg Pathol, 2002).
(h) Profondità misurata in mm (UICC, TNM Supplement, 4th edition, pag. 194).
(i) UICC: TNM 8th Edition - 2017.

Tumor budding

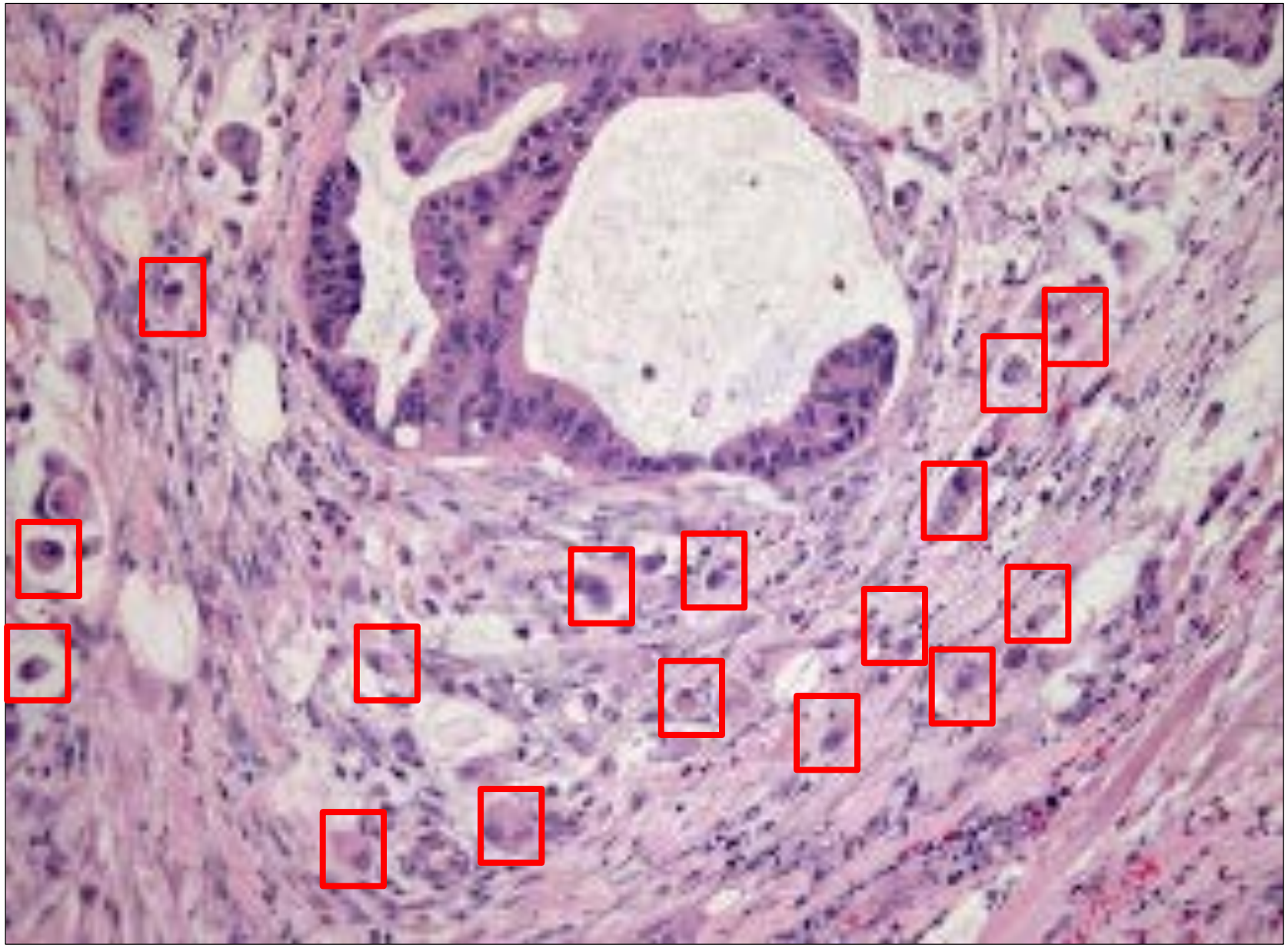

Tumor budding – *a histologic 'snapshot' of EMT*

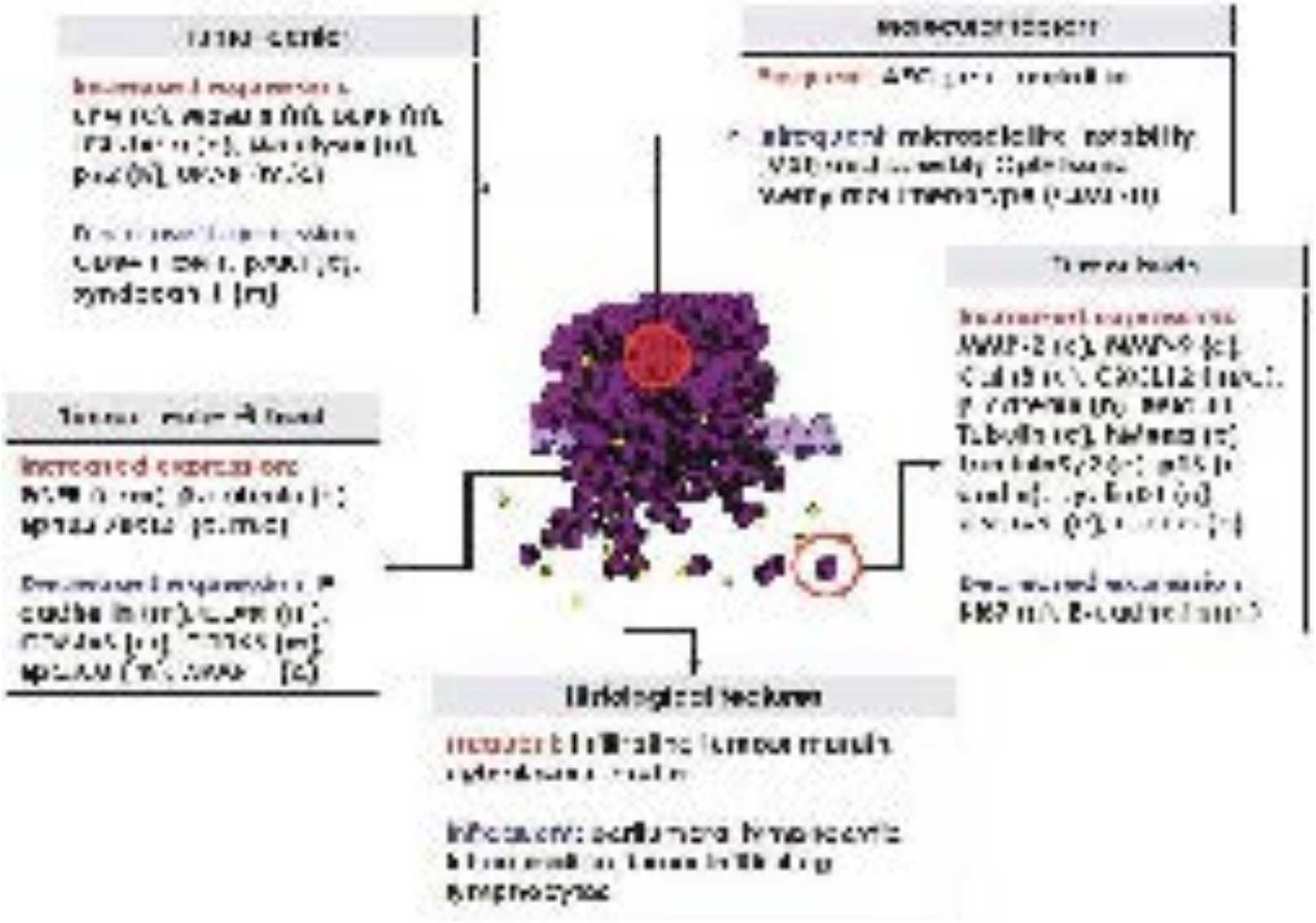

Zlobec I, et al., Oncotarget 2010; 1: 651 - 661

Tumor budding – *clinical significance*

Paper	Patients	Results
Ueno 2004 (*Gastro*)	292 Stage I	Independent prognostic factor
Ueno 2004 (*Ann Surg*)	638 Stage II & III	Independent prognostic factor
Wang 2005 (*Dis Colon*)	159 Stage I	10.1% pt with LN-mets
Park 2004 (*Dis Colon*)	109 Stage II & III	(1)61.5% had ITC (2)degree of TB correlated with ITC
Okuyama 2003 (*Dis Colon*)	196 Stage II	(1)43.3% of tumors showed budding (2)Significantly associated with LN mets (3)Independent prognostic factor
Tanaka 2003 (*Dis Colon*)	138 Stage II	Only budding associated with recurrence
Okuyama 2003 (*J Surg Onc*)	83 pT3	Lower overall survival (51.8% vs. 85%, P<0.002)
Shinto 2006 (*Dis Colon*)	136 Stage II & III	(1)Lymph node mets (P<0.0001) (2)High recurrence rate (P=0.0022)
Kajiwara 2010 (*Dis Colon*)	244 Stage II	Significant LN met risk
Homma 2010 (*J Surg Oncol*)	65 Stage II	Significant LN mets (P=0.002)

Tumor budding – *scoring systems*

Paper	n	Stain	Scoring system
Morodomi 1998 (*Cancer)*	40 CRC	H&E	Count performed at four locations (1.25mm^2 field area) and average calculated
Hase 1993 (*Dis Colon)*	663 CRC	H&E	N/A: classified according to subjective impression
Ueno 2002 (*Histopath.)*	638 CRC	H&E	10 or more buds in 25X field (0.385mm^2)
Okuyama 2003 (*Dis Colon*)	196 CRC	H&E	N/A: classified according to subjective impression
Jass 2003 (*J Clin Path)*	95 CRC	H&E	5 buds in 40X field (area not specified)
Guzinska K 2005 (*Antican)*	24 CRC	H&E	Any budding considered positive
Ha 2005 (*Korean Can Ass)*	90 CRC	H&E	>7 buds in 20X field (area not specified)
Kanazawa 2008 *(Col Dis)*	159 CRC	H&E	0-1/3: mild; 1/3-2/3: moderate; >2/3: marked
Wang 2009 (*AJSP)*	128 CRC	H&E	5 fields (20X, 0.95mm^2); a median count of 1 or more buds considered positive

Tumor budding in HSR

Ueno's criteria:

Tumor buds: 1-5 cells; 20x hpf (= 0.385 mm²)

Low grade budding: <5 buds in a 20x hpf
Borderline budding: 5-9 buds in a 20x hpf
High grade budding: >10 buds in a 20x hpf

Ueno H, *et al*., A new prognostic staging system for rectal cancer. Annals of surgery, 2004. 240(5): p. 832-9.

Tumor budding

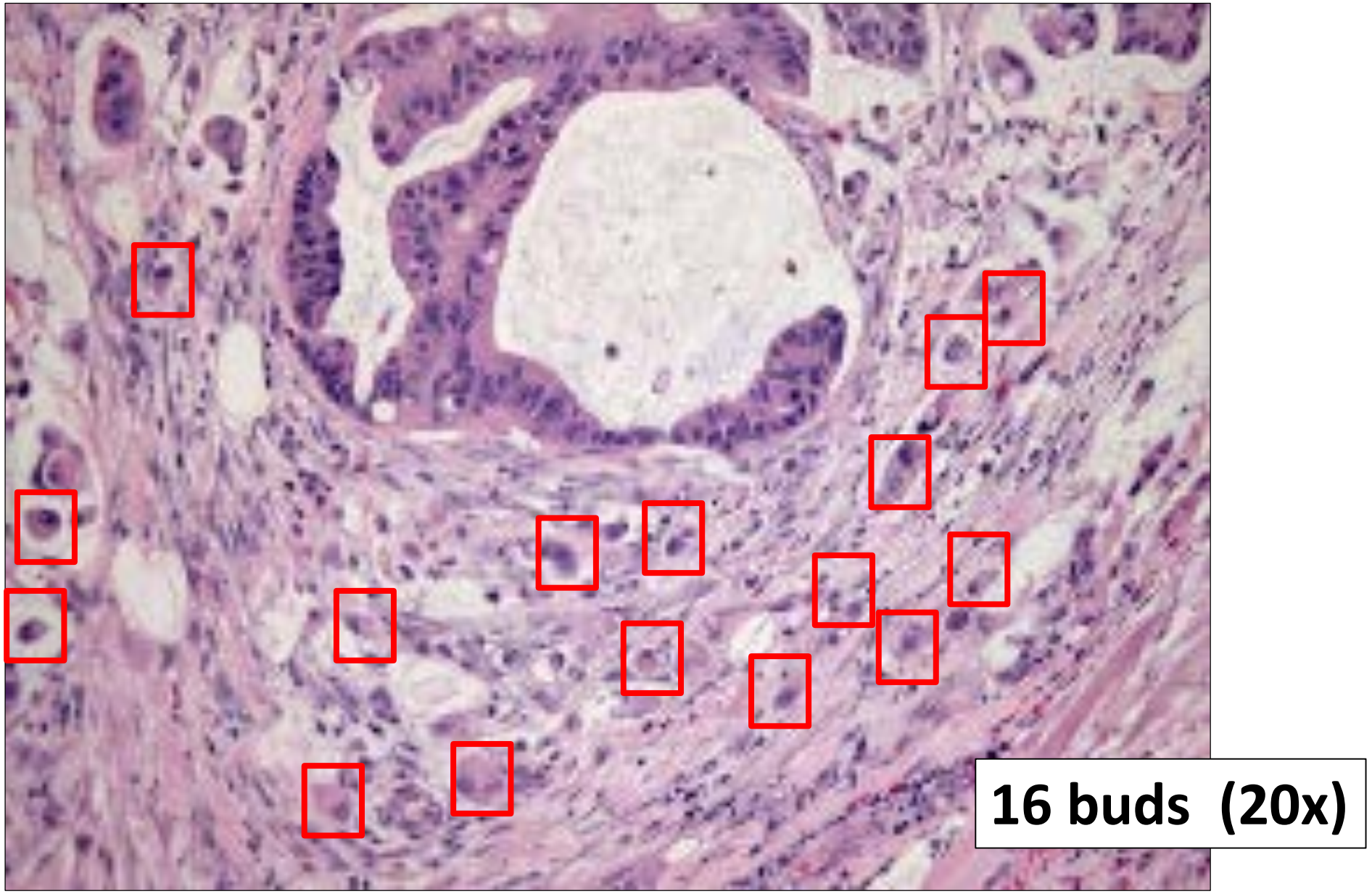

1) DIAGNOSI DI ISTOTIPO +

PARAMETRI PROGNOSTICI

2) STADIAZIONE PATOLOGICA

3) PARAMETRI PREDITTIVI

HSR Pathology report:

general references for calssification of exocrine epithelial tumours

Histological typing:

- World Health Organization Classification of Tumours. WHO Classification of Tumours of the Digestive System

IARC Press: Lyon 2010.

Pathological staging:

- International Union Against Cancer (UICC): TNM Classification of Malignant Tumours

8th ed.; Brierley, Gospodarowicz, Wittekind eds.

New York: Wiley 2017

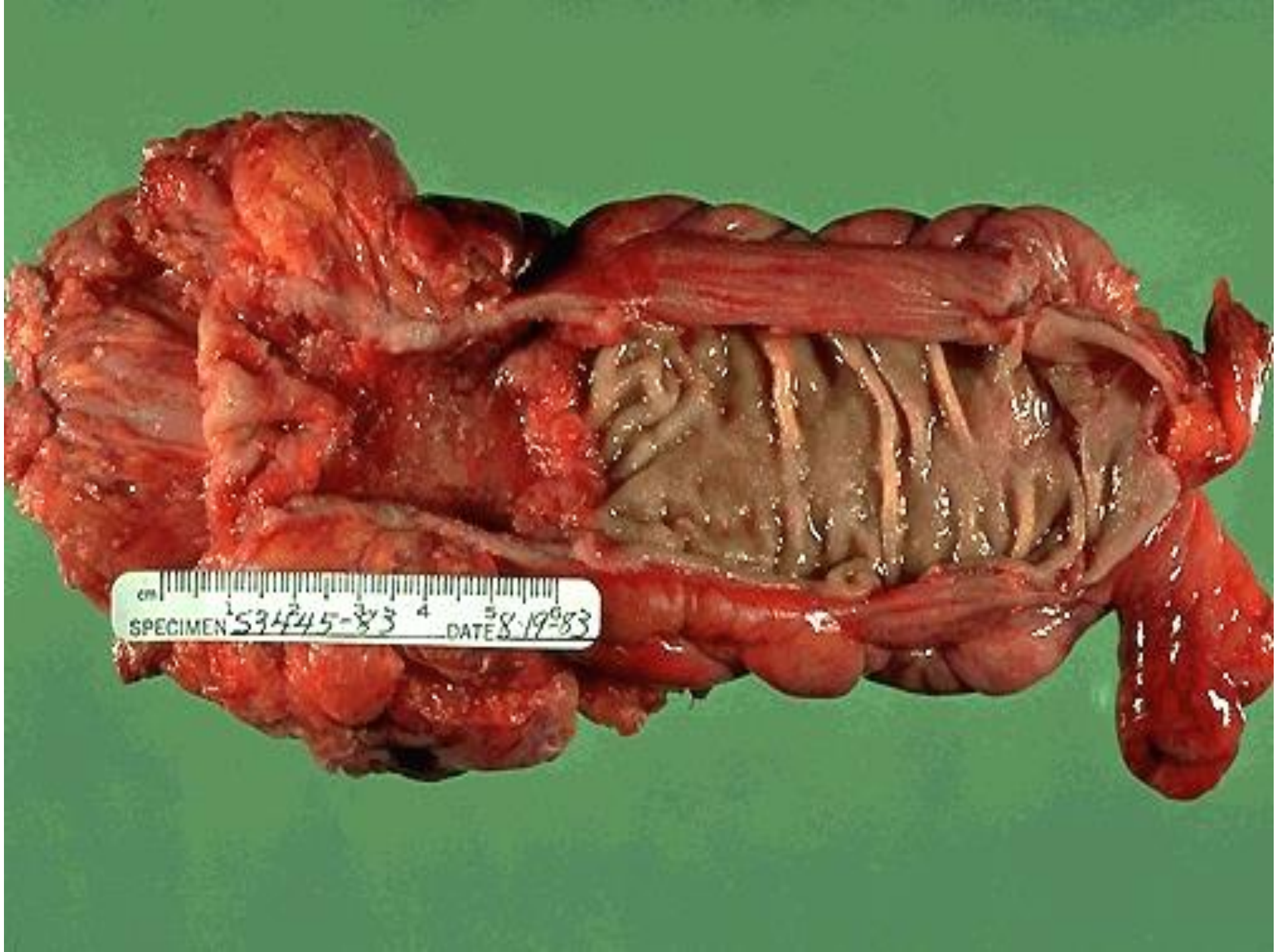
SPECIMEN S34245-83
DATE 8-19-83

pTNM classification - Colon and Rectum

UICC: TNM 8th ed. 2017

Primary Tumor (pT)

pTX: Cannot be assessed
pT0: No evidence of primary tumor
pTis: Carcinoma in situ: invasion of lamina propria
pT1: Tumor invades submucosa
pT2: Tumor invades muscularis propria
pT3: Tumor invades subserosa or pericolic or perirectal tissues
pT4: Tumor invades other organs or structures and or perforates perit.
- **pT4a:** tumor peforates visceral peritoneum.
- **pT4b:** Tumor invades other organs or structures

pTNM classification - Colon and Rectum

UICC: TNM 8th ed. 2017

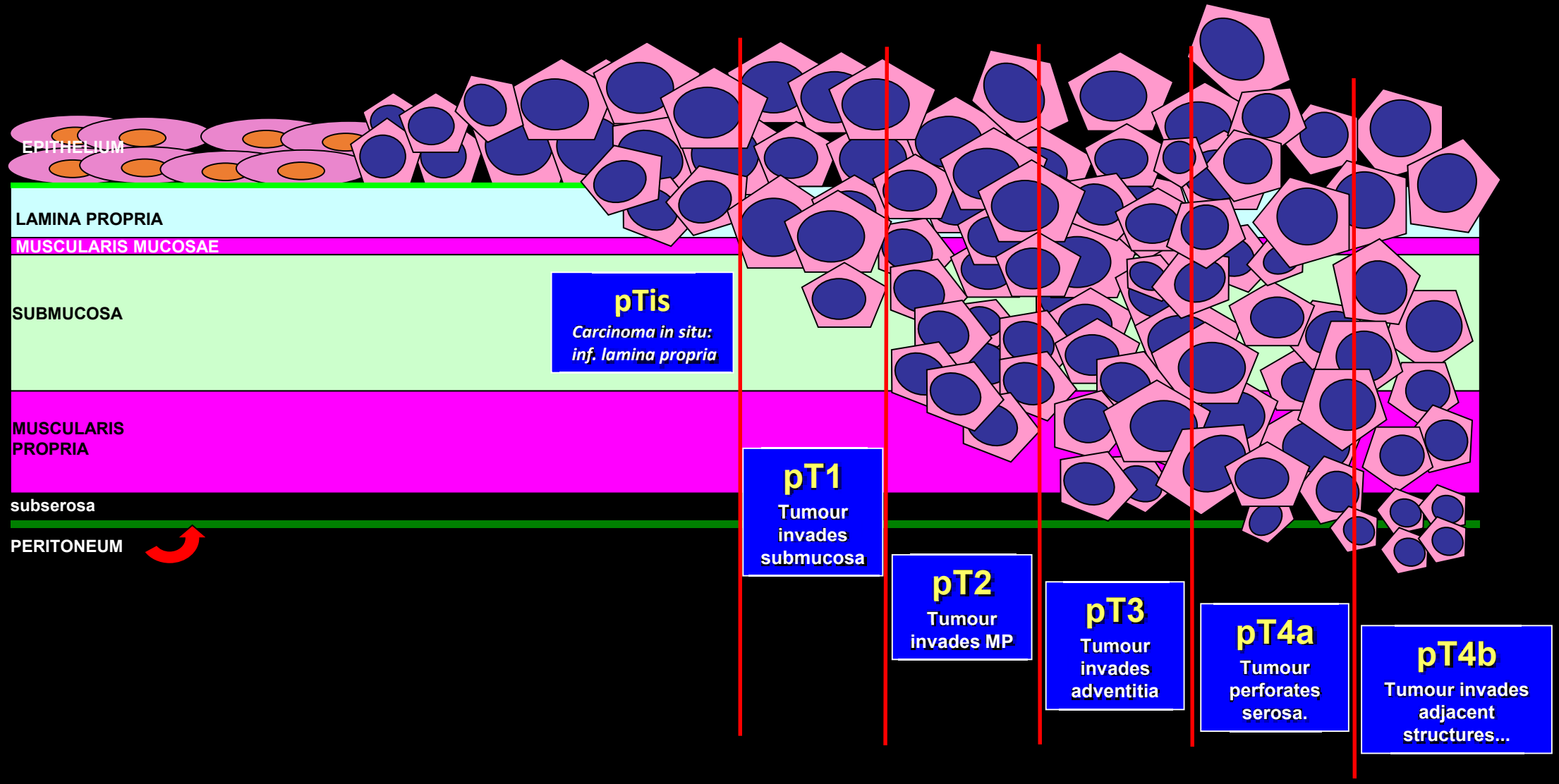

AJCC TNM (8th edition)

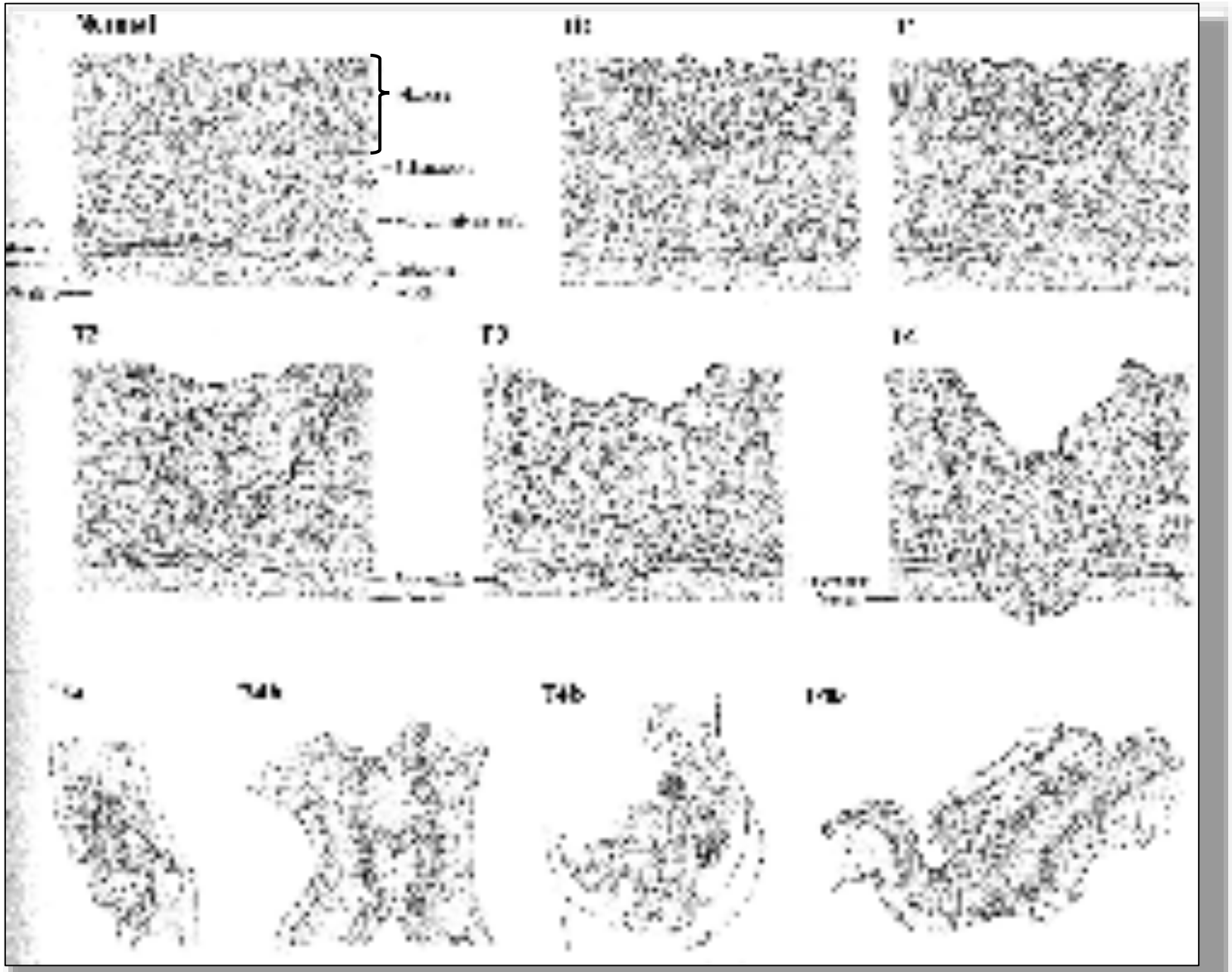

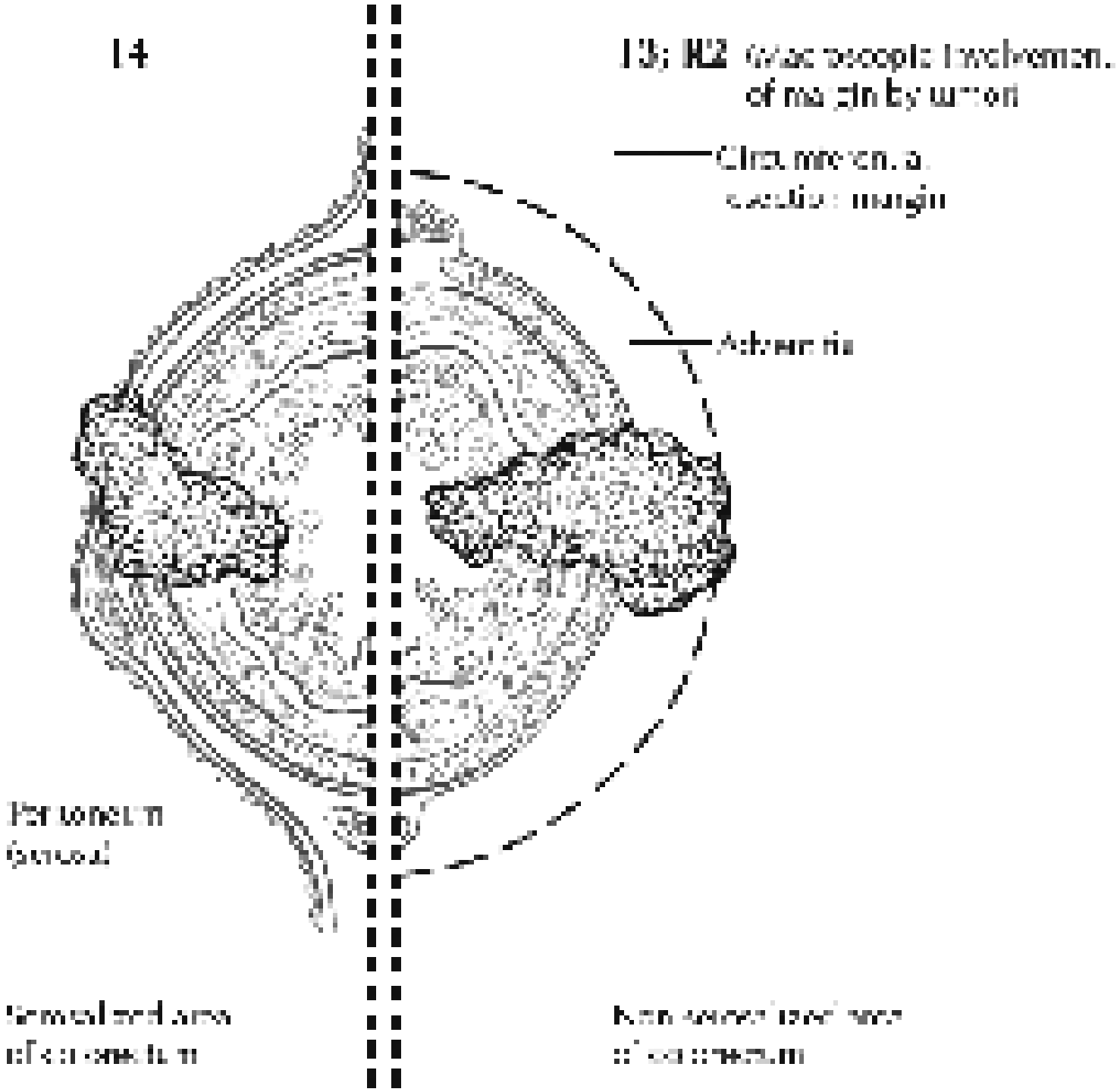
14
13; R2
Circumferential resection margin
Adventitia
Peritoneum (visceral)

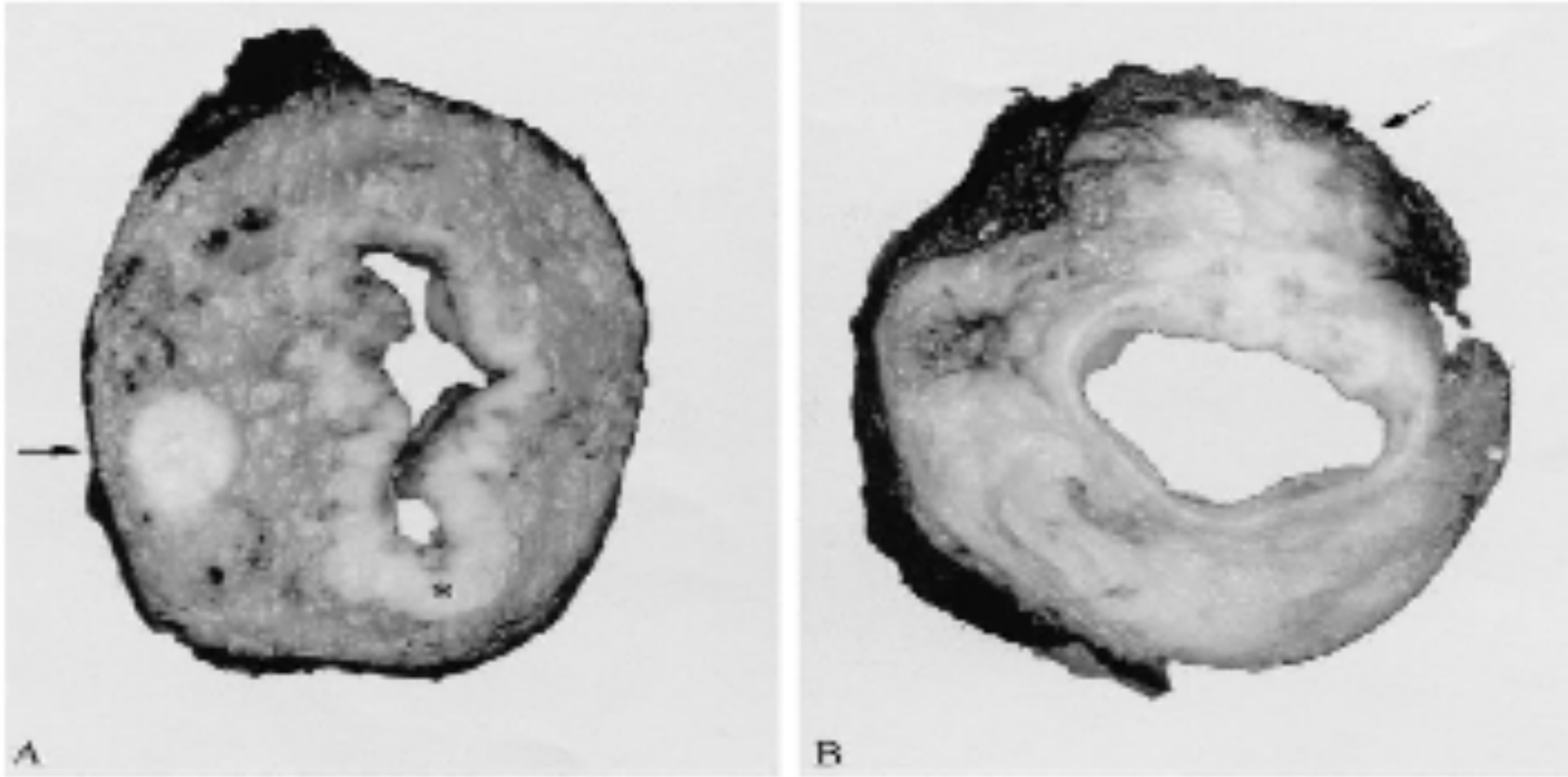

FIG. 1. Macroscopic view of the circumferential margin in resection specimens. (A) Positive margin: tumor close to the resection margin, as indicated by the arrow (primary tumor). (B) Primary tumor invading but not reaching the soft tissue close to the circumferential margin, as indicated by the arrow.

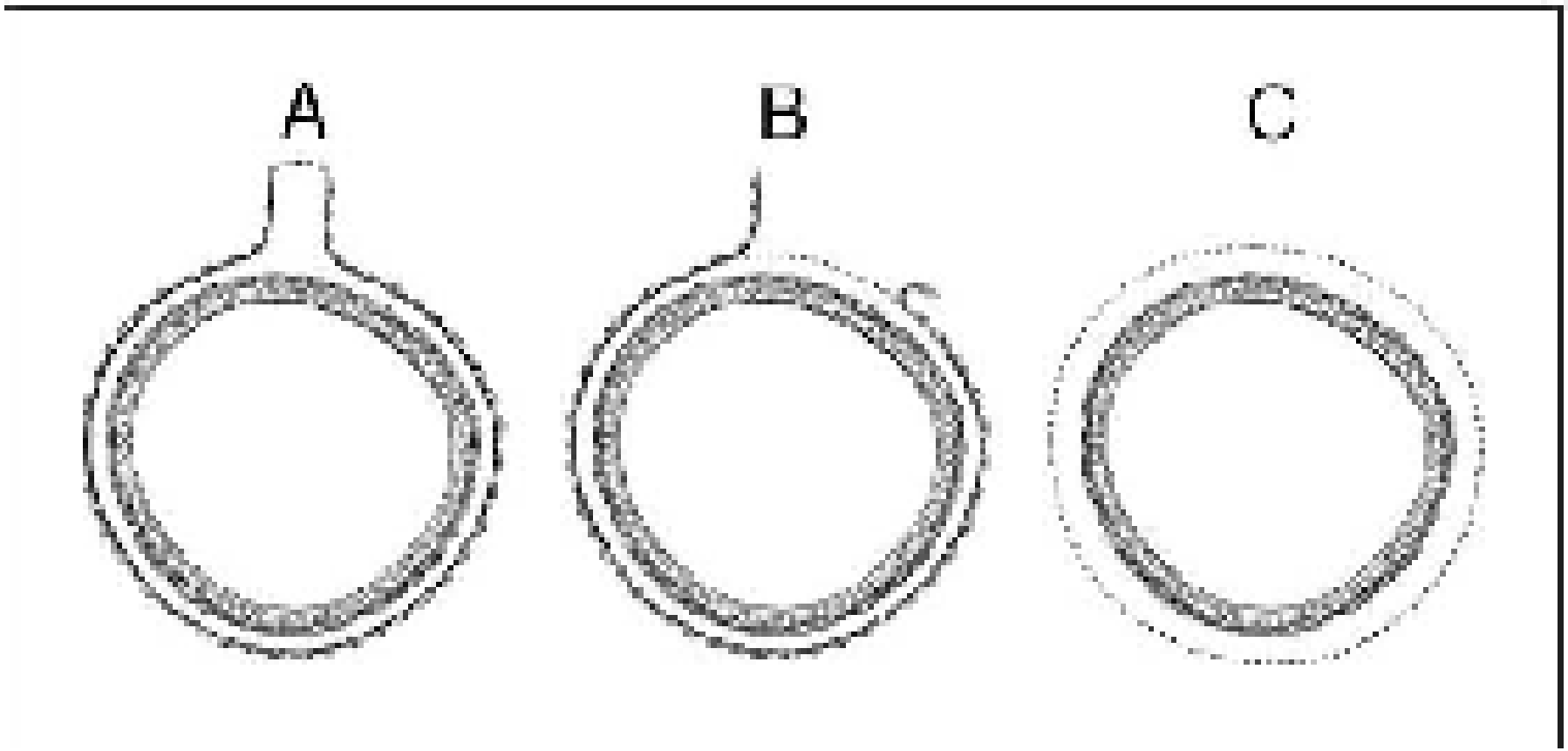

Figure 3. *A, Mesenteric margin in portion of colon completely encased by peritoneum (dotted line). B, Circumferential margin (dotted line) in portion of colon incompletely encased by peritoneum. C, Circumferential margin (dotted line) in rectum, completely uncased by peritoneum.*

Adenocarcinoma scarsamente differenziato del grosso intestino (rif. a) infiltrante il connettivo periviscerale.
Margini di resezione su pezzo chirurgico e margine radiale indenni da neoplasia.
Metastasi in 4 su 32 linfonodi periviscerali.
Si valutano i seguenti caratteri istoprognostici.
- Modalità di crescita: espansiva (rif. b).
- Infiltrato linfoide peritumorale: moderato (rif. c).
- Reazione desmoplastica stromale: moderata (rif. c).
- Reazione Crohn's-like: presente (rif. d).
- Budding peritumorale: alto grado (13 foci/250x) (rif. e).

TRG

deputato alla correzione di appaiamenti scorretti delle basi nel DNA) su tessuto neoplastico.
- MSH2 (clone G219-1129): cellule carcinomatose con immunoreattività preservata;
- MLH1 (clone M1): cellule carcinomatose con immunoreattività non preservata;
- MSH6 (clone 44): cellule carcinomatose con immunoreattività preservata;
- PMS2 (clone EPR3947): cellule carcinomatose con immunoreattività non preservata.
Si osserva espressione di PD-L1 nel 20% della componente neoplastica.
(Valutazione dell'espressione di PD-L1 con anticorpo clone 22C3 su sezione istologica in paraffina; piattaforma Ventana):

Stadio TNM (rif. i): pT3(V1), pN2a, G3.

Riferimenti metodologici:
(a) WHO Classification of Tumours. IARC 2010.
(b) Valutazione espressa come: espansiva, infiltrativa (Jass, 1987).
(c) Valutazione espressa come: assente, lieve, moderata, marcata (modificato da Jass, 1987).
(d) Valutazione espressa come: assente, presente (Graham, 1990).
(e) Score di riferimento: 0-9 foci/250x = basso grado; >=10 foci/250x = alto grado (Ueno, 2004).
(f) Valutazione espressa come: osservata; non osservata.
(g) Distanza misurata microscopicamente ed espressa in millimetri (Nagtegaal, Am J Surg Pathol, 2002).
(h) Profondità misurata in mm (UICC, TNM Supplement, 4th edition, pag. 194).
(i) UICC: TNM 8th Edition - 2017.

JOURNAL OF CLINICAL ONCOLOGY ORIGINAL REPORT

Prognostic Significance of Tumor Regression After Preoperative Chemoradiotherapy for Rectal Cancer

[illegible]

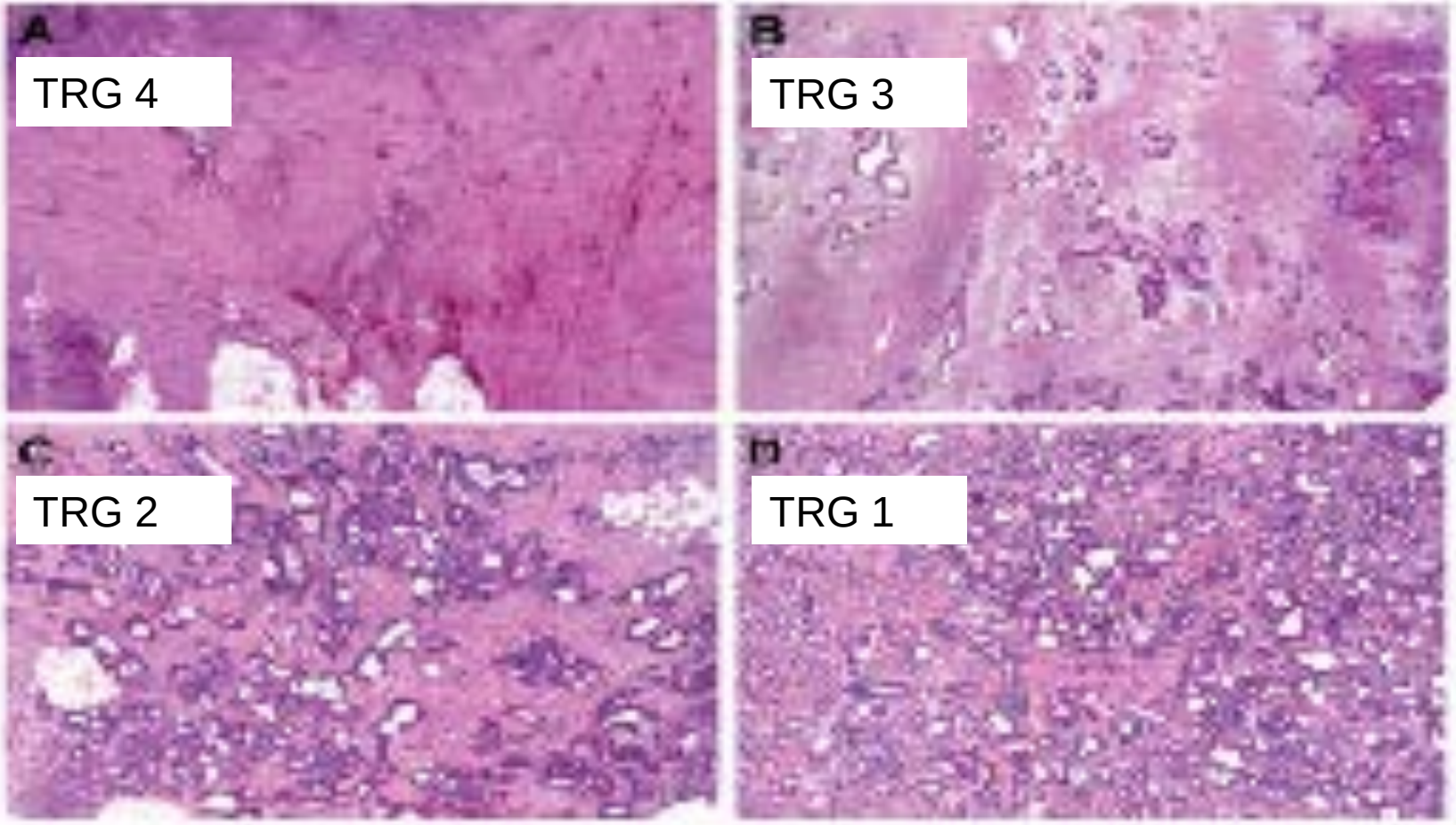

[illegible]

Grado di regressione tumorale dopo terapia neoadiuvante (TRG)

- ***TRG***. Nel caso di neoplasia sottoposta a chemio- e/o radioterapia neoadiuvante si applica un sistema di graduazione finalizzato a valutare la risposta alla terapia. Il grado di regressione tumorale (TRG, "Tumour Regression Grade") è classificato con valori da 0 a 4 (Rödel e coll., Journal of Clinical Oncology, 2005, 34: 8688-8696).

Schematicamente:

- **grado "0"** = non si osserva regressione.
- **grado "1"** = scarsa regressione: prevale il tumore, la fibrosi costituisce meno del 26% della massa tumorale;
- **grado "2"** = moderata regressione: prevale il tumore, la fibrosi costituisce il 26-50% della massa tumorale;
- **grado "3"** = marcata regressione: prevale la regressione, la fibrosi costituisce più del 50% della massa tumorale;
- **grado "4"** = completa regressione: assenza di tumore.

pTNM classification - Colon and Rectum

UICC: TNM 8th ed. 2017

Regional Lymph Nodes (pN)

pNX: Cannot be assessed
pN0: No regional lymph node metastasis
pN1a: **M**etastasis in 1 regional lymph node
pN1b: **M**etastasis in 2 to 3 regional lymph nodes
pN1c: Tumor deposit(s) in the subserosa, or non-peritonealized pericolic or perirectal tissues without regional lymph node metastasis
pN2a: Metastasis in 4 to 6 regional lymph nodes
pN2b: Metastasis in 7 or more regional lymph nodes

Distant Metastasis (pM)

pM0: No distant metastasis
pM1: Distant metastasis
- pM1a: 1 organ
- pM1b: more than 1 organ
- pM1c: peritonaeum…

1) DIAGNOSI DI ISTOTIPO +

PARAMETRI PROGNOSTICI

2) STADIAZIONE PATOLOGICA

3) PARAMETRI PREDITTIVI

Adenocarcinoma scarsamente differenziato del grosso intestino (rif. a) infiltrante il connettivo periviscerale.
Margini di resezione su pezzo chirurgico e margine radiale indenni da neoplasia.

La valutazione dell'espressione immunoistochimica delle proteine del sistema enzimatico MMR ("DNA Mismatch Repair", deputato alla correzione di appaiamenti scorretti delle basi nel DNA) su tessuto neoplastico viene effettuata in osservanza delle vigenti norme (rif. a), fornisce una valutazione sensibile e specifica dello stato di instabilità microsatellitare del tumore (rif. b) e ha evidenziato i seguenti risultati.
- MSH2 (clone G219-1129): cellule carcinomatose con immunoreattività NON PRESERVATA;
- MLH1 (clone M1): cellule carcinomatose con immunoreattività preservata;
-
-

N
Il
o
C

--

Ri
(a)
pr
(b)

Riferimenti metodologici:

(a) Decreto Regione Lombardia n. 4498 del 3/06/2015. Rete Oncologica Lombarda – ROL: Approvazione del documento tecnico “Requisiti minimi per la gestione diagnostica delle lesioni preneoplastiche del carcinoma del colon-retto e standard di refertazione anatomo-patologica”.

(f) Valutazione espressa come: osservata; non osservata.
(g) Distanza misurata microscopicamente ed espressa in millimetri (Nagtegaal, Am J Surg Pathol, 2002).
(h) Profondità misurata in mm (UICC, TNM Supplement, 4th edition, pag. 194).
(i) UICC: TNM 8th Edition - 2017.

GENOMIC INSTABILITY PATHWAYS: CIN, MSI, CIMP

The rate of mutations per nucleotide base pair is estimated to be as low as 10^{-9} per cellular generation.

Cancer cells must acquire some form of intrinsic genomic instability, a "mutator phenotype", that increases their rate of new mutations. Multiple genetic events → genomic instability → tumor progression.

In colon cancer, at least 3 distinct pathways of genomic instability have been described,

- chromosomal instability (CIN),
- microsatellite instability (MSI),
- CpG island methylator phenotype (CIMP).

GASTROENTEROLOGY 2010 138, 2059-2072

CIN
Chromosomal
INstability pathway

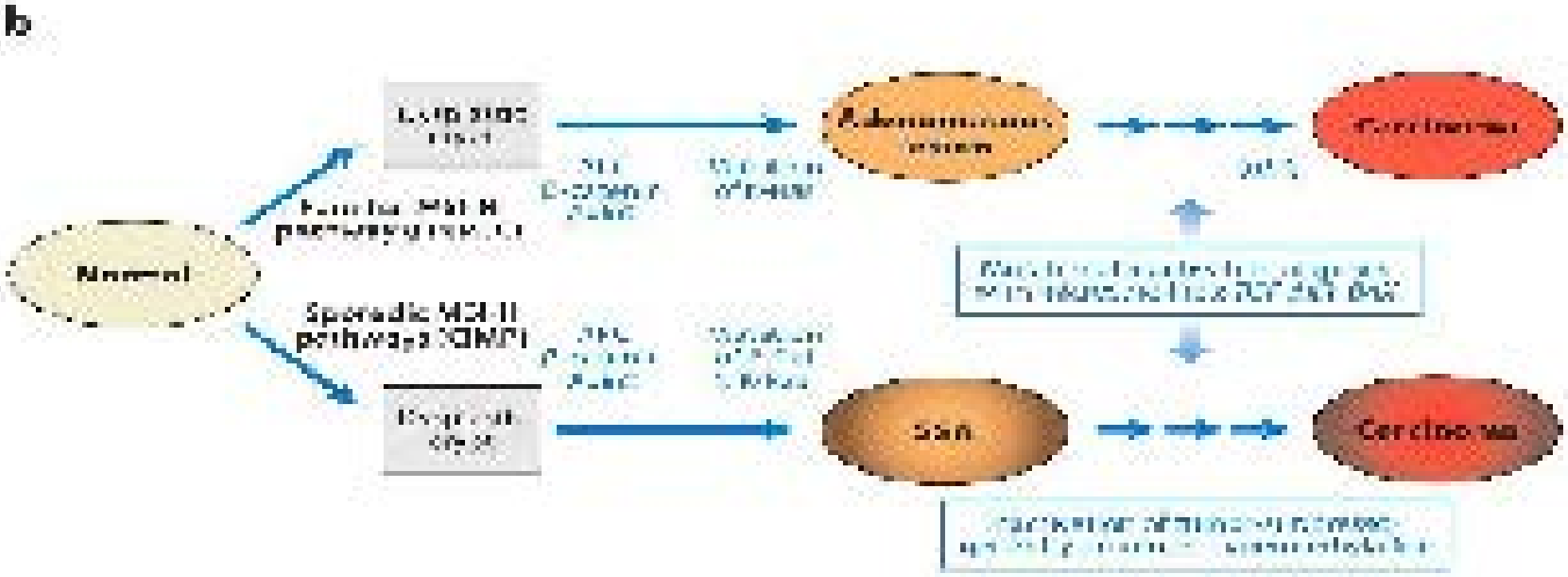

MSI
Micro
Satellite
Instability pathway

CIMP
CpG
Island
Methylator
Phenotype pathway

ANNU REV PATHOL MECH DIS 2011 6 479,

SEQUENZA ADENOMA-CARCINOMA

CIN
Chromosomal
INstability pathway

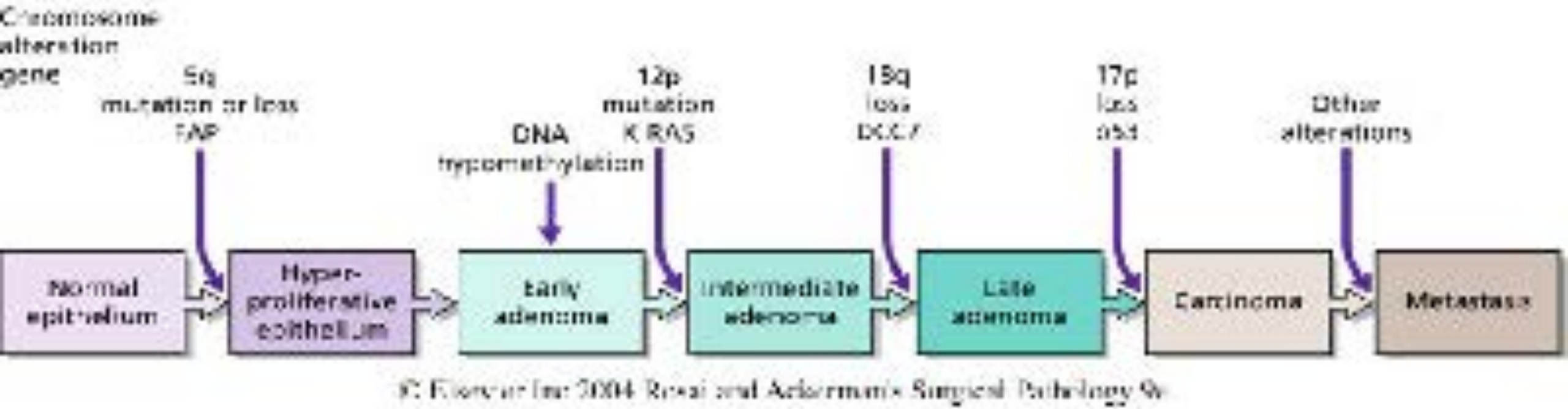

CANCRO CON FENOTIPO MSS

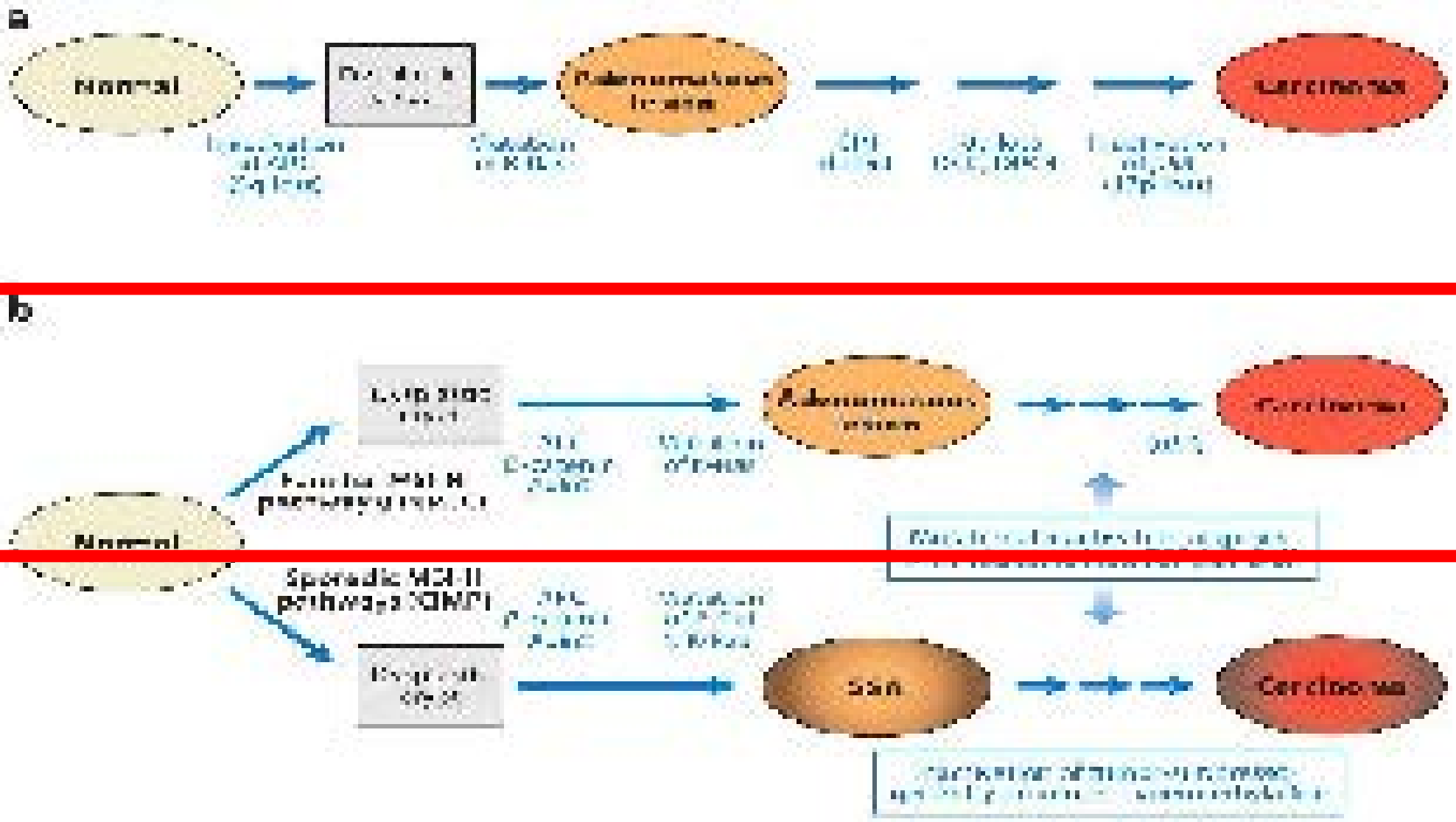

CIN
Chromosomal
INstability pathway

MSI
Micro
Satellite
Instability pathway

CIMP
CpG
Island
Methylator
Phenotype pathway

ANNU REV PATHOL MECH DIS 2011 6 479,

MicroSatellite Instability

Microsatellite sequences (microsatellites) are repetitive DNA sequences usually several base pairs in length.

Microsatellite sequences are composed of non-coding DNA and are not parts of genes.

They are used as genetic markers to follow the inheritance of genes in families.

8 repeated sequences

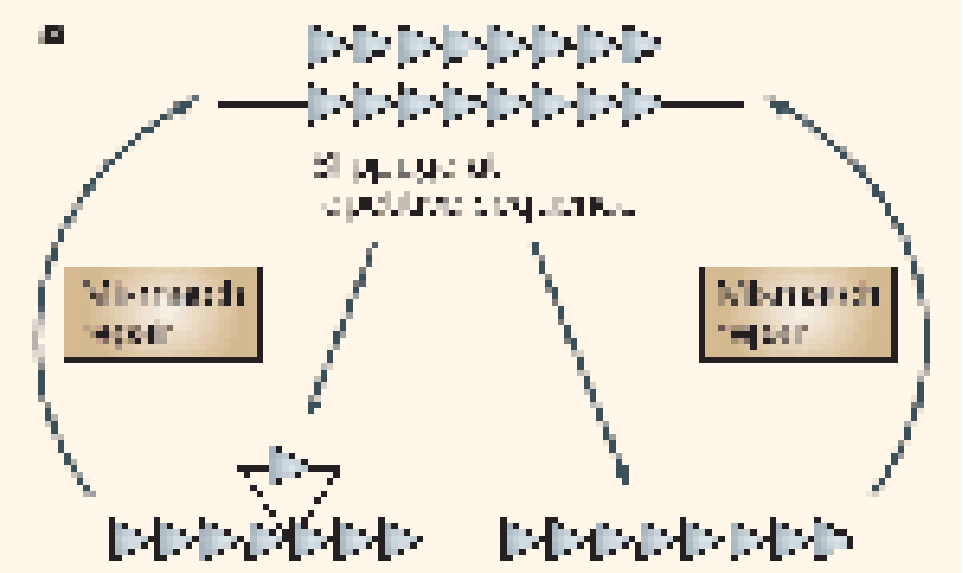

DNA

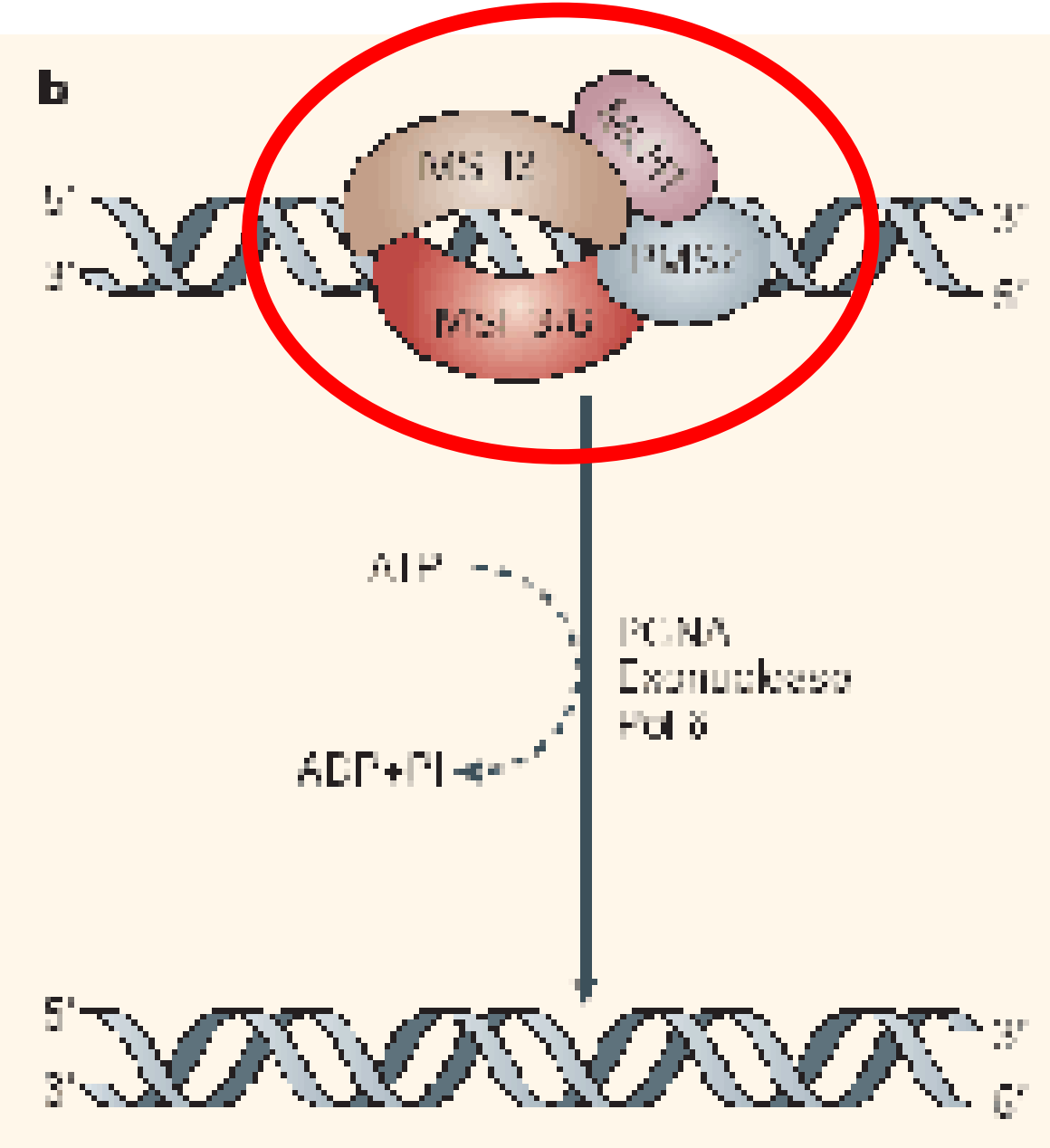

DNA Mismatch Repair Machinery:

- **MSH2**
- **MLH1**
- **PMS2**
- **MSH6**

Table 1. Cancers with an MSI-H frequency greater than 10%

Tumor type	Frequency, % (*n*)	Study
Colorectal cancer	15% (1066)	Hampel et al. (72)
Endometrial	22% (543), 33% (446)	Ziegelbo m et al. (73), Hampel et al. (74)
Gastric	22% (295)	TCGA (75)
Hepatocellular carcinoma	16% (37)[a]	Chaopin et al. (76)
Ampullary carcinoma	10% (144)	Ruemmele et al. (77)
Thyroid	63% (30)[a]	Mitmaker et al. (78)
Skin (sebaceous tumors)	35% (20)[a], 60% (25)[a]	Cesinaro et al. (79), Kruse et al (80)
Skin (melanoma)	11% (58)[a]	Palmieri et al. (81)

[a]Studies of less than 100 patients.

Table 2. Cancers with an MSI-H frequency between 2% and 10%

Tumor type	Frequency, % (*n*)	Study
Ovarian	10% (123/4)	Murphy and Wentzensen (52)
Cervical	8% (54/7)[a]	Lee (83)
Esophageal adenocarcinoma	7% (76)	Kim et al. (84)
Soft-tissue sarcoma	5% (40)	Kawaguchi et al. (85)
Head and neck SCC	3% (5/8)[b]	Claver et al. (86)
Renal cell carcinoma	3% (5/9)	Hammerschmied et al. (87)
Ewing sarcoma	2% (5/5)	Alldinger et al. (88)

Abbreviation: SCC, squamous cell carcinoma.

[a]This number represents an aggregate of studies with different definitions of MSI-H, not all of which meet the Bethesda guidelines.

[b]MSI-H was defined as positivity in at least 2/8 markers.

MMR Immunohistochemistry

- **Loss of expression of MMR proteins = reliable test of mismatch repair deficiency**

(antibodies to *hMLH1*, *hMSH2*, *hMSH6* and *hPMS2)*

- **This feature alone can not discriminate between sporadic MSI-H and Lynch syndrome due to the germ line mutation in *hMLH1* (approximately half of the cases).**
- **In the majority of sporadic MSI-H tumors there is characteristic *BRAF* (V600E) mutation not seen in Lynch syndrome.**
- **This provides for algorithmic approach to analysis of MSI-H tumors.**

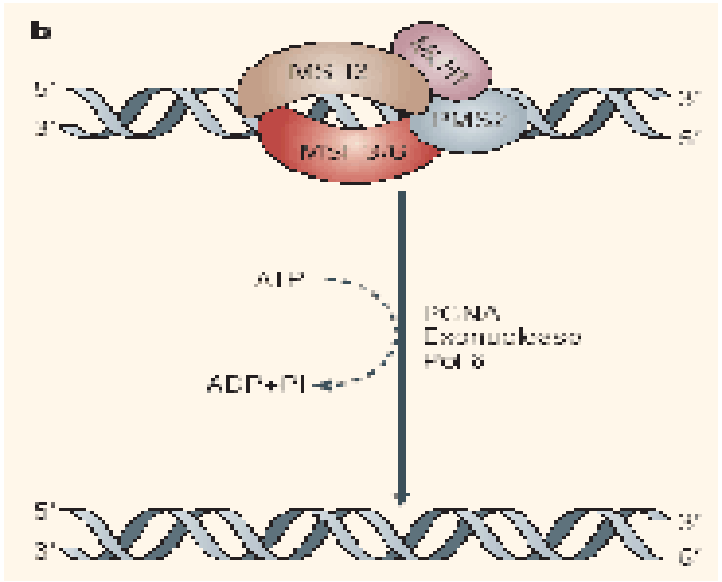

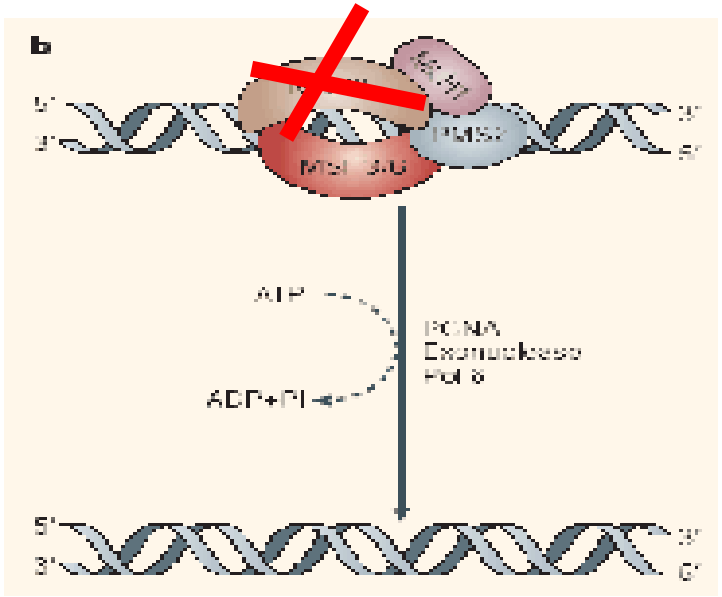

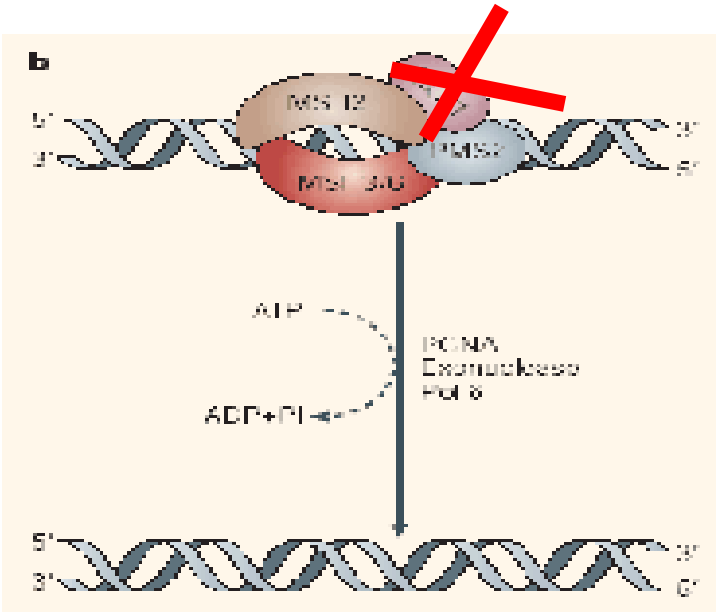

MSH2

MLH1

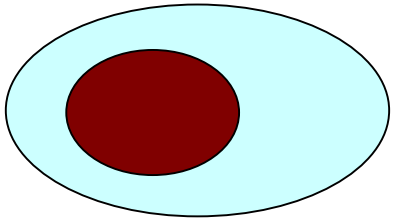

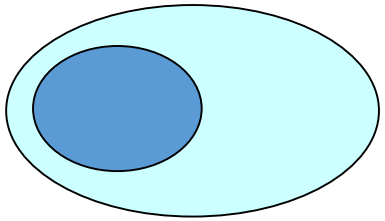

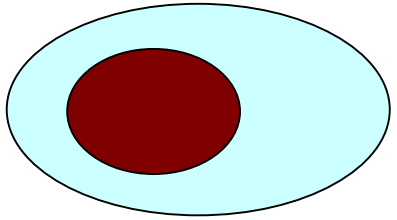

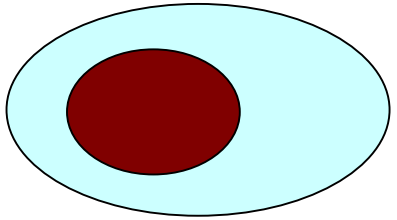

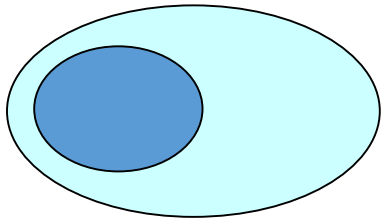

(NORMAL)

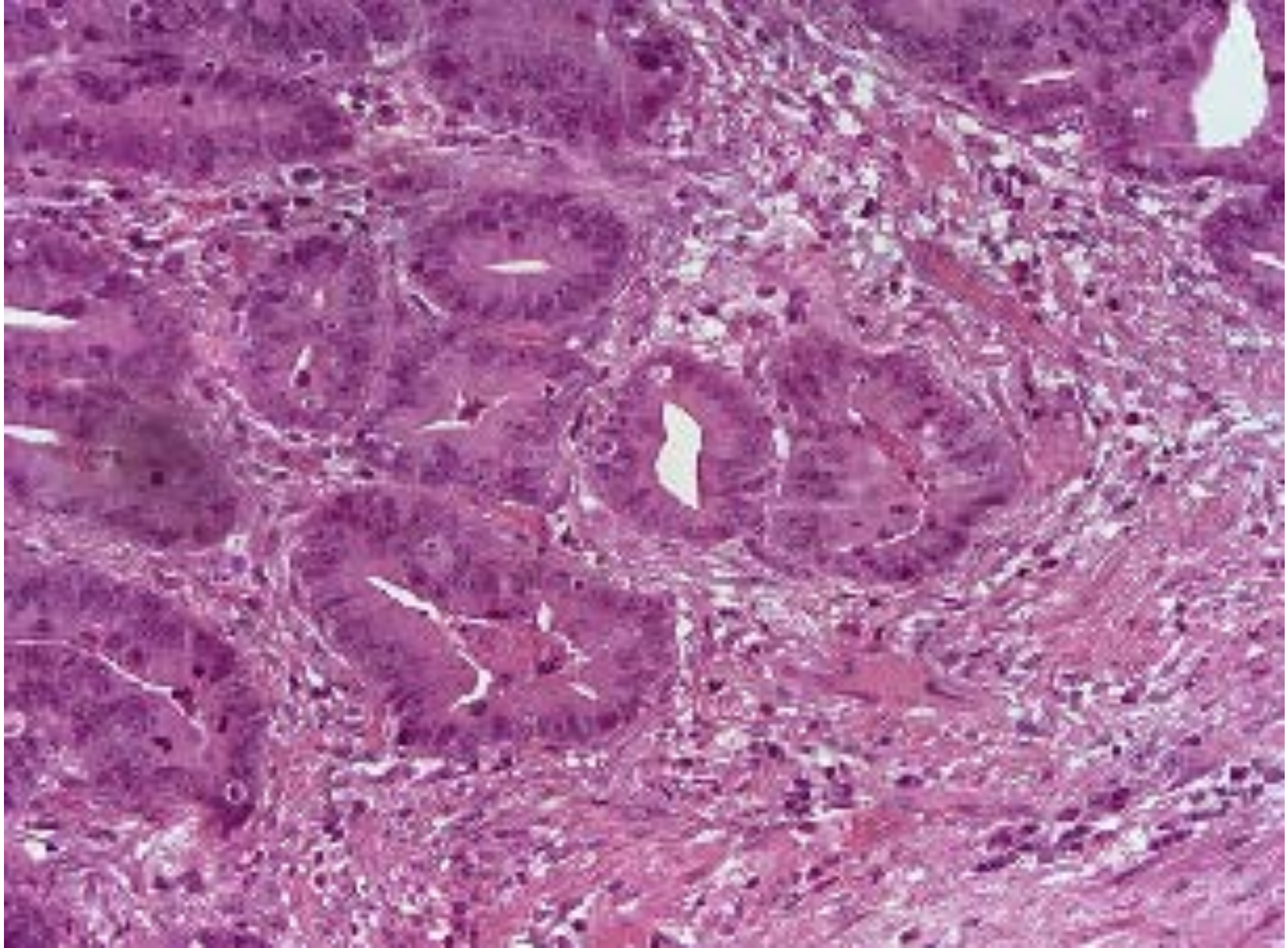

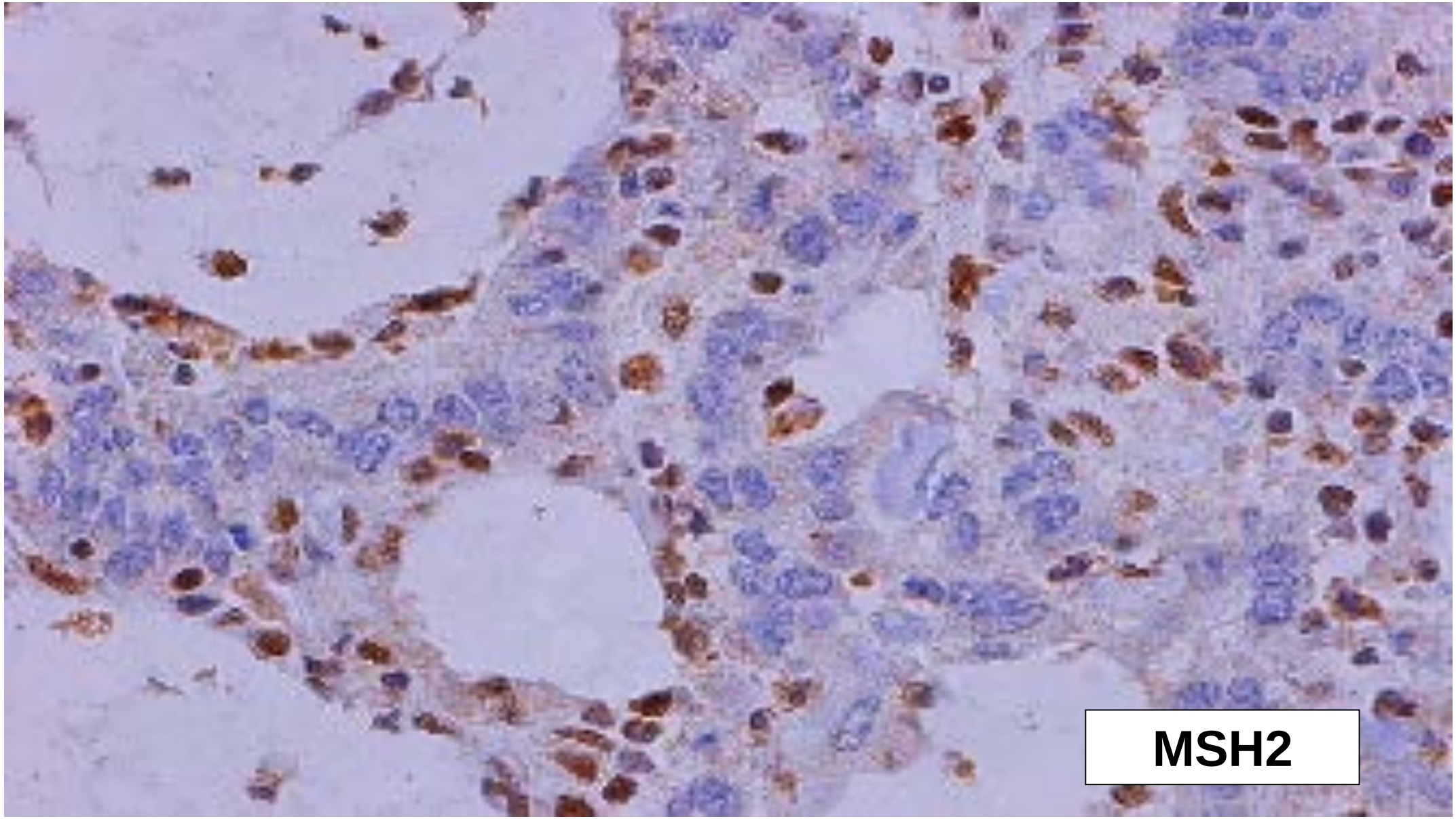
MSH2

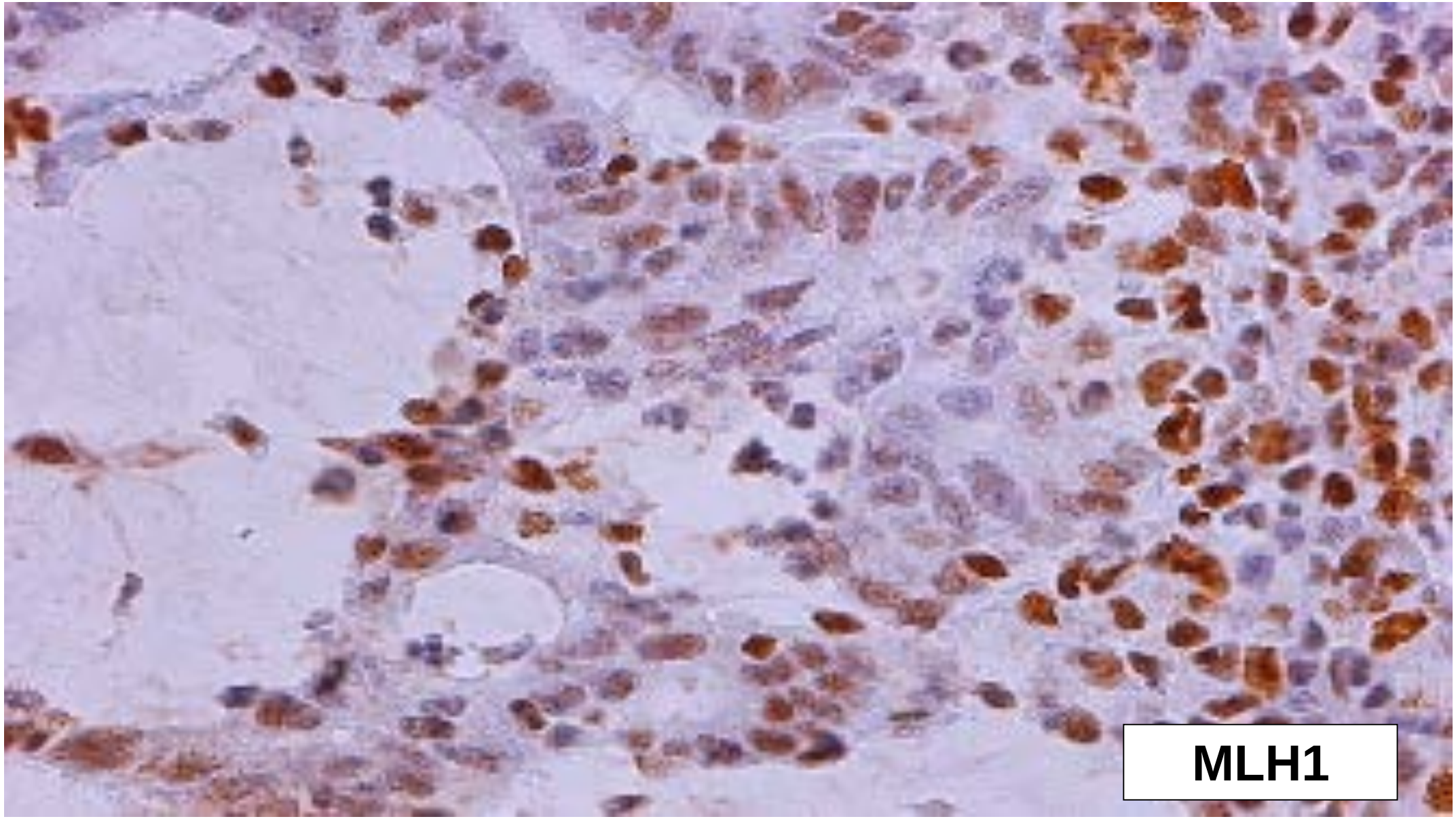
MLH1

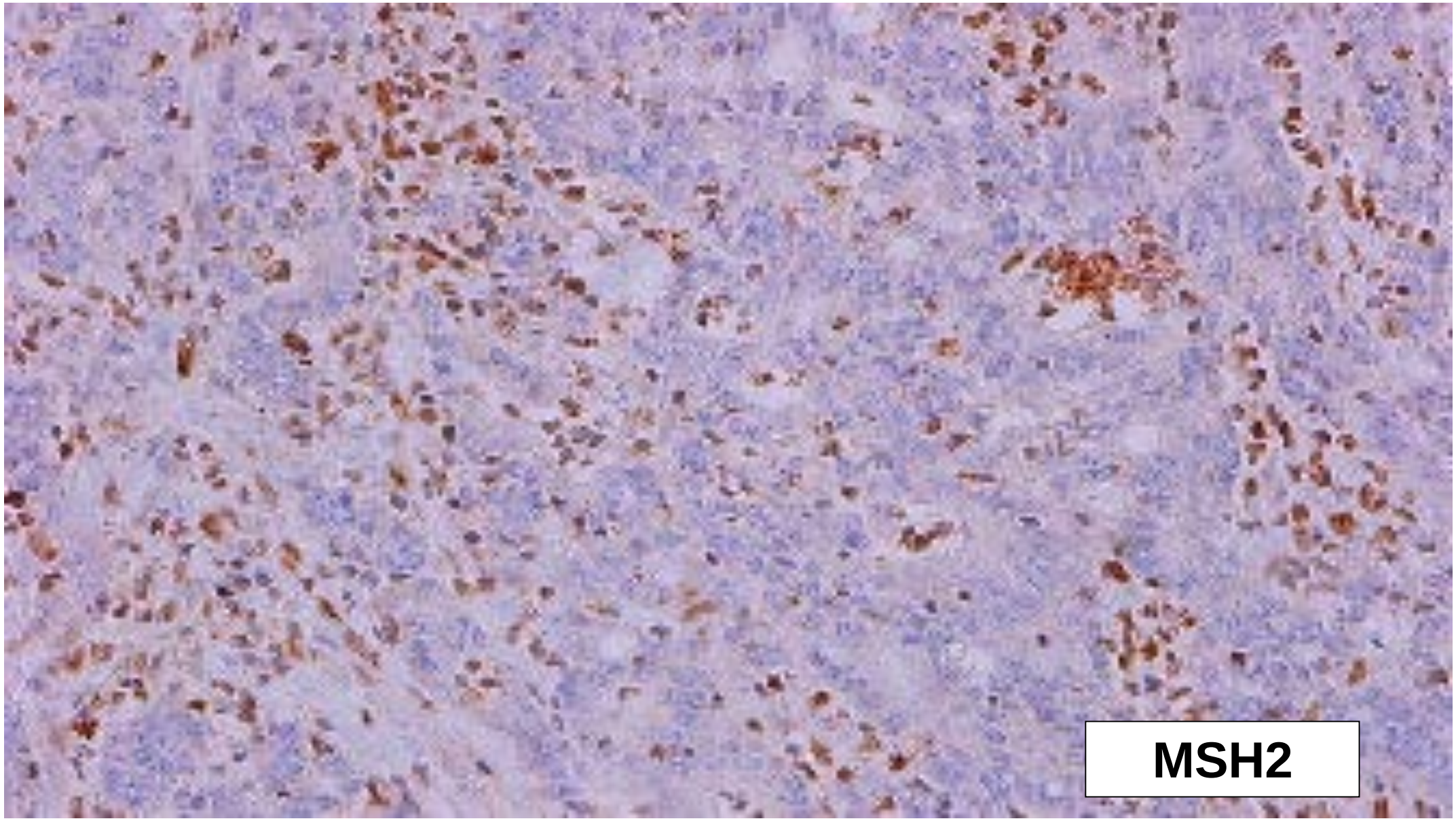
MSH2

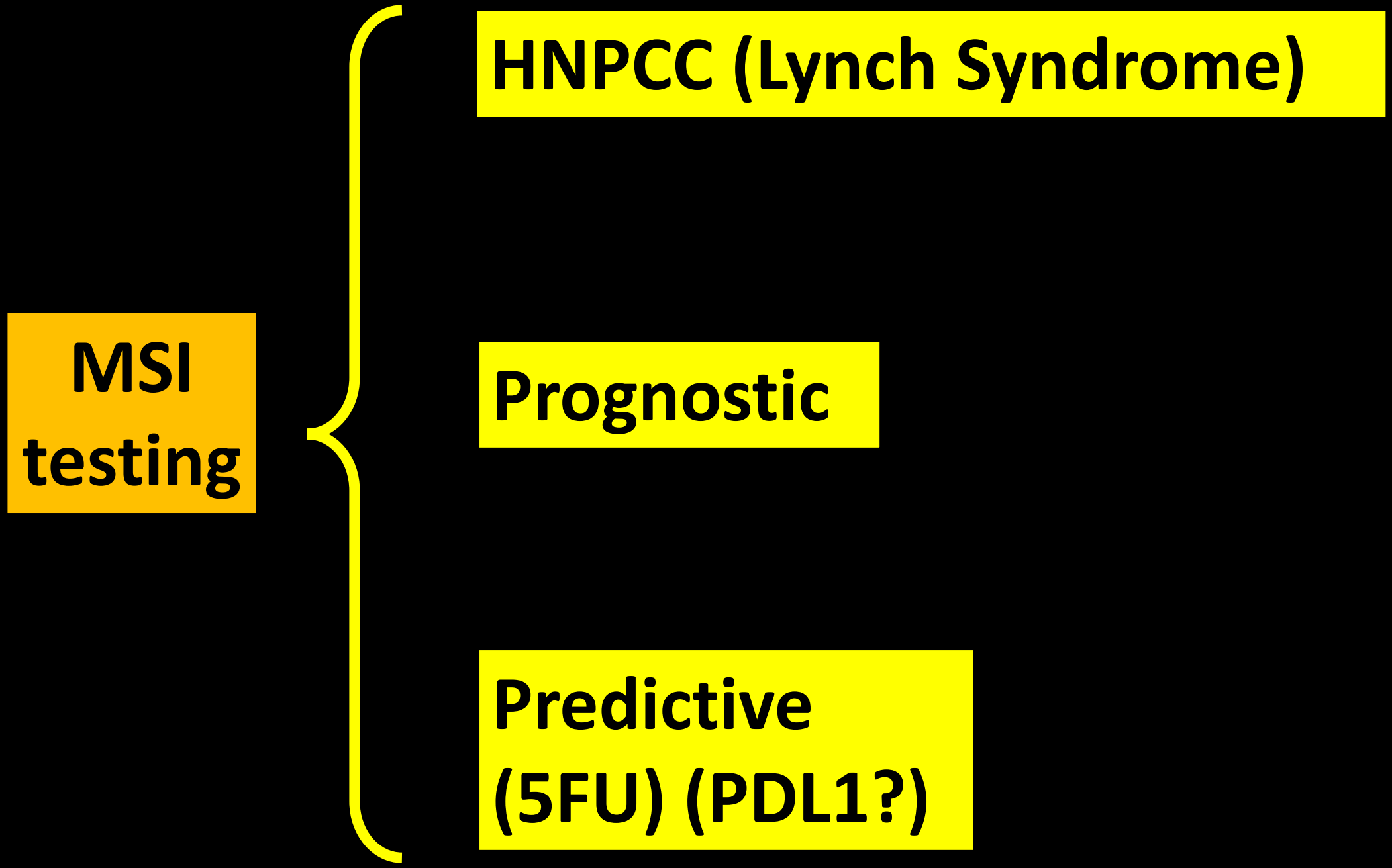
MSI testing
HNPCC (Lynch Syndrome)
Prognostic
Predictive (5FU) (PDL1?)

Hereditary colorectal cancer syndromes

Syndrome	*Preinvasive*	*CRC morphology*	*Extra colonic pathology*	*Mutation*
Lynch	Tubulo-villous adenoma, usually right-sided	Mucinous, medullary, signet ring and mixed types	Endometrial carcinoma; sebaceous skin tumors	MMR genes (*hMLH1*, *hMSH2*, *hMSH6 or hPMS2*)
FAP	Tubular adenoma, microadenomas	Adenocarcinoma NOS	Fibromatoses, hepatoblastoma	*APC*
MAP	Tubular adenoma	Adenocarcinoma NOS	Duodenal carcinoma	*MUTYH*
PJS	Hamartomatous polyp with smooth muscle core	Adenocarcinoma NOS	Esophagus, Stomach, small intestine and pancreas carcinomas; sex cord tumors	*STK11*
JP	Hamartomatous polyp with dilated crypts	Not specified	Pancreatic, gastric duodenal carcinomas	*SMAD4/BMPR1A*
Cowden	Hamartomatous polyp	No increased risk for CRC	Breast, thyroid and uterus carcinomas	*PTEN*

Circle graph depicting the marked genotypic and phenotypic heterogeneity in hereditary colorectal cancer syndromes. Note those with an increased risk for small bowel cancer (Revised with permission from Lynch et al (2004) Cancer 100:53–64.)

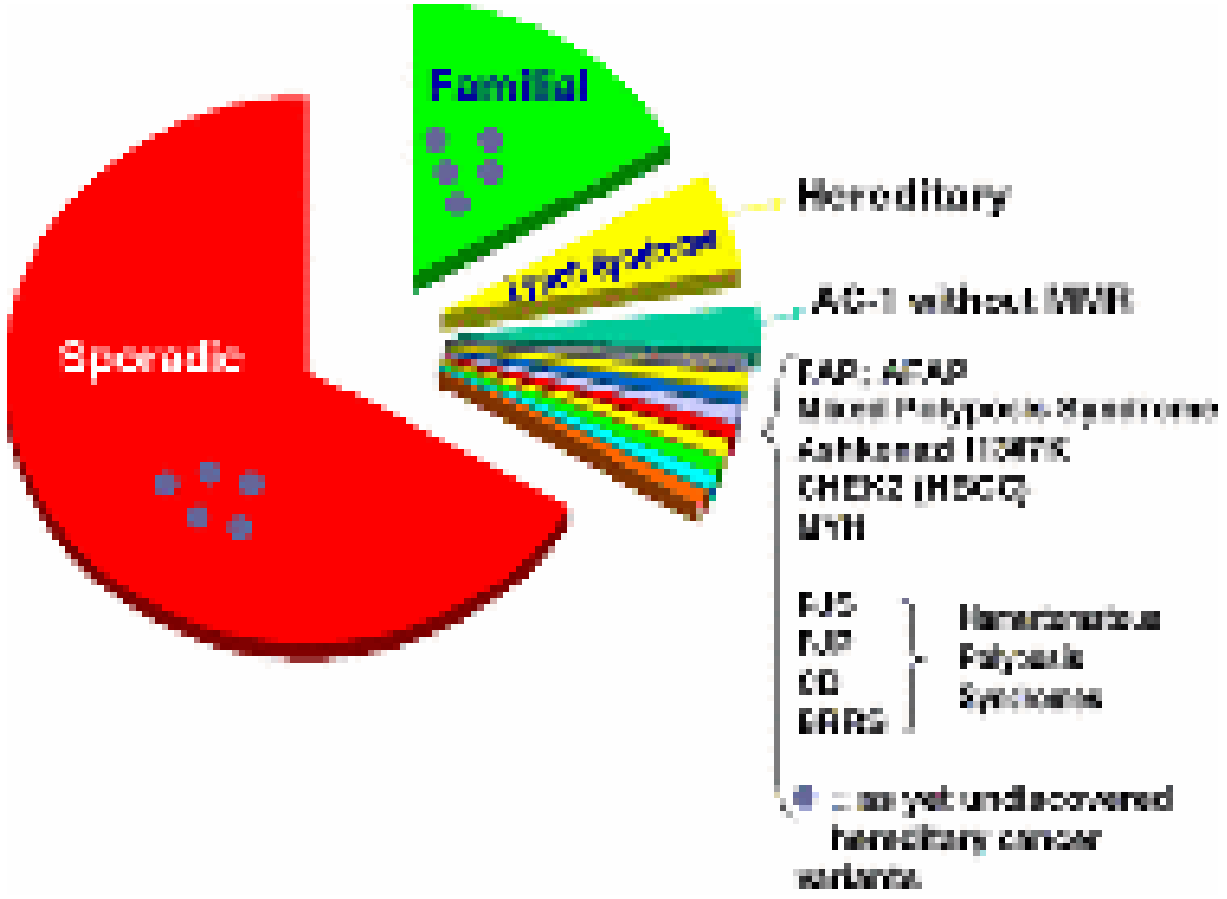

HNPCC (Lynch syndrome)
Cardinal Features

CRC in HNPCC

- **poorly differentiated,**
- **mucoid and signet-cell features,**
- **Crohn's-like reaction,**
- **excess of tumor infiltrating lymphocytes (TILs)**
- **MSI-H**

- Increased survival from CRC, when controlled for age and stage;

- Accelerated carcinogenesis and reduced interval CRC (adenoma-ca within 2–3 years, as opposed to 8–10 years in the general population)

- Sebaceous adenomas, sebaceous carcinomas, and multiple keratoacanthomas in the Muir–Torre syndrome variant of Lynch syndrome;

- The *sine qua non*, the identification of a germline MMR mutation segregating with syndrome-affected individuals in the family.

MSI testing

HNPCC

P

Since **MSI-H** cancers have a favorable prognosis, MSI testing for stage II cases can help in making decisions regarding adjuvant chemotherapy.
(J Clin Oncol. 2010;28(20):3219-3226.)

P
(5

Since **MSI-H** cancers do not respond well to 5-FU therapy, MSI status is also important in determining the choice of chemotherapeutic regimen.
(J Clin Oncol. 2010;28(20):3219-3226.)

KRAS

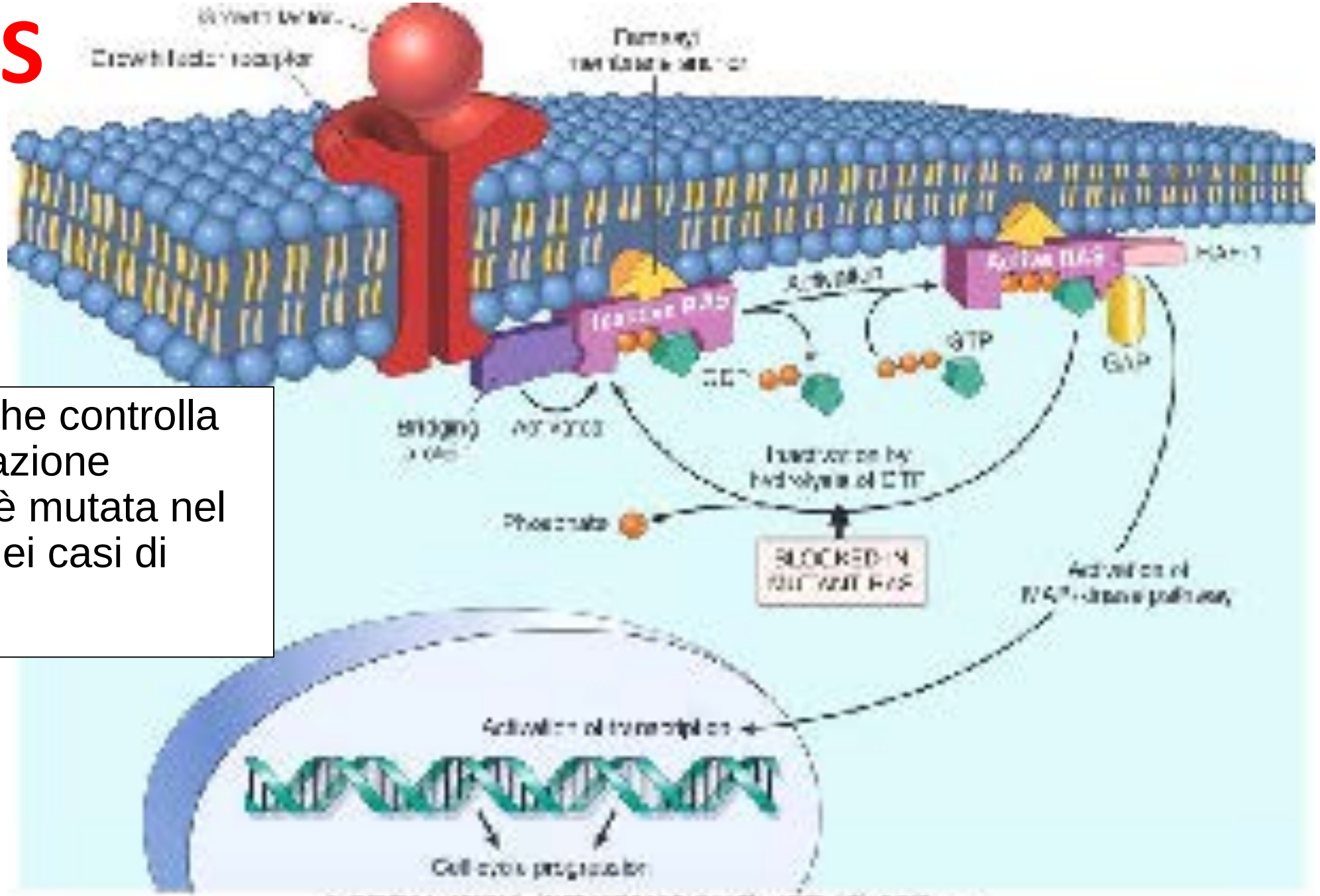

GTP-asi che controlla la proliferazione cellulare, è mutata nel 50–60% dei casi di CRC.

KRAS pathway

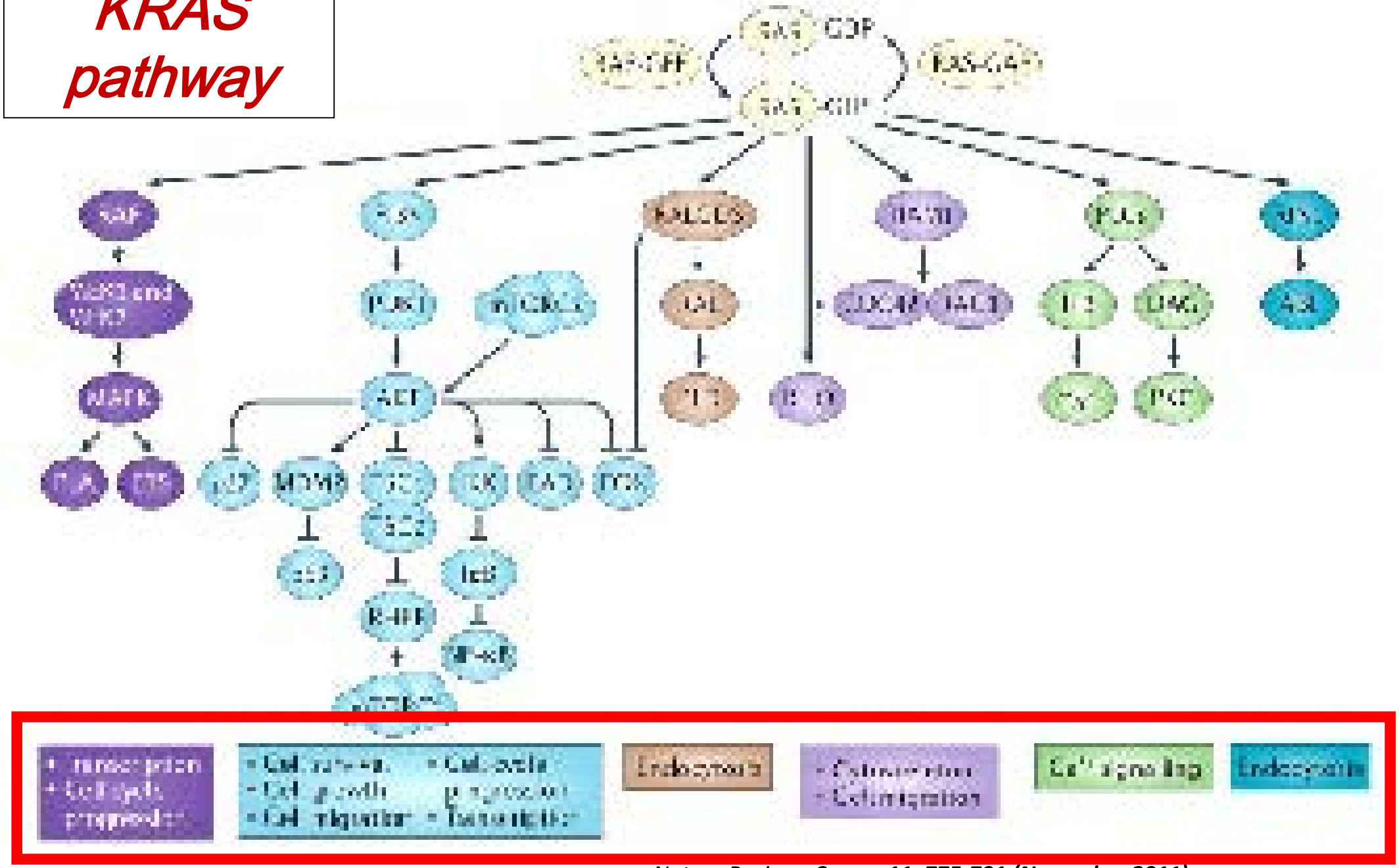

Nature Reviews Cancer ***11, 775-791 (November 2011)***

Synergistic effect between erlotinib and MEK inhibitors in KRAS wild-type human cancer cells

Clin Cancer Res. 2011 May 1; 17(9): 2744–2756

Combination treatments of erlotinib and MEK inibitors (RDEA119-erlotinib or AZD6244-erlotinib) shows significant synergistic effect in wild-type but not in mutant KRAS tumours (cell culture study).

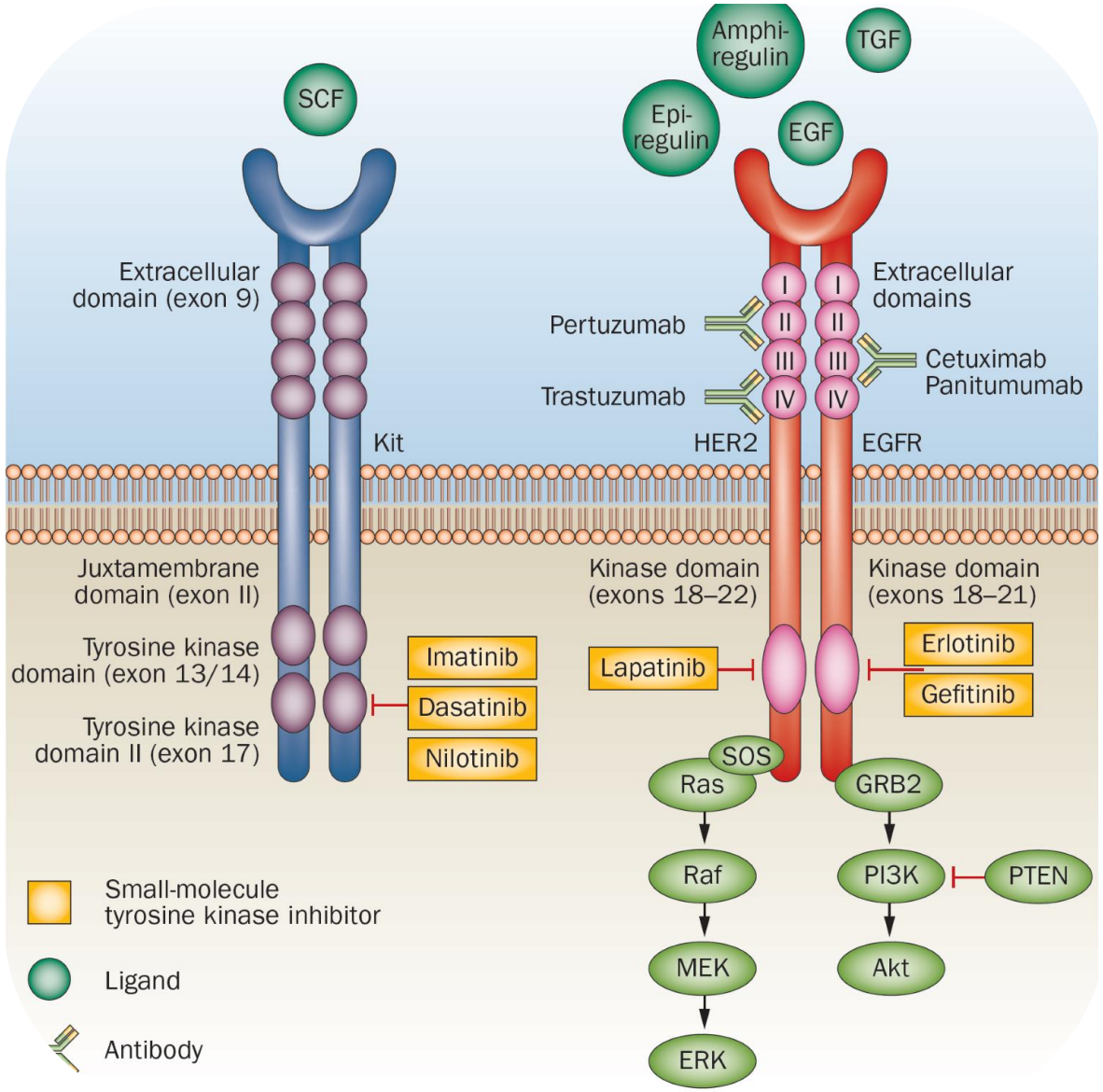

Adenocarcinoma scarsamente differenziato del grosso intestino (rif. a) infiltrante il connettivo periviscerale.
Margini di resezione su pezzo chirurgico e margine radiale indenni da neoplasia.
Metastasi in 4 su 32 linfonodi periviscerali.
Si valutano i seguenti caratteri istoprognostici.
- Modalità di crescita: espansiva (rif. b).
- Infiltrato linfoide peritumorale: moderato (rif. c).
- Reazione desmoplastica stromale: moderata (rif. c).
- Reazione Crohn's-like: presente (rif. d).
- Budding peritumorale: alto grado (13 foci/250x) (rif. e).
- Angioinvasione: presente (rif. f).
- Linfoinvasione: assente (rif. f).
- Neuroinvasione: assente (rif. f).
- Distanza minima dal margine di scollamento circonferenziale (margine radiale) (rif. g): 12 mm.
- Profondità di infiltrazione del connettivo periviscerale: 7 mm (rif. h).

Valutazione dell'espressione immunoistochimica delle proteine del sistema enzimatico MMR ("DNA Mismatch Repair", deputato alla correzione di appaiamenti scorretti delle basi nel DNA) su tessuto neoplastico.
- MSH2 (clone G219-1129): cellule carcinomatose con immunoreattività preservata;
- MLH1 (clone M1): cellule carcinomatose con immunoreattività non preservata;
- MSH6 (clone 44): cellule carcinomatose con immunoreattività preservata;
- PMS2 (clone EPR3947): cellule carcinomatose con immunoreattività non preservata.
Si osserva espressione di PD-L1 nel 20% della componente neoplastica.
(Valutazione dell'espressione di PD-L1 con anticorpo clone 22C3 su sezione istologica in paraffina; piattaforma Ventana):

Stadio TNM (rif. i): pT3(V1), pN2a, G3.

Riferimenti metodologici:
(a) WHO Classification of Tumours. IARC 2010.
(b) Valutazione espressa come: espansiva, infiltrativa (Jass, 1987).
(c) Valutazione espressa come: assente, lieve, moderata, marcata (modificato da Jass, 1987).
(d) Valutazione espressa come: assente, presente (Graham, 1990).
(e) Score di riferimento: 0-9 foci/250x = basso grado; >=10 foci/250x = alto grado (Ueno, 2004).
(f) Valutazione espressa come: osservata; non osservata.
(g) Distanza misurata microscopicamente ed espressa in millimetri (Nagtegaal, Am J Surg Pathol, 2002).
(h) Profondità misurata in mm (UICC, TNM Supplement, 4th edition, pag. 194).
(i) UICC: TNM 8th Edition - 2017.

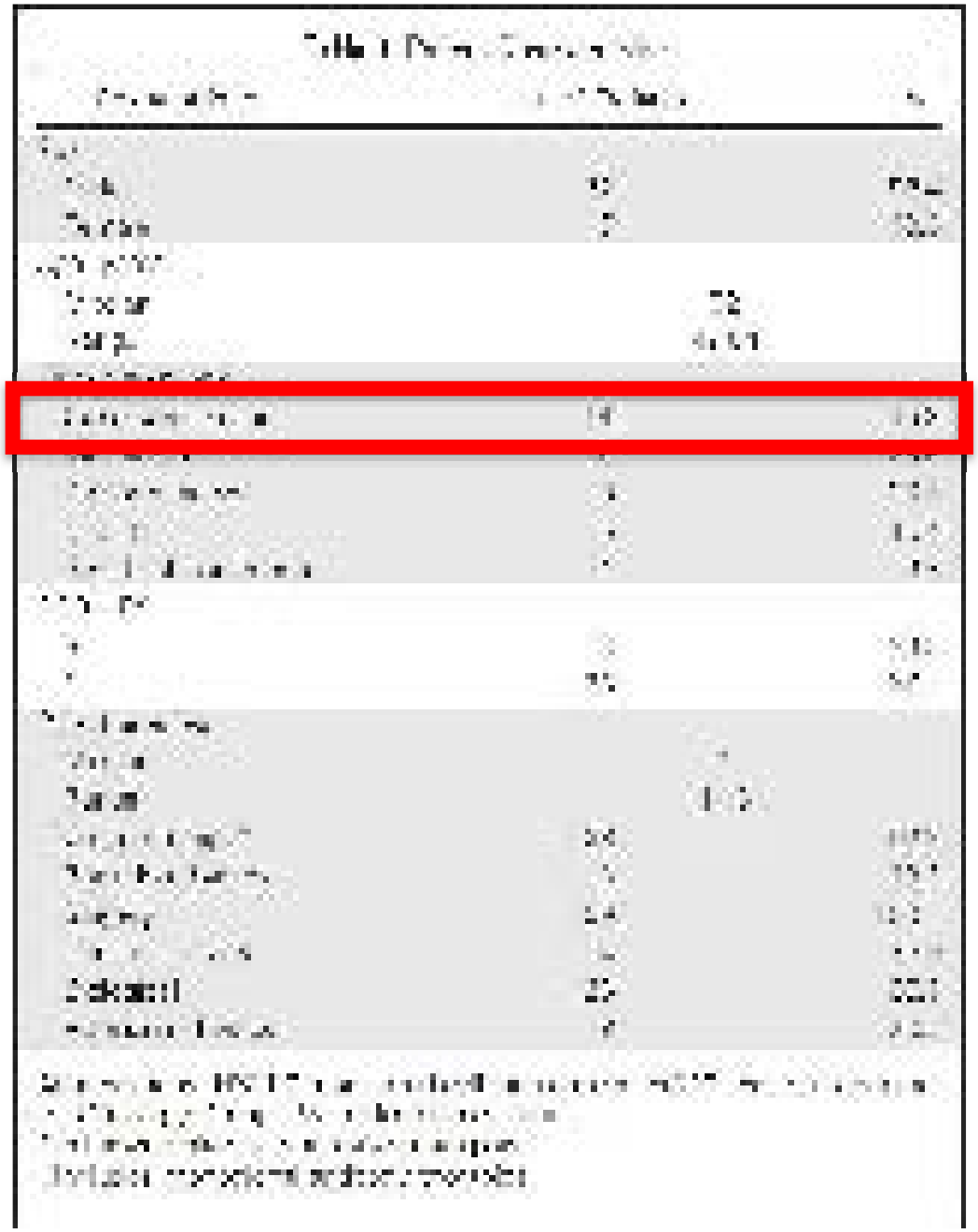

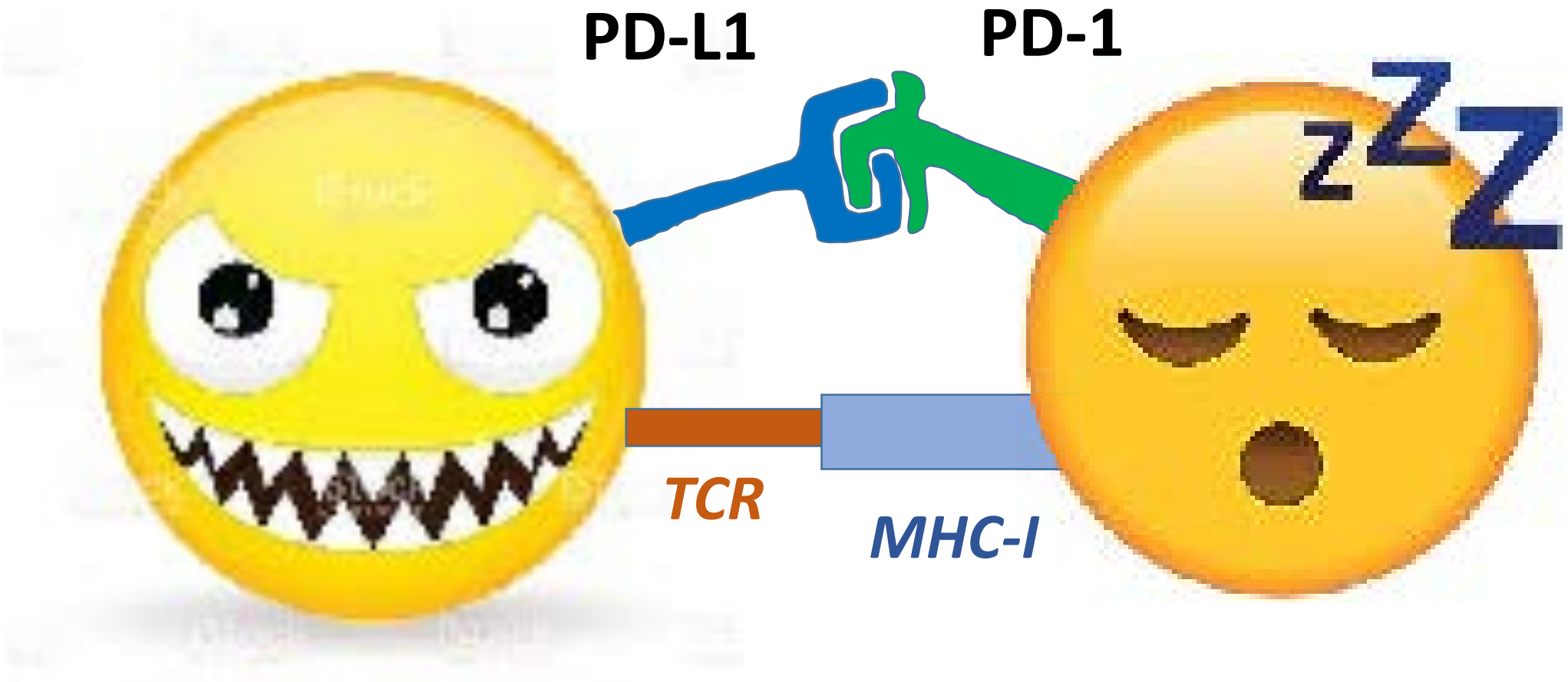

TUMOUR cell

T-lymphocyte

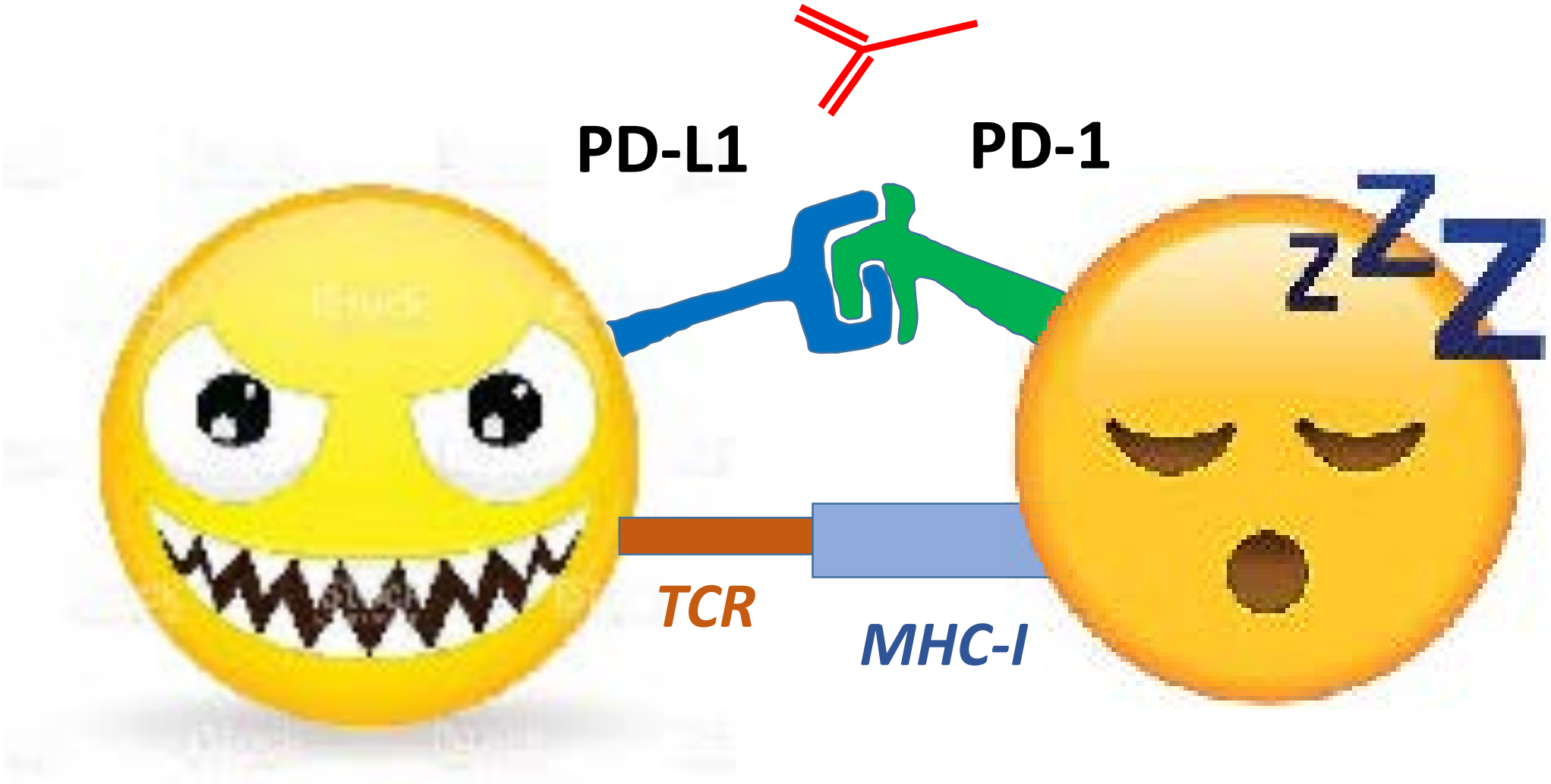
PD-L1
PD-1
TCR
MHC-I
TUMOUR cell
T-lymphocyte

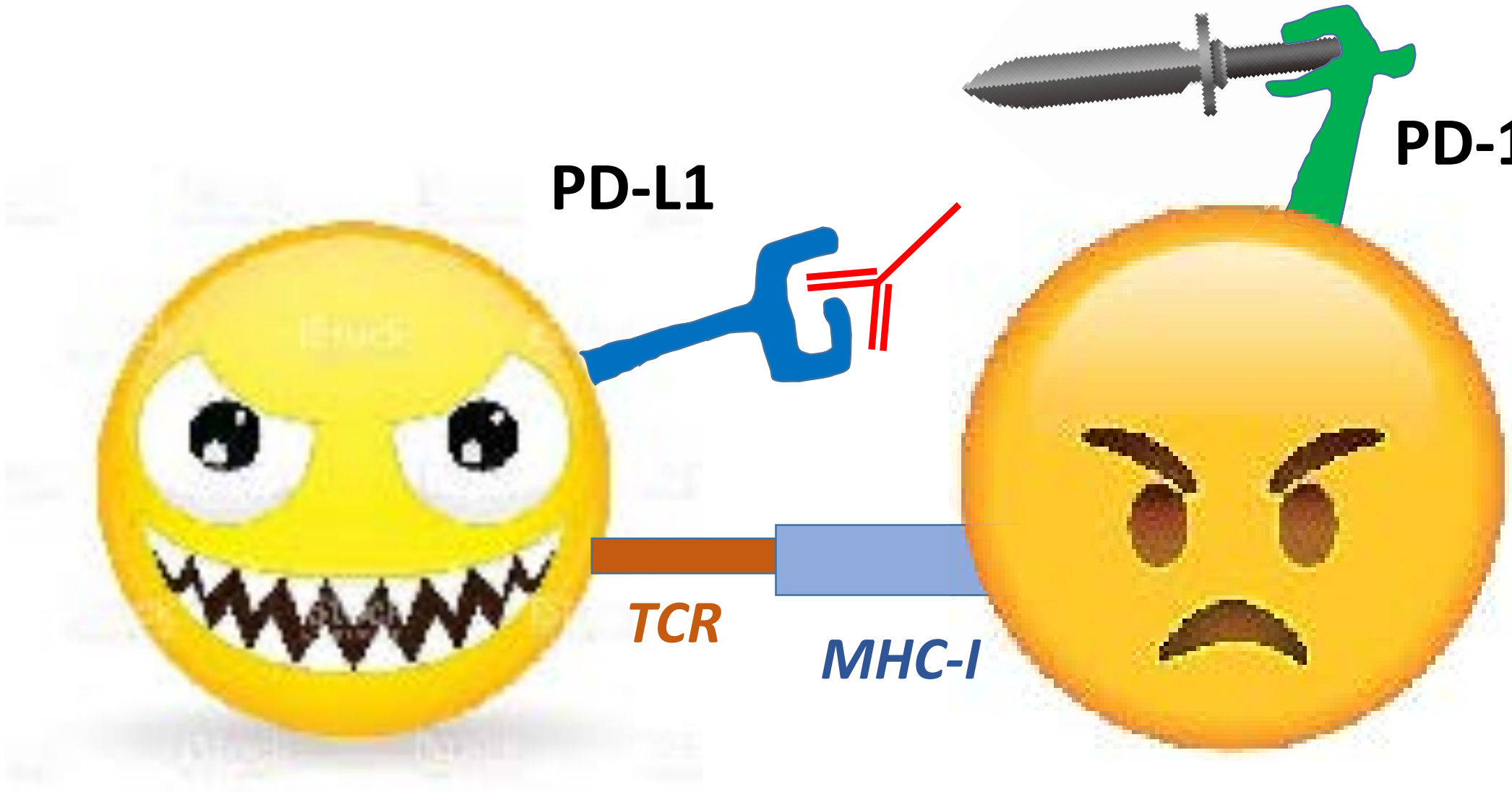

TUMOUR cell

T-lymphocyte

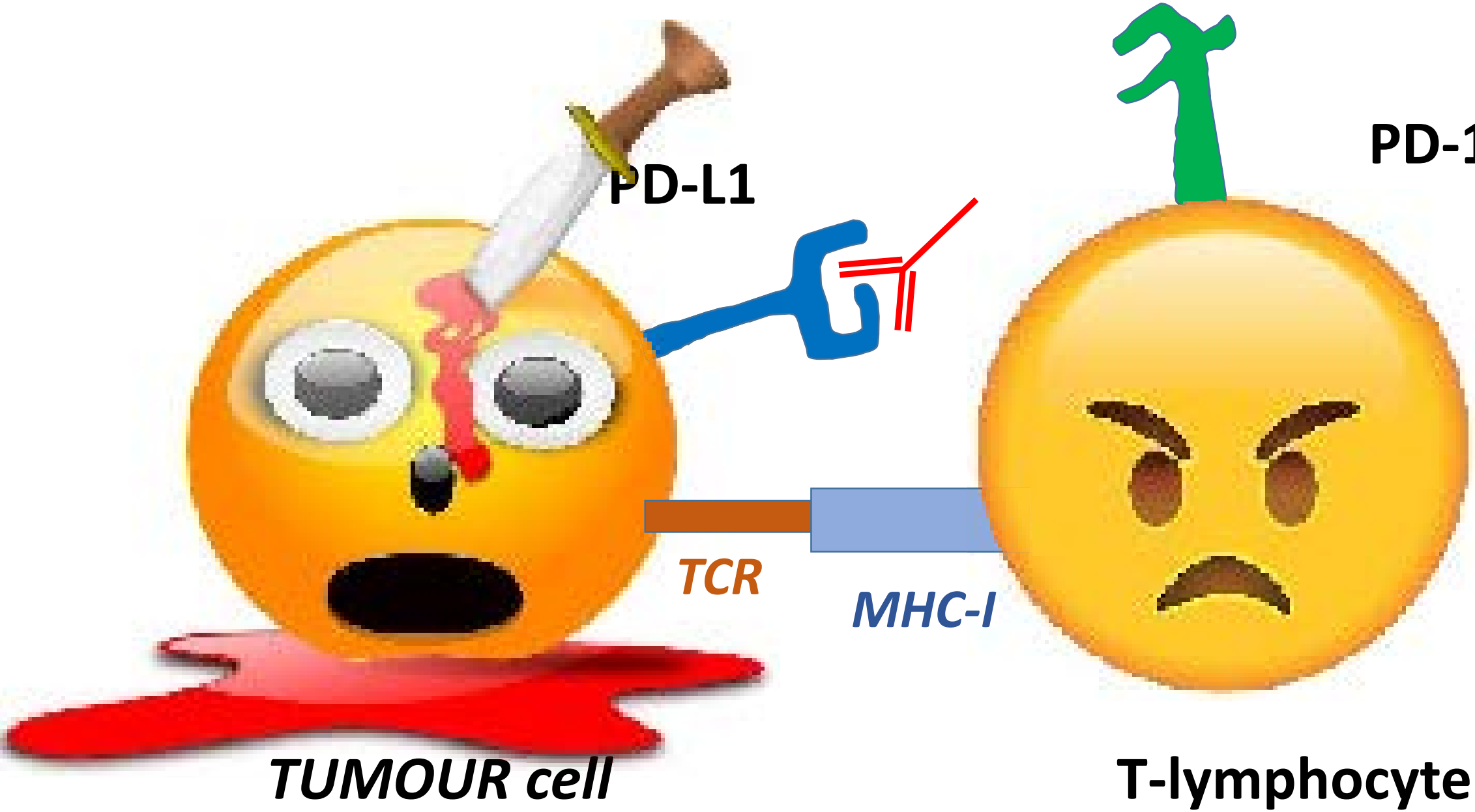
PD-L1
PD-1
TCR
MHC-I
TUMOUR cell
T-lymphocyte

2A. T CELL INTERACTION with CANCER CELL

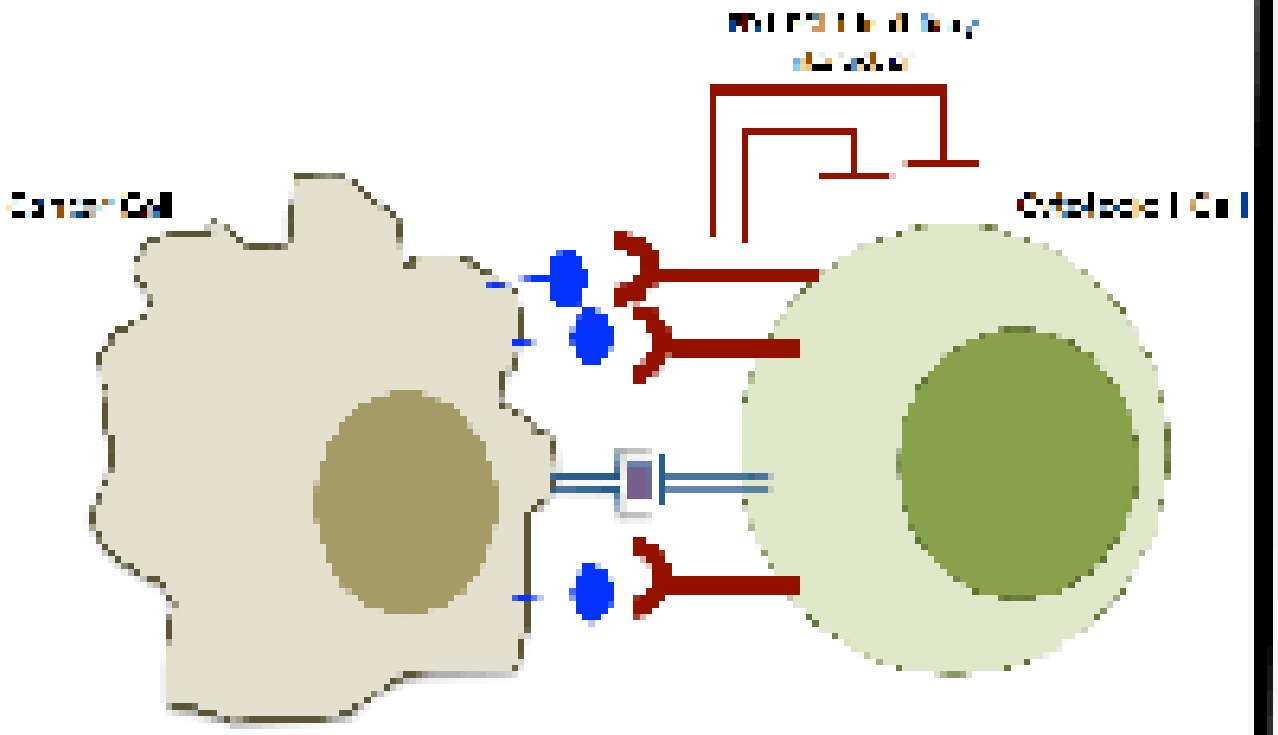

2B. ACTION of ANTI-PD-1 DRUG

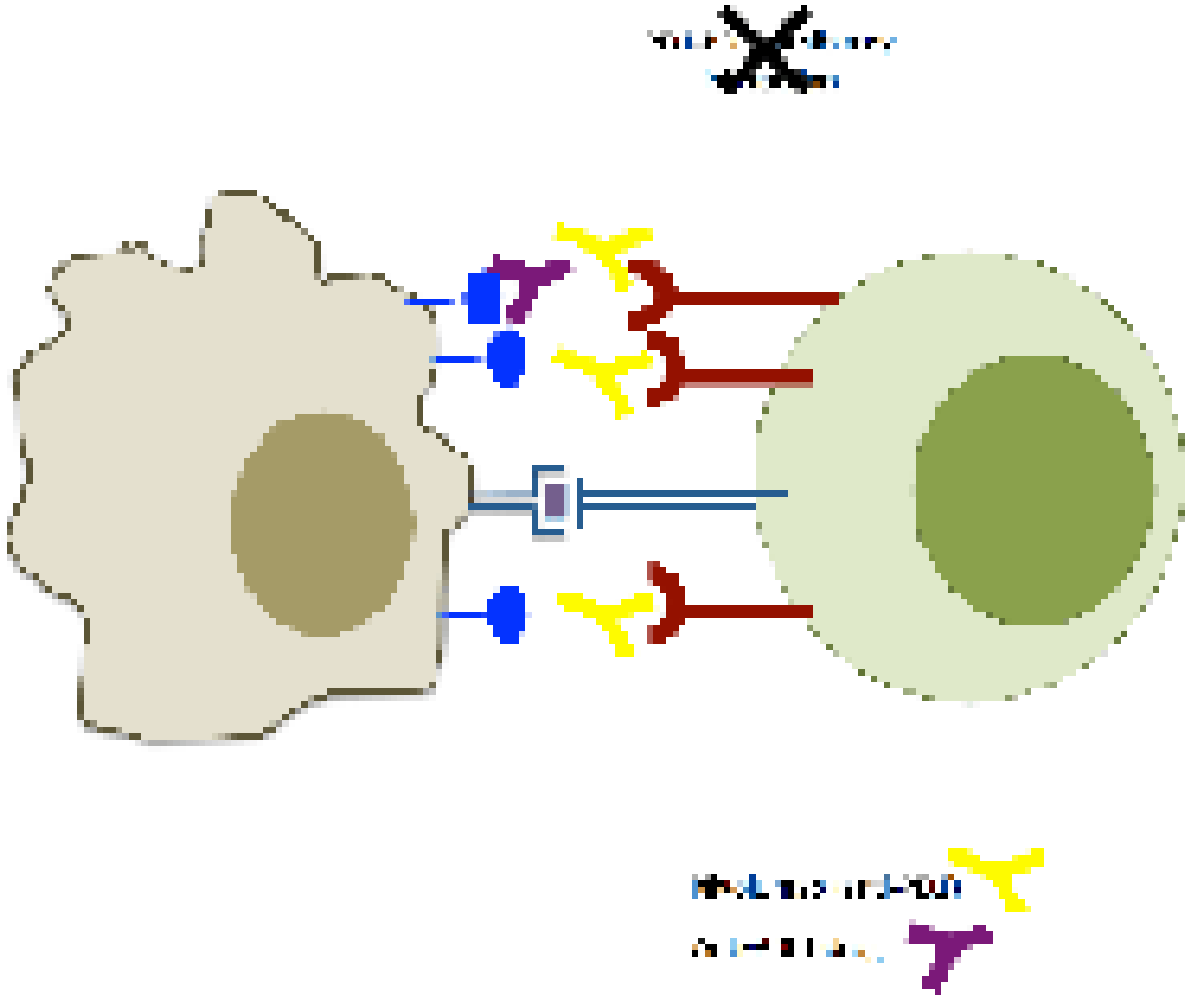

PD-L1 Assay Systems Used in the Blueprint Project

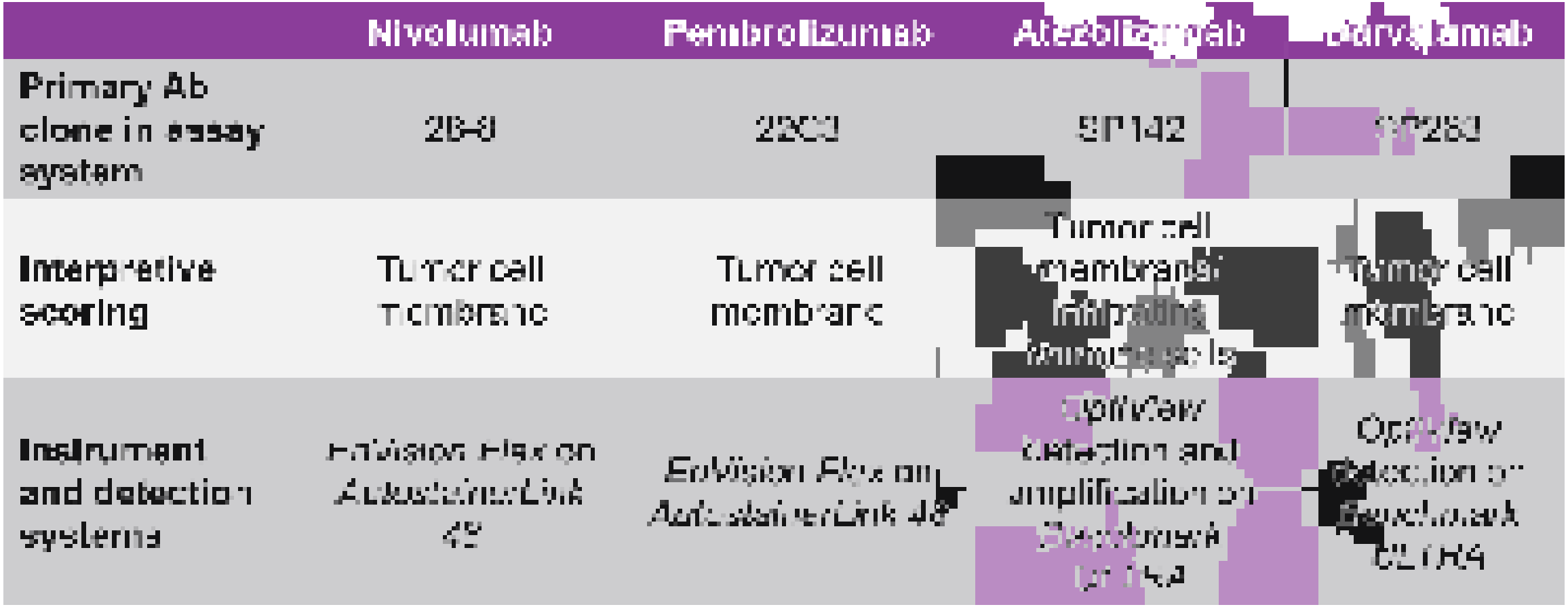

Hirsch FR, et al. J Thorac Oncol. 2017;12:208-222. Blueprint Working Group. Blueprint proposal. 2015.

Table 1 Biomarker assays for anti-PD-1/PD-L1 drugs and associated outcomes

Example	Drug	Primary Target	Cut-off[a]	ORR[b]	CR	PFS[c]	OS[d]
Exploratory analysis[e][f][g]	Nivolumab	PD-1[h]	1%	26%	4%	3.5	9.2
Exploratory analysis[e][f][g]	Durvalumab (MEDI4736)	PD-L1	25%	43.6%	2.9%	12.3	49.9
Exploratory analysis[e][f][g]	Durvalumab	PD-L1 (SP263)	25%	16%	0%	1.9	10.6
Exploratory analysis[e][f][g]	Pembrolizumab	Activated NFAT	20%	18%	4%	7.2	21.8
Exploratory analysis[e][f][g]	Pembrolizumab	Interferon Gamma	1%	37%	3%	3.7	11.1
Dose 1[e][f]	Atezolizumab	PD-L1	1%	15%	1%	2.7	13.8
Dose 2[e][f]	Atezolizumab	PD-L1	5%	23%	4%	2.8	15.7
Dose 3[e][f]	Atezolizumab	Macrophage	10%	26%	10%	3.0	15.7
Dose 4[e][f]	Nivolumab	PD-L1 (Dako 28-8)	1%	19%	0%	3.5	10.6
Dose 5[e][f]	Nivolumab	PD-L1 (SP142)	5%	15%	3%	2.7	9.7
Dose 6[e][f]	Nivolumab	Macrophage	5%	24%	4%	3.5	19.9
Dose 7[e][f]	Nivolumab + Ipilimumab	Macrophage	1%	27%	5%	5.5	17.5

[a]PD-L1 cut-off for tumor cell staining. [b]Cut-off for proportion of tumor cells expressing PD-L1 below which tumor is considered PD-L1 negative. [c]PFS: Objective response rate (complete response + partial response). [d]Time to progression. [e]Time to death. [f]Efficacy of immunotherapy in relation to expression of PD-L1 by tumor cells. [g]Predictive biomarker analysis based on published results. [h]Specificity of immunotherapy for predicting response to PD-1 blockade based on measurement of PD-L1 and PD-1 based on weighted average of corresponding PD-L1 scores

Reproducibility of PD-L1 IHC Platforms

- Prospective multicenter comparison by 13 pathologists using 4 IHC assays to score PD-L1 expression on archival NSCLC samples (N = 90)

Primary Ab Clone	Mean PD-L1 Score	
	Tumor Cells	Immune Cells
22C3	2.36	2.15
28-8	3.26	2.23
SP142	1.99	1.62
E1L3N	3.20	2.23
Overall mean	**2.85**	**2.08**

Rimm DL, et al. JAMA Oncol. 2017;[Epub ahead of print].

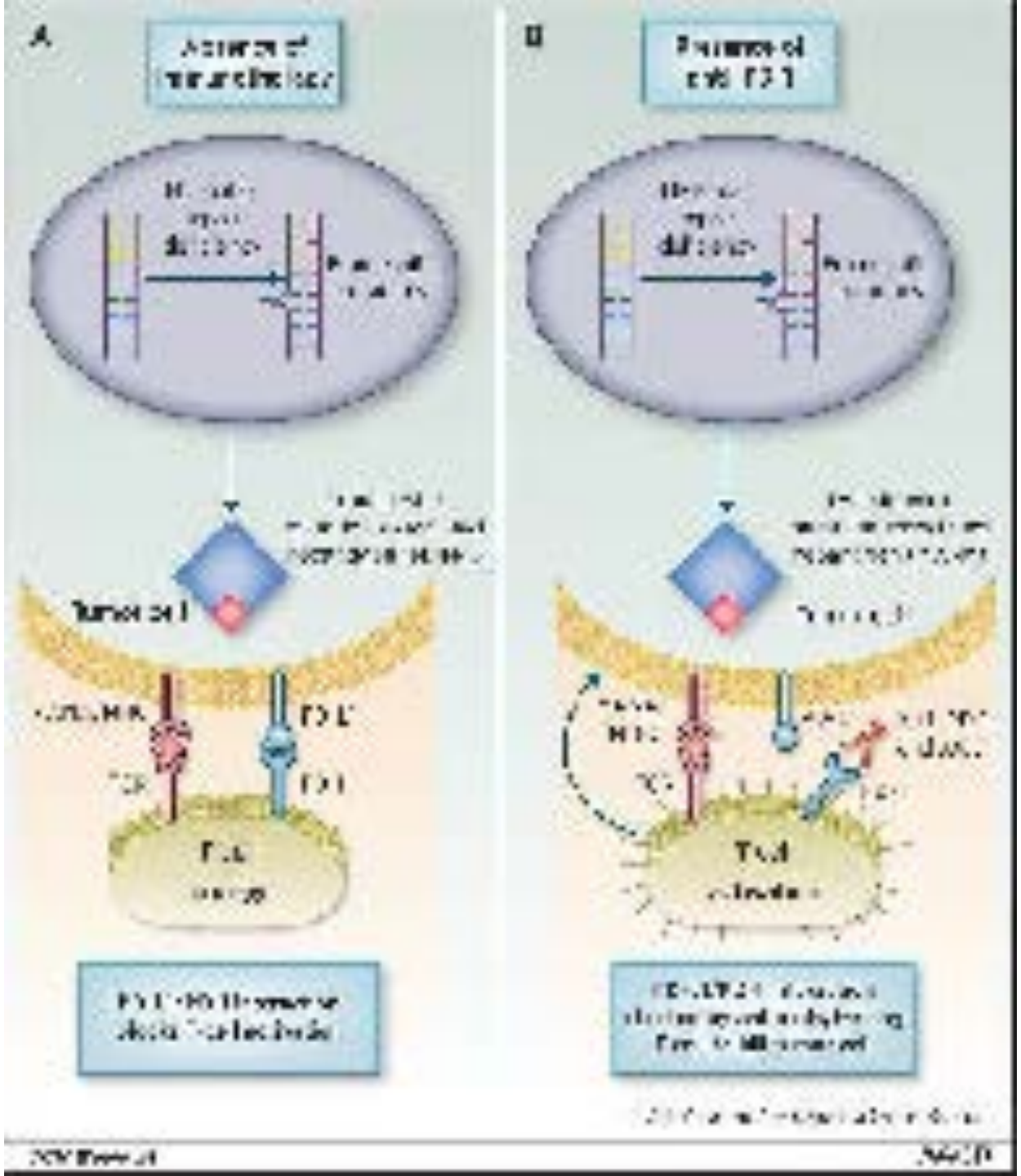

Clin Cancer Res; 22(4); 813–20. 2016

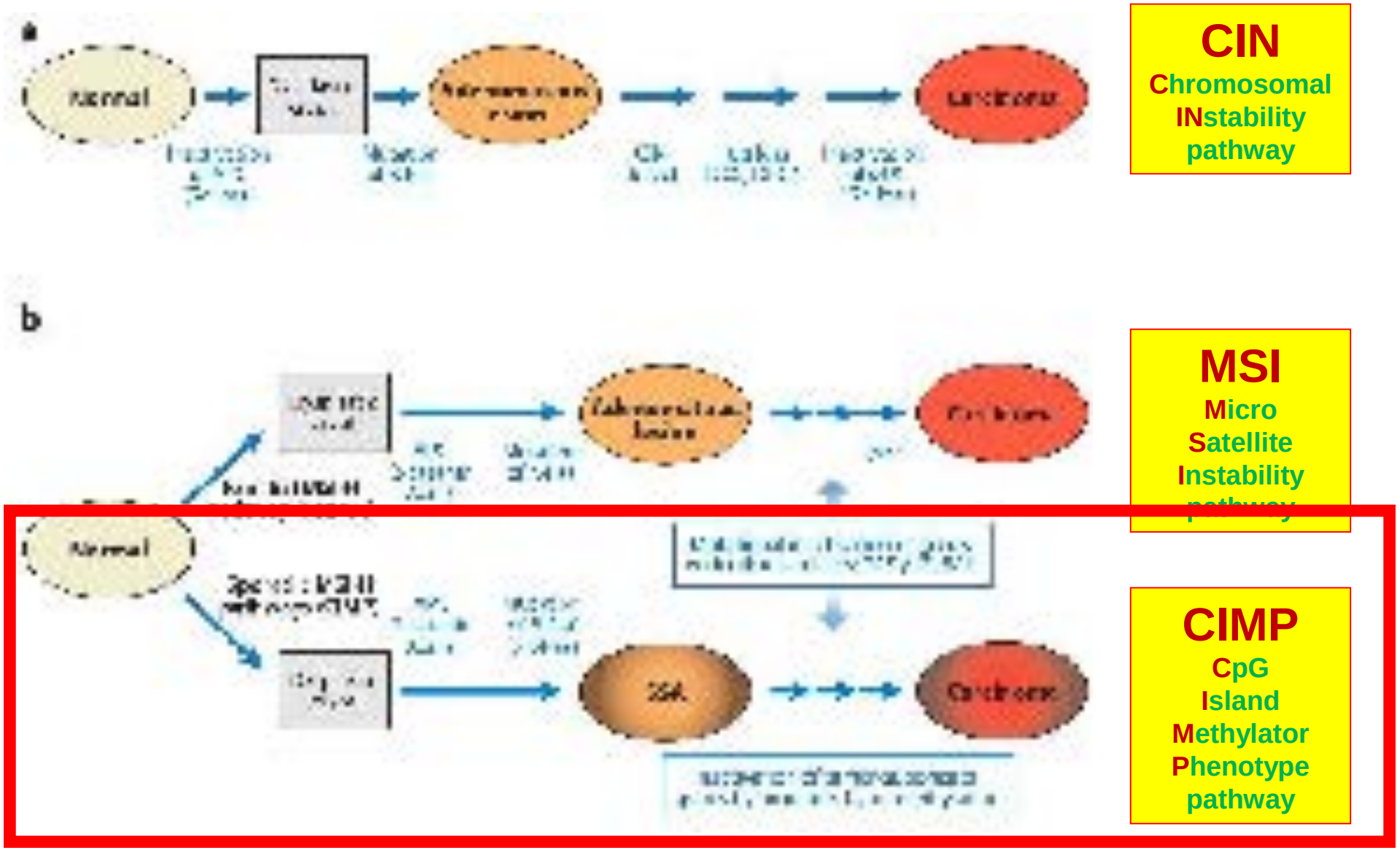

CIN
Chromosomal
INstability
pathway

MSI
Micro
Satellite
Instability
pathway

CIMP
CpG
Island
Methylator
Phenotype
pathway

ANNU REV PATHOL MECH DIS 2011 6 479,

CpG islands

- «***CpG*** sites» are regions of DNA where a cytosine nucleotide occurs next to a guanine nucleotide in the linear sequence of bases along its length.
- “CpG” is shorthand for “-C-phosphate-G-”, that is C and G separated by only one phosphate; phosphate links any two nucleosides together in DNA.
- GpG islands are genomic regions containing high conc. of GpG sites.
- In mammalian genomes CpG islands are 300-3000 bp in length, and are found in or near approx 40% of promoters of mammalian genes.
- About 70% of human promoters have a high CpG content.

Trends in Genetics 2014, 30: 75–84

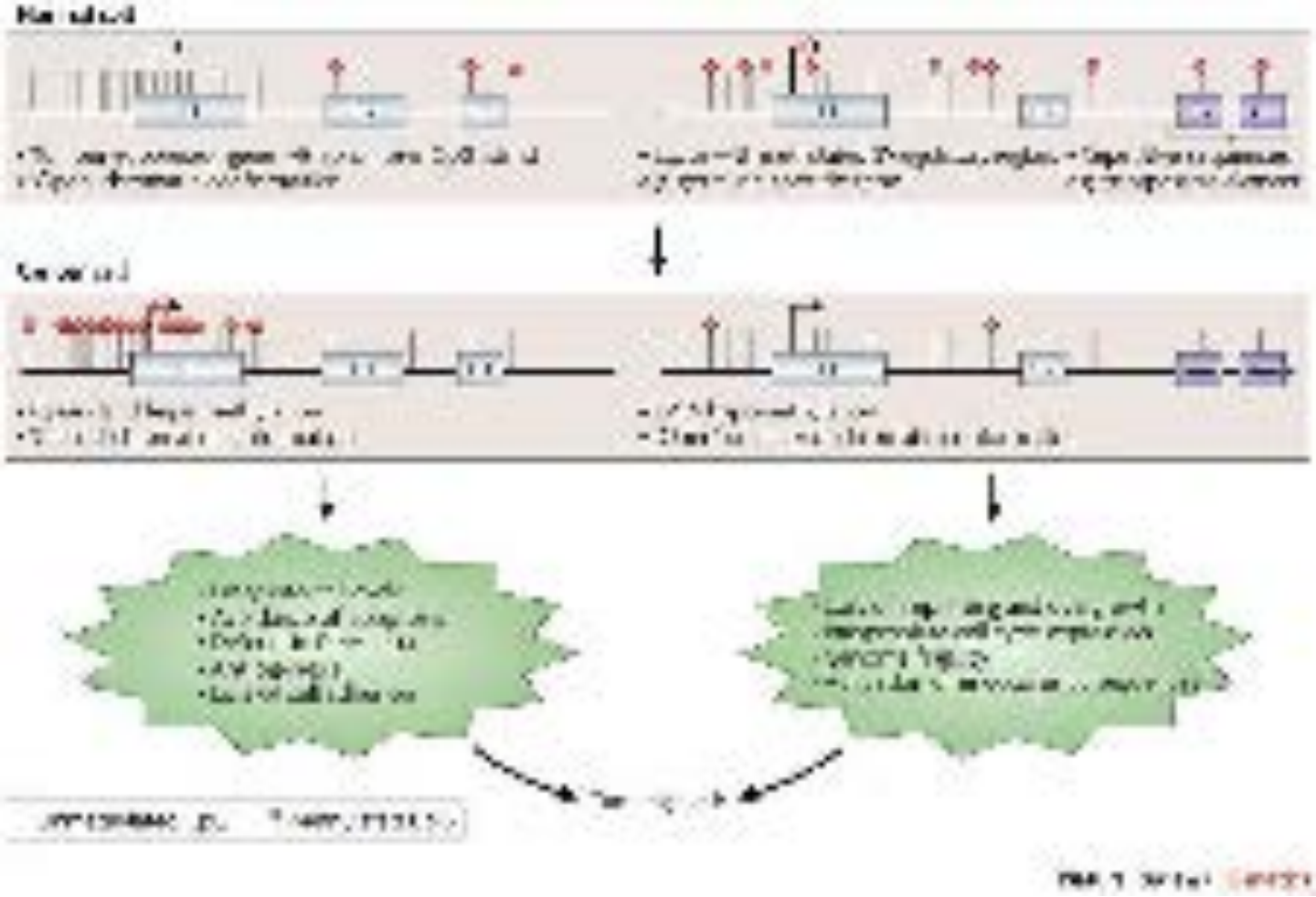

Nature Reviews Genetics **8**, 286-298 (April 2007)

"Molecular-pathological" classification of colorectal carcinoma (2009)

	Chromosomal instability pathway	Mismatch repair pathway	Serrated pathway		Hybrid pathway
Heredity	**Hereditary and sporadic (FAP, MUTYH)**	**Hereditary (HNPCC)**	**Hereditary and sporadic**		**Sporadic**
CIMP status	Negative	Negative	CIMP-High	CIMP-High	CIMP-Low
MSI status	MSS	MSI-H	MSI-H	MSI-L / MSS	MSI-L or MSS
Chromosomal instability	Present	Absent	Absent	Absent	Present
***KRAS* mutation**	+++	+/−	−−−	−−−	+++
***BRAF* mutation**	−−−	−−−	+++	+++	−−−
MLH1 status	Normal	Mutation	Methylated	Partial methylation	Normal
MGMT methylation	−−−	−−−	+/−	+++	+++
Precursor lesion			SSA/P	TSA	
Side		RIGHT colon	RIGHT colon	LEFT colon	

Abbreviations: CIMP, CpG island methylator phenotype; MGMT, O-6-methylguanine DNA methyltransferase; MSI, microsatellite instability; MSI-H, high-level microsatellite instability; MSI-L, low-level microsatellite instability; MSS, microsatellite stability.

Annu Rev Pathol Mech Dis 2009 4: 343-364

ARTICLE

Comprehensive molecular characterization of human colon and rectal cancer

2012

The Cancer Genome Atlas (TCGA) integrated molecular classification

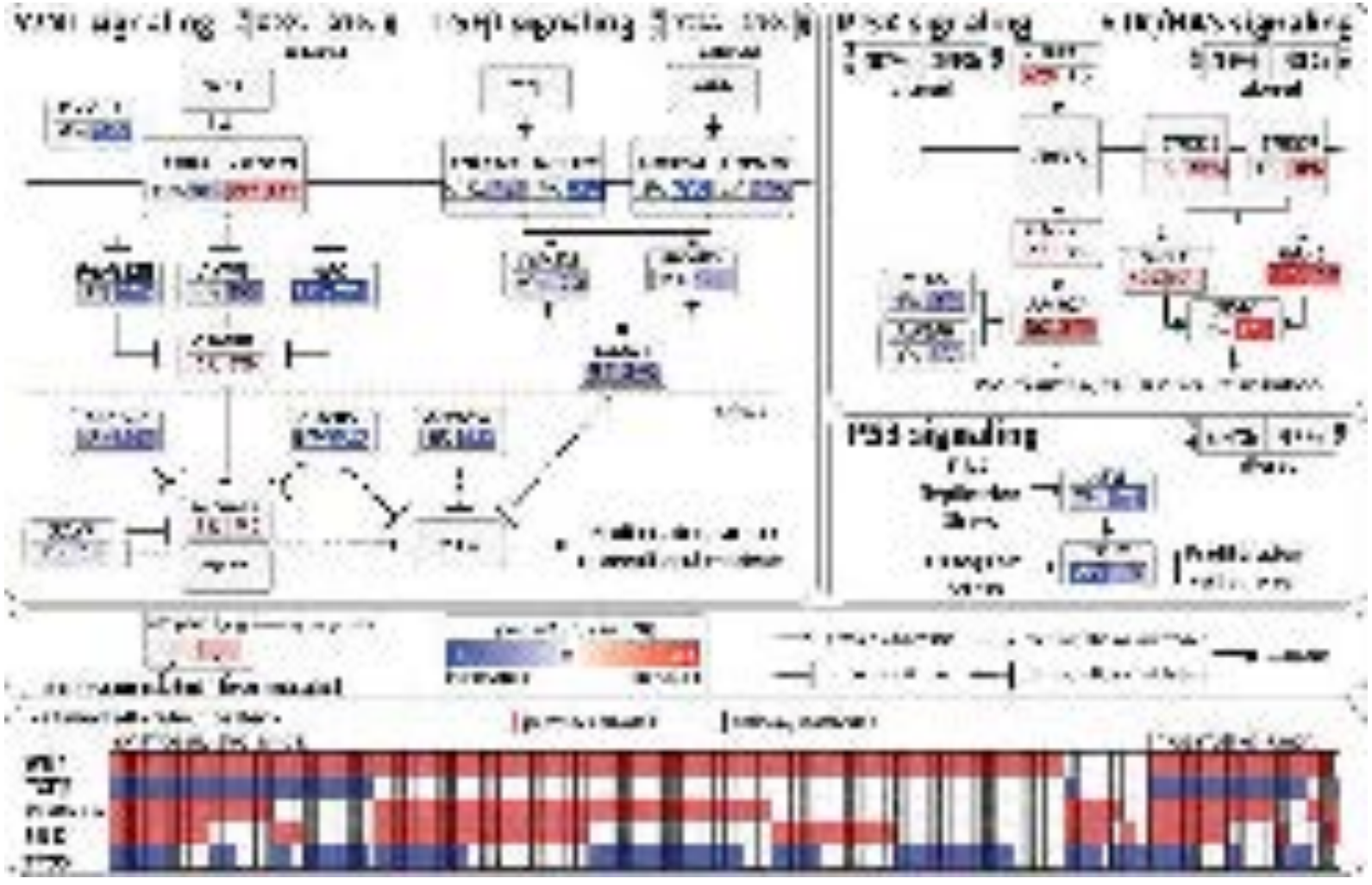

2012
The Cancer Genome Atlas (TCGA) integrated molecular classification

Characteristics of colorectal cancers

Group	(1a) Ultramutated POLE mutant	(1b) Hypermutated dMMR/MSI	(2) CIN/SCNA-high, MSS
Mutation rate	++++	+++	+
Somatic copy number alterations	+/−	+	+++
Key molecular/genetic abnormality	*POLE* EDM proofreading mutation	Defective MMR/MLH1 promoter hypermethylation	Variety of mutated cancer genes; WNT pathway activation (mostly by APC mutation/inactivation)
Predominant histological type	Moderately differentiated adenocarcinoma	Mucinous, or signet ring, or poorly differentiated adenocarcinoma	Moderately differentiated adenocarcinoma
Proportion of all colorectal carcinomas	~3 %	~13 %	~84 %
Prognosis	Good (more data required)	Good/poor after relapse	Good-poor (depending on other characteristics)

CIN chromosomal instability, *POLE* DNA polymerase epsilon, *EDM* exonuclease domain mutant, *SCNA* somatic copy number alteration, *MMR* mismatch repair, *MSI* microsatellite instability

Virchows Arch. 2016; 469: 125–134.

2015
The Consensus Molecular Subtypes of Colorectal Cancer

Proposed taxonomy of colorectal cancer reflecting significant biological differences in the gene expression-based molecular subtypes

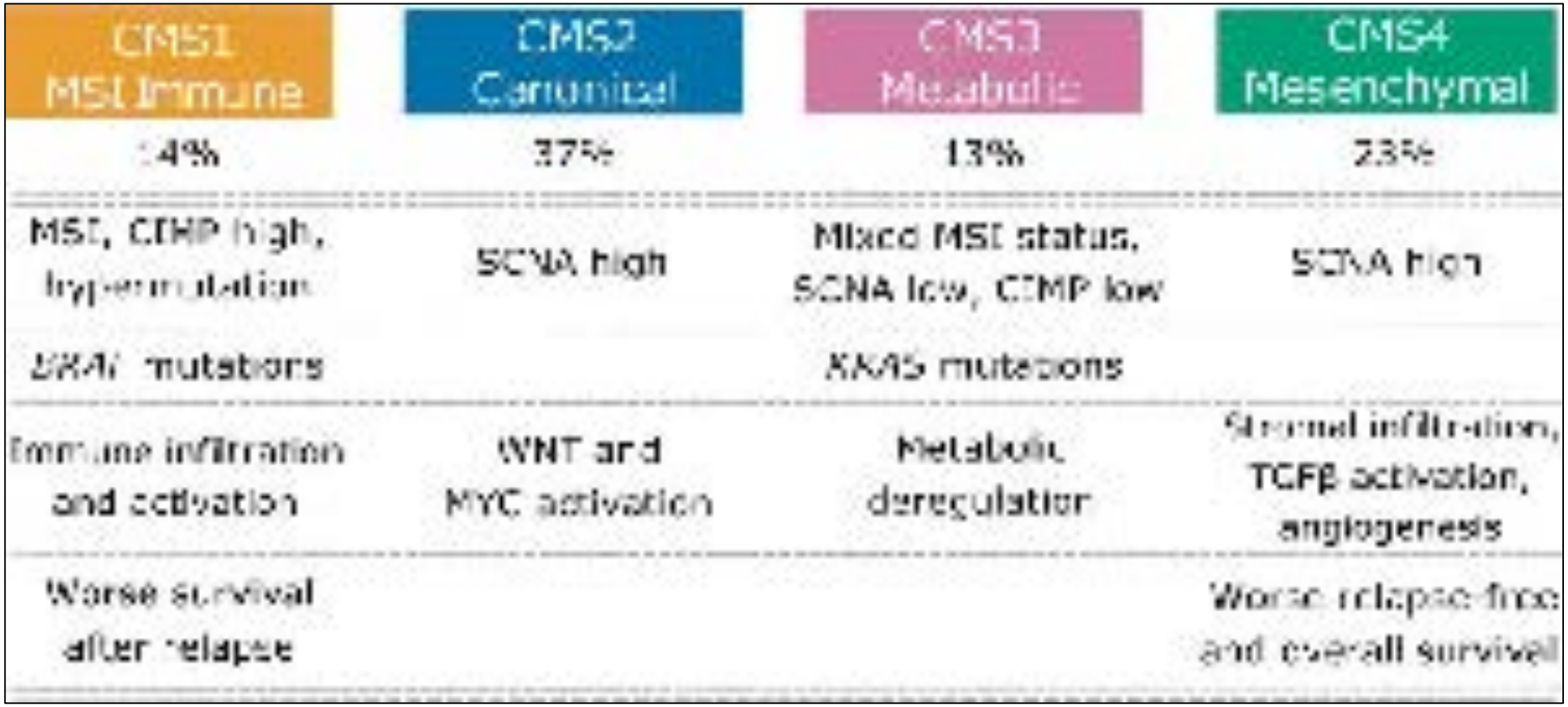

CIMP, CpG Island Methylator Phenotype; MSI, microsatellite instability; SCNA, somatic copy number alterations; TGF, transforming growth factor

Nat Med. 2015 Nov; 21(11): 1350–1356.

Molecular classification systems for colorectal cancers

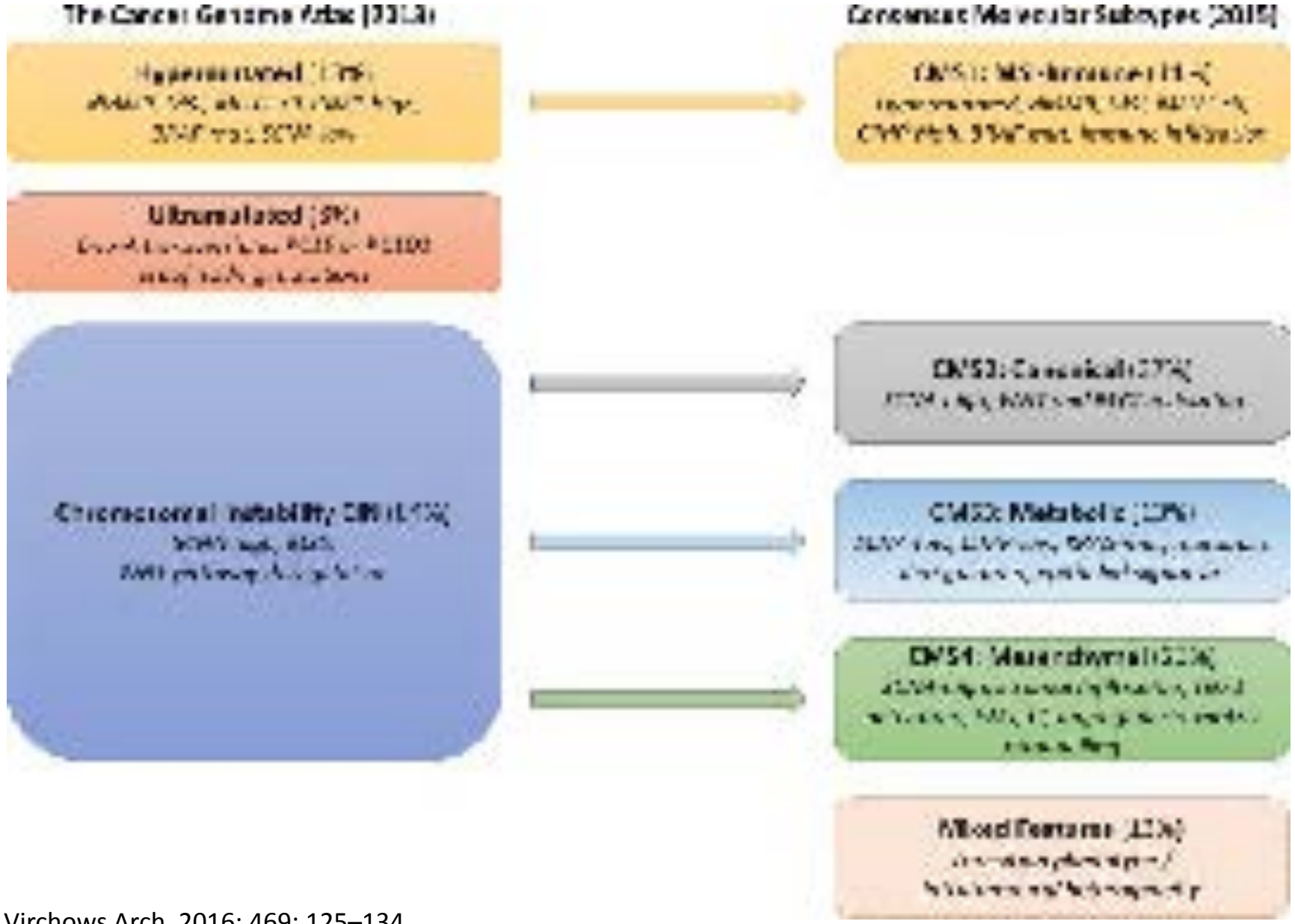

Virchows Arch. 2016; 469: 125–134.

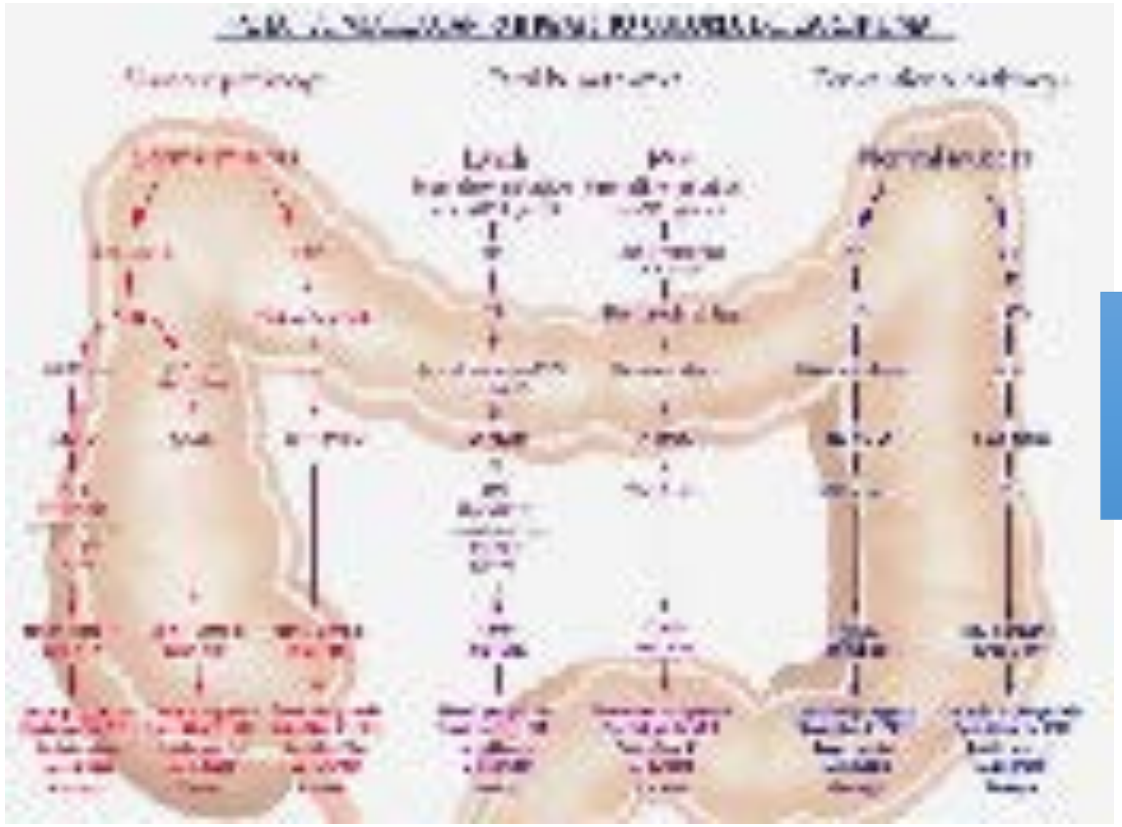

The Cancer Genome Atlas (TCGA) integrated molecular classification (2012)

Characteristics of colorectal cancers

Group	(1a) Ultramutated POLE mutant	(1b) Hypermutated dMMR/MSI	(2) CIN/SCNA-high, MSS
Mutation rate	++++	+++	+
Somatic copy number alterations	+/−	+	+++
Key molecular/genetic abnormality	*POLE* EDM proofreading mutation	Defective MMR/MLH1 promoter hypermethylation	Variety of mutated cancer genes; WNT pathway activation (mostly by APC mutation/inactivation)
Predominant histological type	Moderately differentiated adenocarcinoma	Mucinous, or signet ring, or poorly differentiated adenocarcinoma	Moderately differentiated adenocarcinoma
Proportion of all colorectal carcinomas	~3 %	~13 %	~84 %
Prognosis	Good (more data required)	Good/poor after relapse	Good-poor (depending on other characteristics)

CIN chromosomal instability, *POLE* DNA polymerase epsilon, *EDM* exonuclease domain mutant, *SCNA* somatic copy number alteration, *MMR* mismatch repair, *MSI* microsatellite instability

Virchows Arch. 2016; 469: 125–134.

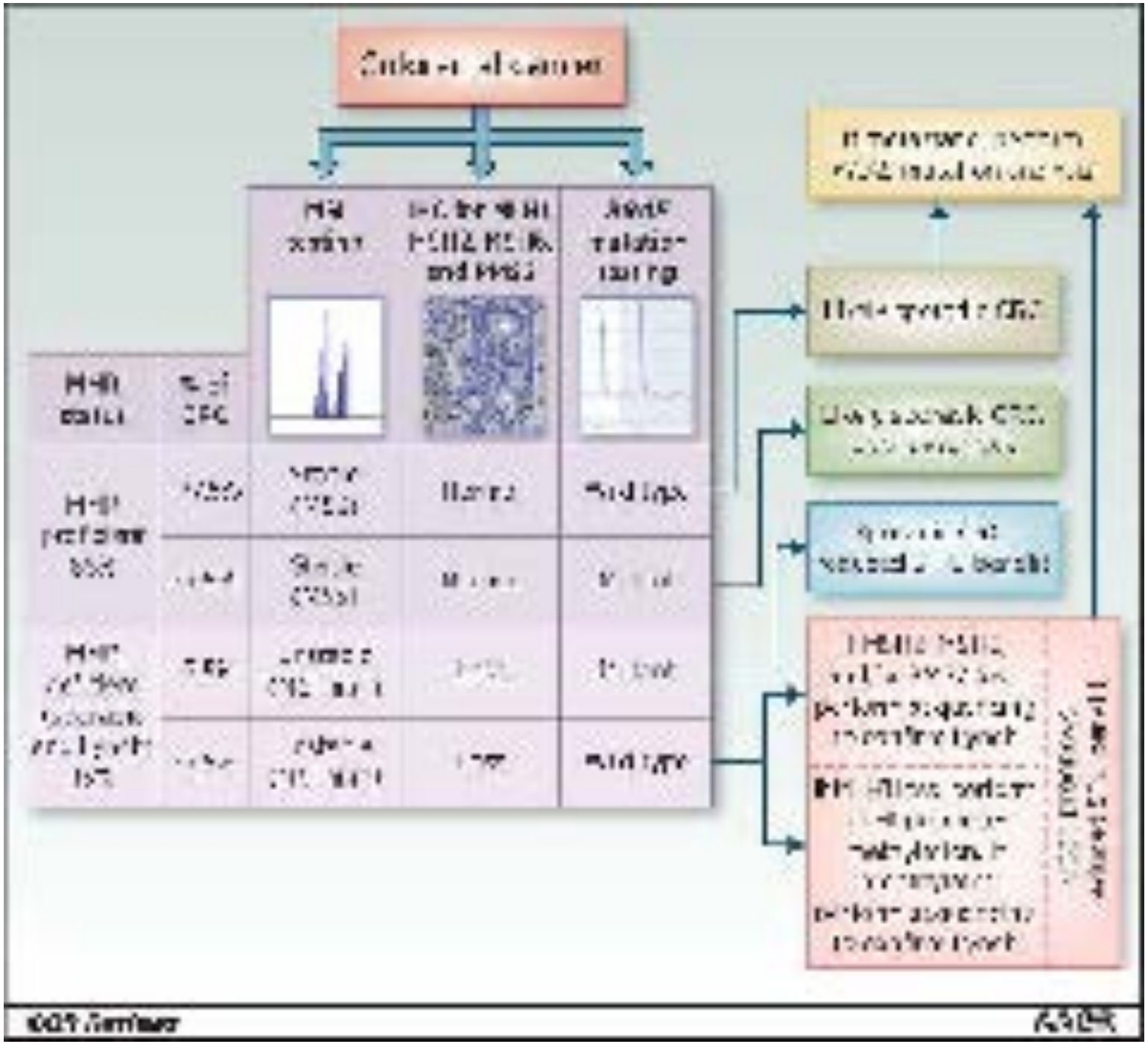

Clin Cancer Res; 22(4); 813–20. 2016

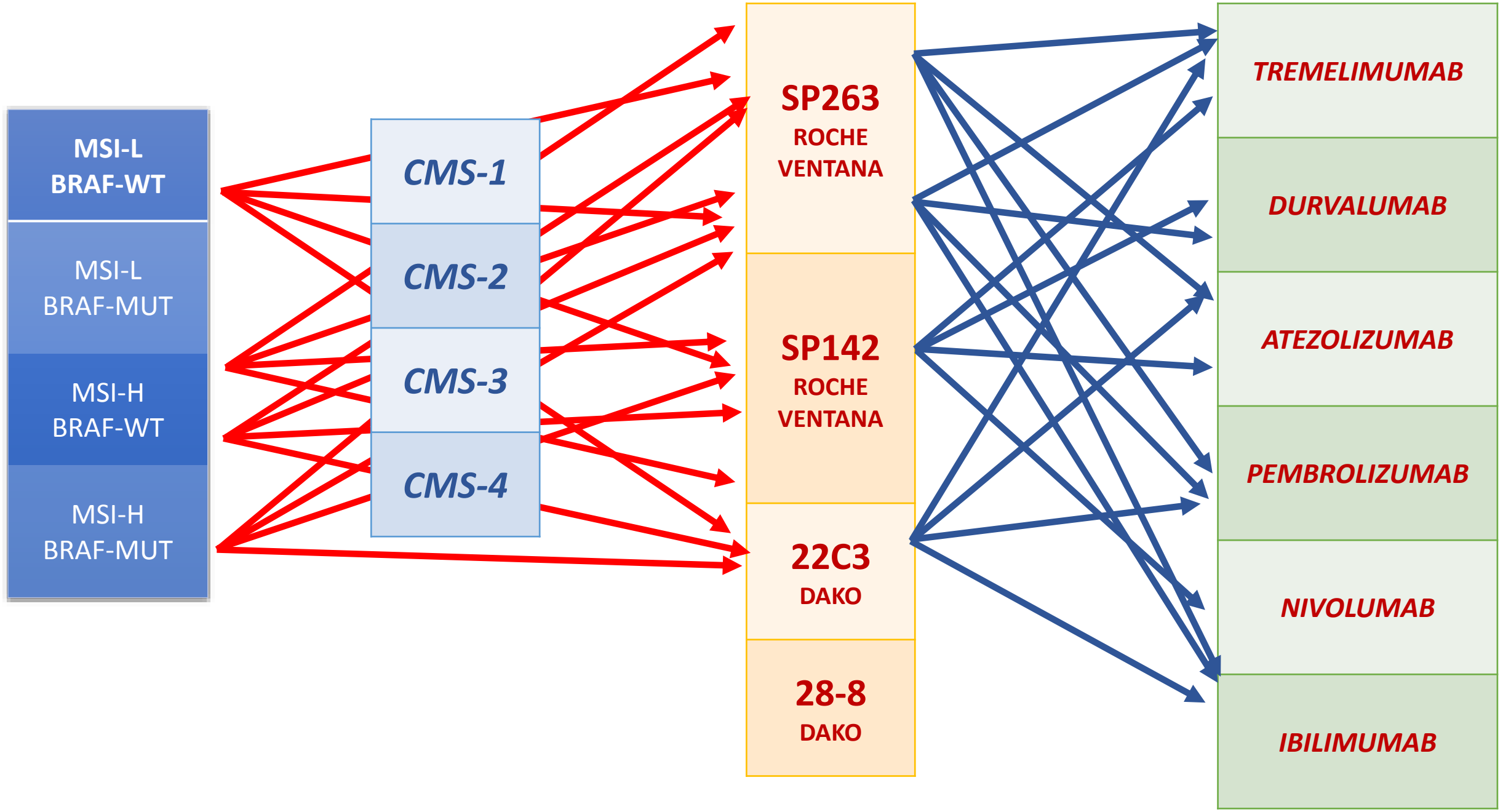
MSI-L
BRAF-WT
MSI-L
BRAF-MUT
MSI-H
BRAF-WT
MSI-H
BRAF-MUT
CMS-1
CMS-2
CMS-3
CMS-4
SP263
ROCHE
VENTANA
SP142
ROCHE
VENTANA
22C3
DAKO
28-8
DAKO
TREMELIMUMAB
DURVALUMAB
ATEZOLIZUMAB
PEMBROLIZUMAB
NIVOLUMAB
IBILIMUMAB

Nel mondo ideale:

- Siamo tutti ben «studiati» (Patologo, chirurgo, clinico)
- Conosciamo i protocolli
- Nel caso specifico applichiamo le conoscenze

Nel mondo reale:

- Il caso specifico ci interroga
- Cerchiamoci e parliamoci
- Studiamo quello che necessita
- Troviamo la strada migliore

(STOP?)

Adenocarcinoma scarsamente differenziato del grosso intestino (rif. a) infiltrante il connettivo periviscerale.
Margini di resezione su pezzo chirurgico e margine radiale indenni da neoplasia.
Metastasi in 4 su 32 linfonodi periviscerali.
Si valutano i seguenti caratteri istoprognostici.
- Modalità di crescita: espansiva (rif. b).
- Infiltrato linfoide peritumorale: moderato (rif. c).
- Reazione desmoplastica stromale: moderata (rif. c).
- Reazione Crohn's-like: presente (rif. d).
- Budding peritumorale: alto grado (13 foci/250x) (rif. e).
- Angioinvasione: presente (rif. f).
- Linfoinvasione: assente (rif. f).
- Neuroinvasione: assente (rif. f).
- Distanza minima dal margine di scollamento circonferenziale (margine radiale) (rif. g): 12 mm.
- Profondità di infiltrazione del connettivo periviscerale: 7 mm (rif. h).

Valutazione dell'espressione immunoistochimica delle proteine del sistema enzimatico MMR ("DNA Mismatch Repair", deputato alla correzione di appaiamenti scorretti delle basi nel DNA) su tessuto neoplastico.
- MSH2 (clone G219-1129): cellule carcinomatose con immunoreattività preservata;
- MLH1 (clone M1): cellule carcinomatose con immunoreattività non preservata;
- MSH6 (clone 44): cellule carcinomatose con immunoreattività preservata;
- PMS2 (clone EPR3947): cellule carcinomatose con immunoreattività non preservata.
Si osserva espressione di PD-L1 nel 20% della componente neoplastica.
(Valutazione dell'espressione di PD-L1 con anticorpo clone 22C3 su sezione istologica in paraffina; piattaforma Ventana):

Stadio TNM (rif. i): pT3(V1), pN2a, G3.

Riferimenti metodologici:
(a) WHO Classification of Tumours. IARC 2010.
(b) Valutazione espressa come: espansiva, infiltrativa (Jass, 1987).
(c) Valutazione espressa come: assente, lieve, moderata, marcata (modificato da Jass, 1987).
(d) Valutazione espressa come: assente, presente (Graham, 1990).
(e) Score di riferimento: 0-9 foci/250x = basso grado; >=10 foci/250x = alto grado (Ueno, 2004).
(f) Valutazione espressa come: osservata; non osservata.
(g) Distanza misurata microscopicamente ed espressa in millimetri (Nagtegaal, Am J Surg Pathol, 2002).
(h) Profondità misurata in mm (UICC, TNM Supplement, 4th edition, pag. 194).
(i) UICC: TNM 8th Edition - 2017.

PD-L1 Assay Systems Used in the Blueprint Project

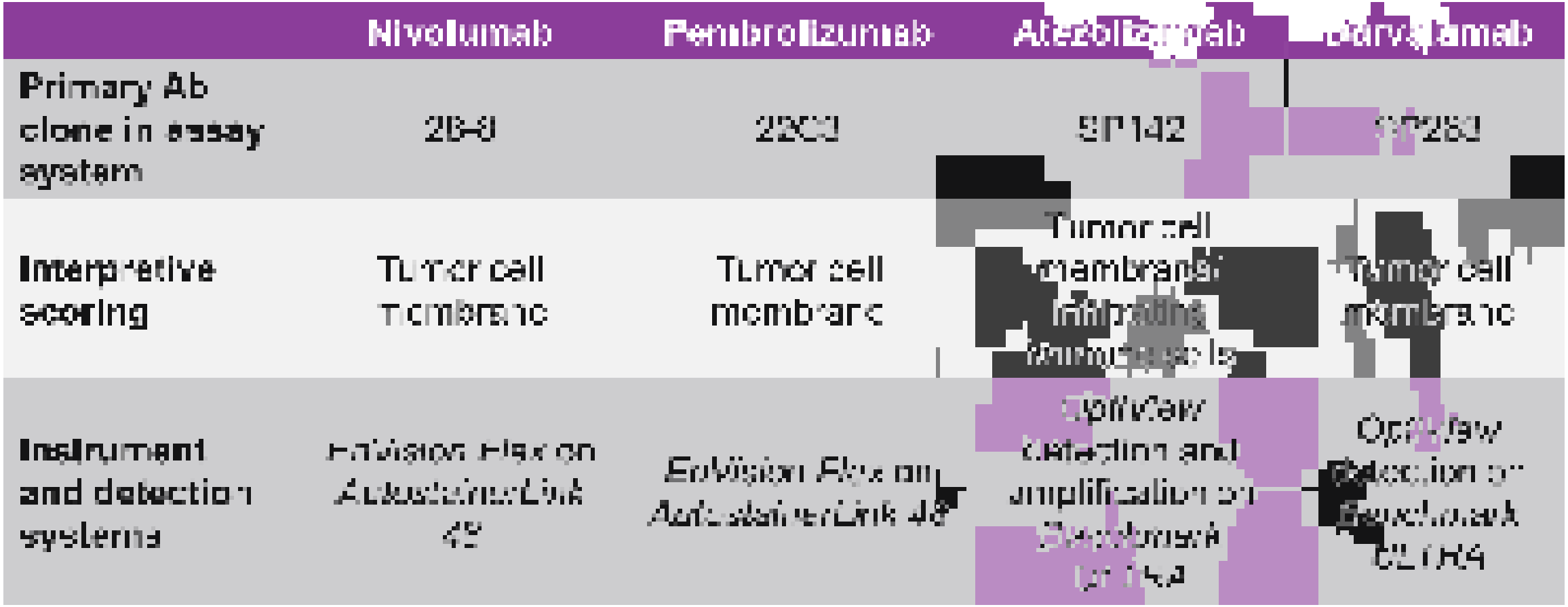

Hirsch FR, et al. J Thorac Oncol. 2017;12:208-222. Blueprint Working Group. Blueprint proposal. 2015.

Table 1 Biomarker assays for anti-PD-1/PD-L1 drugs and associated outcomes

Example	Drug	Primary Target	Cut-off[a]	ORR[b]	CR	PFS[c]	OS[d]
Exploratory analysis[e][f][g]	Nivolumab	PD-1[h]	1%	26%	4%	3.5	9.2
Exploratory analysis[e][f][g]	Durvalumab (MEDI4736)	PD-L1	25%	43.6%	2.9%	12.3	49.9
Exploratory analysis[e][f][g]	Durvalumab	PD-L1 (SP263)	25%	16%	0%	1.9	10.6
Exploratory analysis[e][f][g]	Pembrolizumab	Activated NFAT	20%	18%	4%	7.2	21.8
Exploratory analysis[e][f][g]	Pembrolizumab	Interferon Gamma	1%	37%	3%	3.7	11.1
Dose 1[e][f]	Atezolizumab	PD-L1	1%	15%	1%	2.7	13.8
Dose 2[e][f]	Atezolizumab	PD-L1	5%	23%	4%	2.8	15.7
Dose 3[e][f]	Atezolizumab	Macrophage	10%	26%	10%	3.0	15.7
Dose 4[e][f]	Nivolumab	PD-L1 (Dako 28-8)	1%	19%	0%	3.5	10.6
Dose 5[e][f]	Nivolumab	PD-L1 (SP142)	5%	15%	3%	2.7	9.7
Dose 6[e][f]	Nivolumab	Macrophage	5%	24%	4%	3.5	19.9
Dose 7[e][f]	Nivolumab + Ipilimumab	Macrophage	1%	27%	5%	5.5	17.5

[a]PD-L1 cut-off for tumor cell staining. [b]Cut-off for proportion of tumor cells expressing PD-L1 below which tumor is considered PD-L1 negative. [c]PFS: Objective response rate (complete response + partial response). [d]Time to progression. [e]Time to death. [f]Efficacy of immunotherapy in relation to expression of PD-L1 by tumor cells. [g]Predictive biomarker analysis based on published results. [h]Specificity of immunotherapy for predicting response to PD-1 blockade based on measurement of PD-L1 and PD-1 based on weighted average of corresponding PD-L1 scores

Reproducibility of PD-L1 IHC Platforms

- Prospective multicenter comparison by 13 pathologists using 4 IHC assays to score PD-L1 expression on archival NSCLC samples (N = 90)

Primary Ab Clone	Mean PD-L1 Score	
	Tumor Cells	Immune Cells
22C3	2.36	2.15
28-8	3.26	2.23
SP142	1.99	1.62
E1L3N	3.20	2.23
Overall mean	**2.85**	**2.08**

Rimm DL, et al. JAMA Oncol. 2017;[Epub ahead of print].

MSI-H CRC: H&E Stain

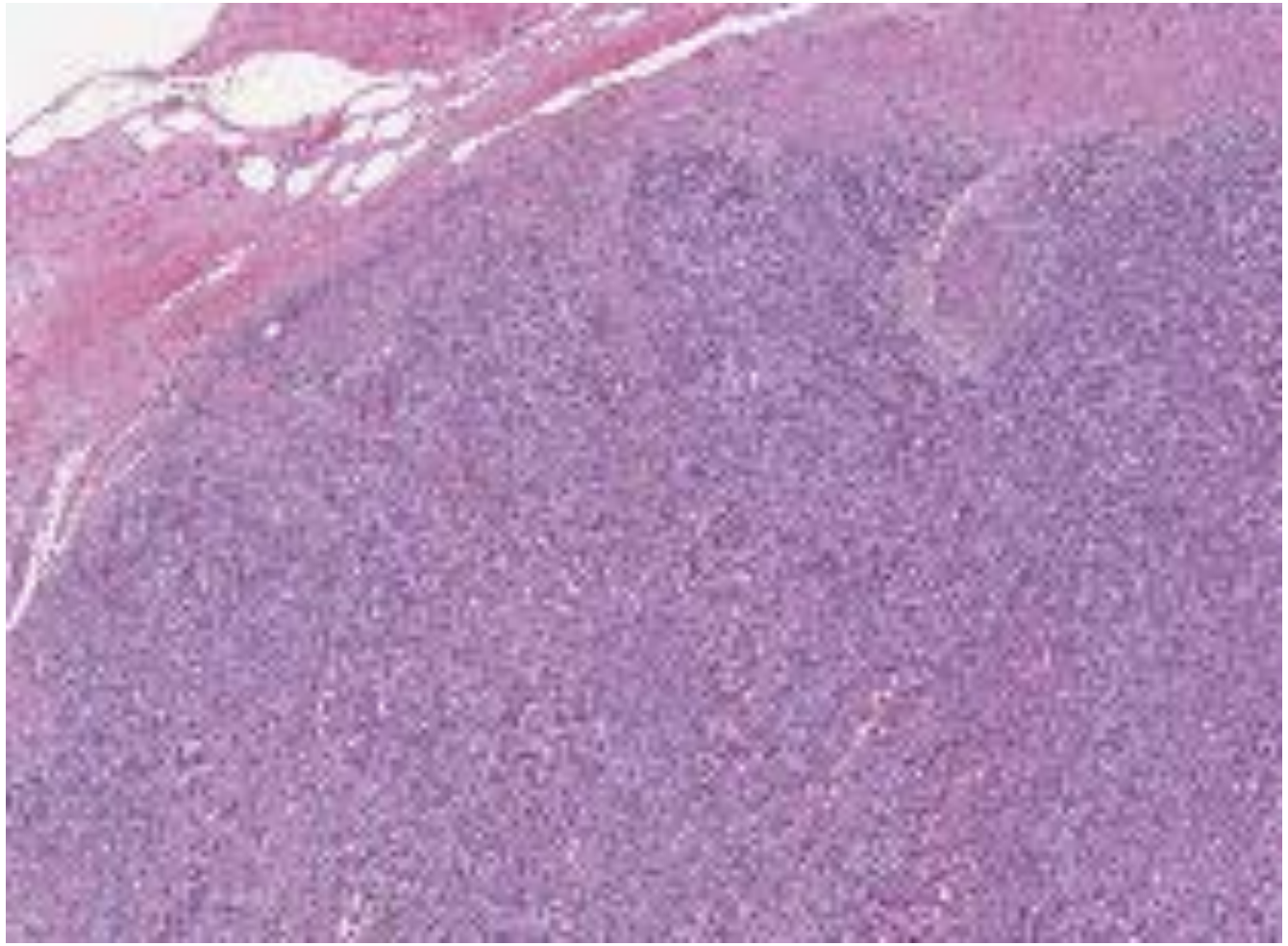

IHC Staining for PD-L1

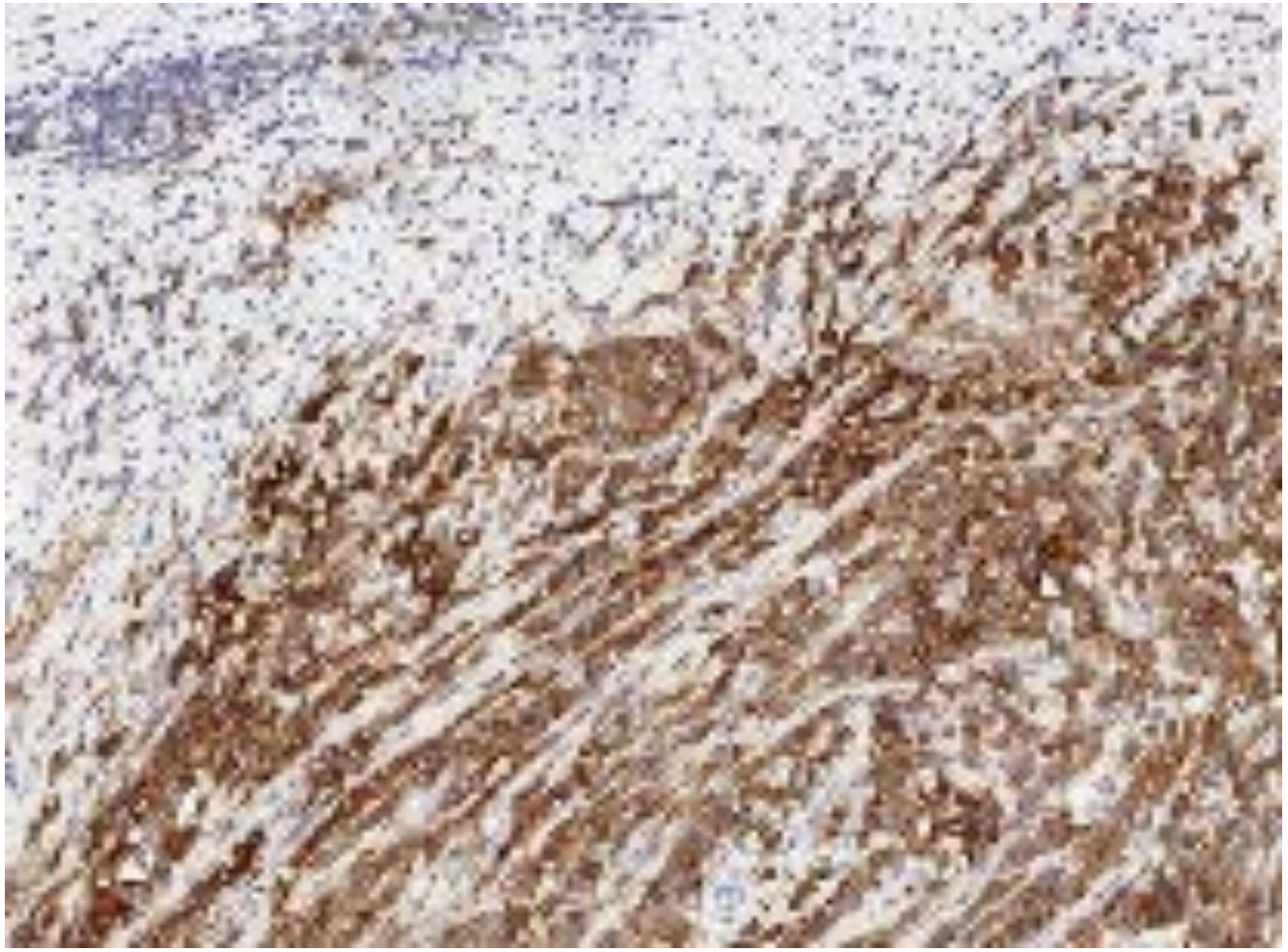

IHC Staining for CD4 (Left) and CD8 (Right)

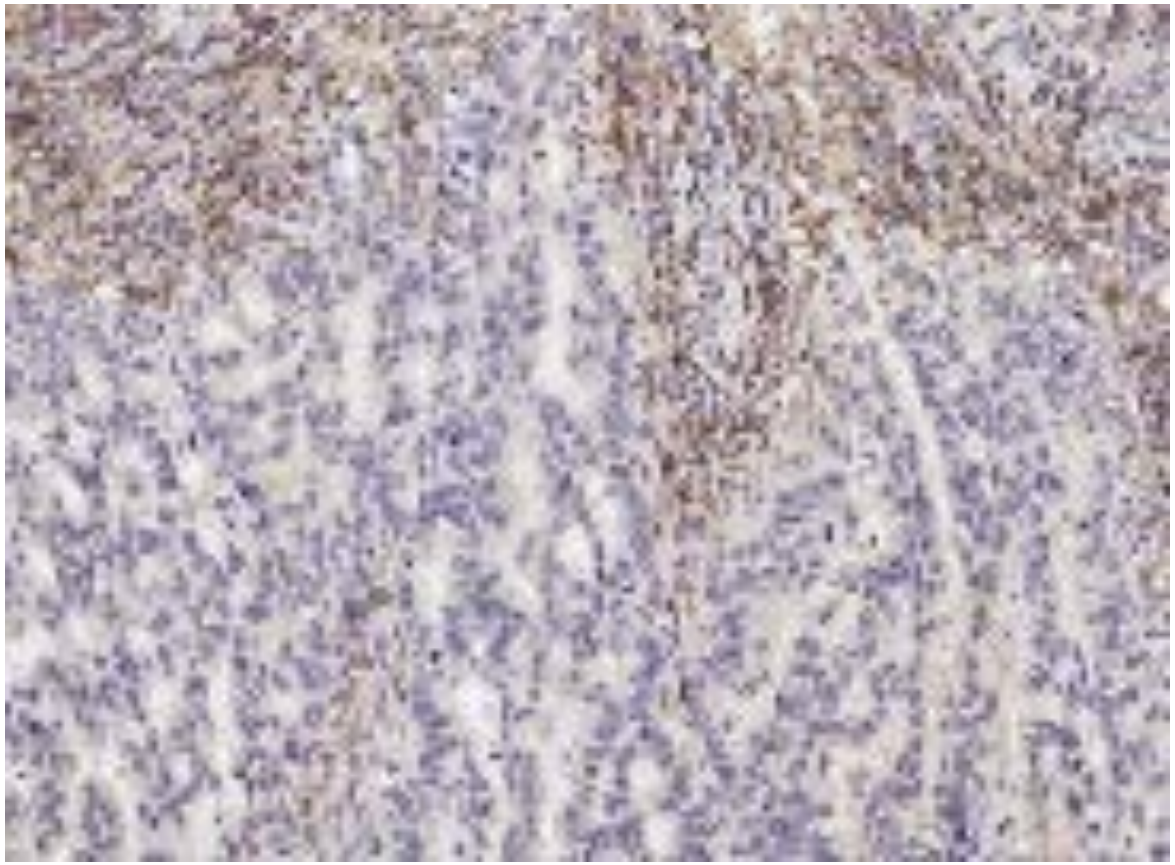

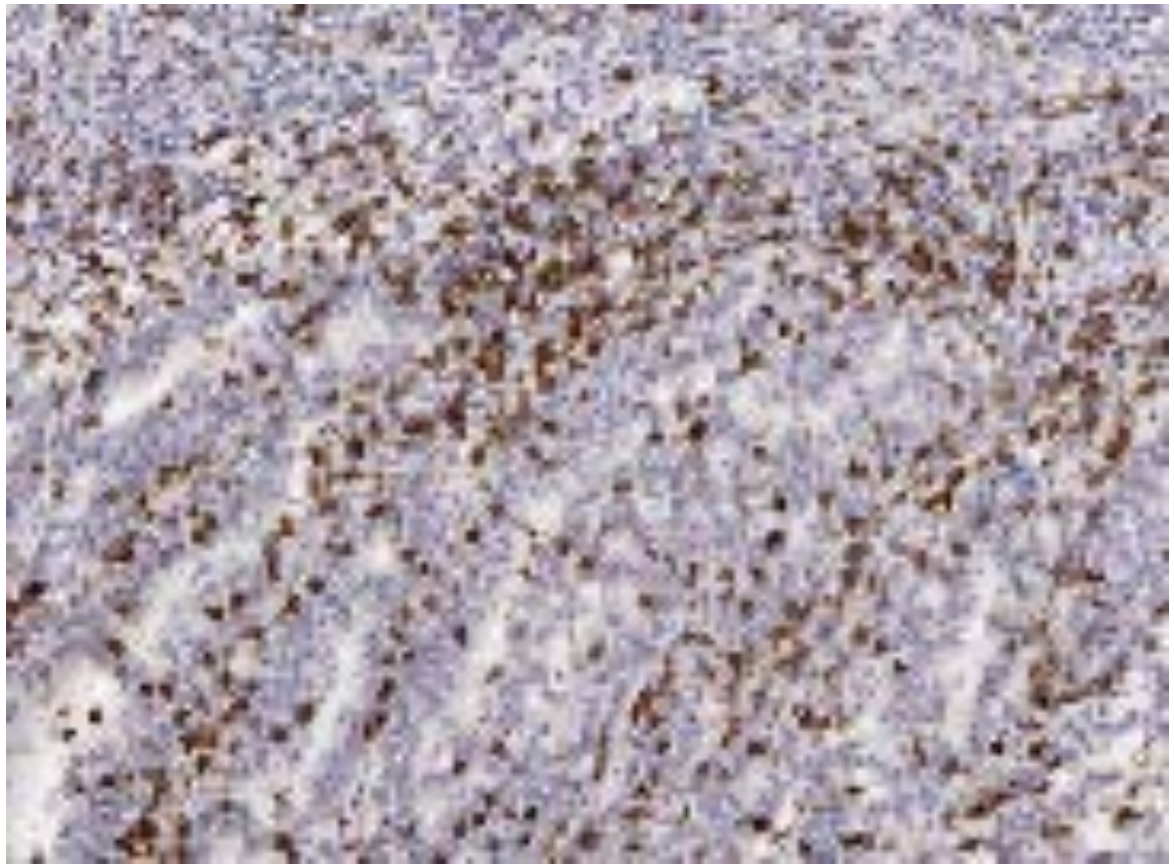

High Expression of HLA on Tumor Cells and FOXP3 on Immune Cells in MSI-H CRC

HLA

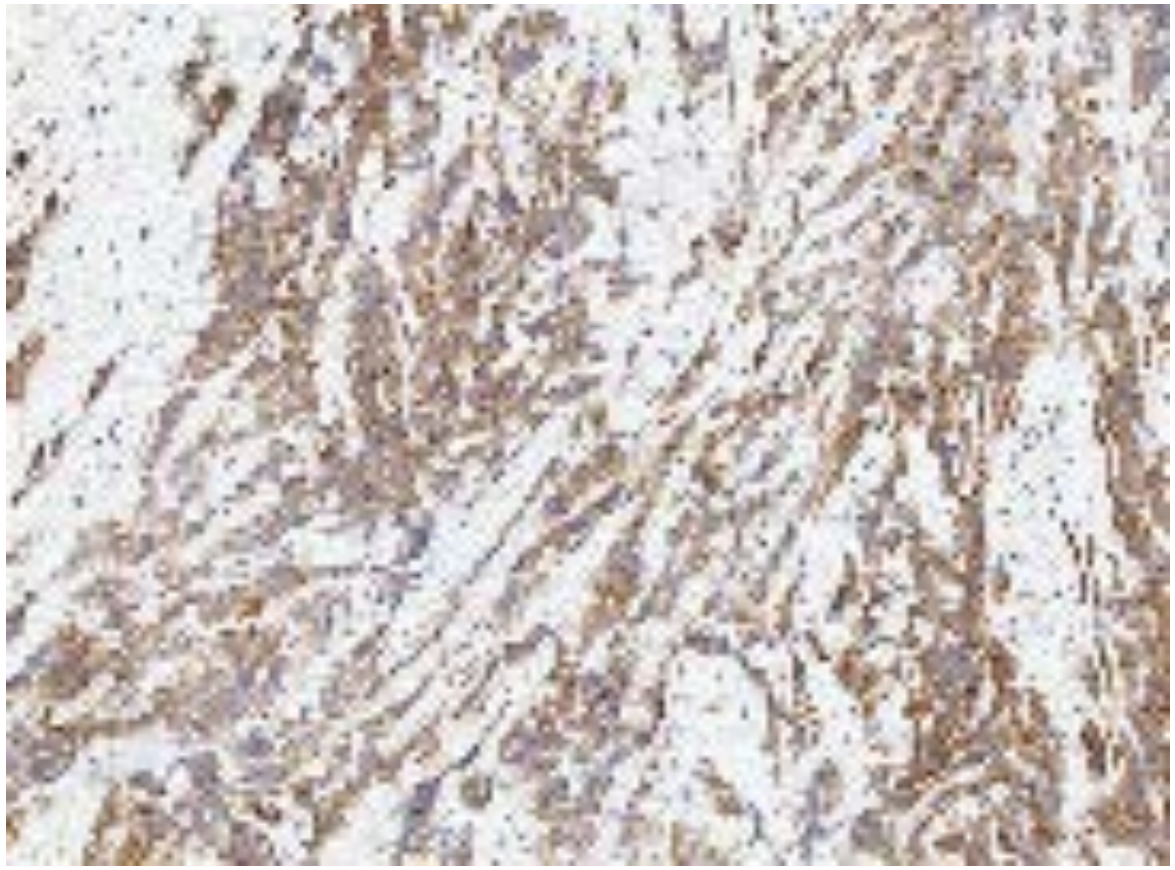

FOXP3

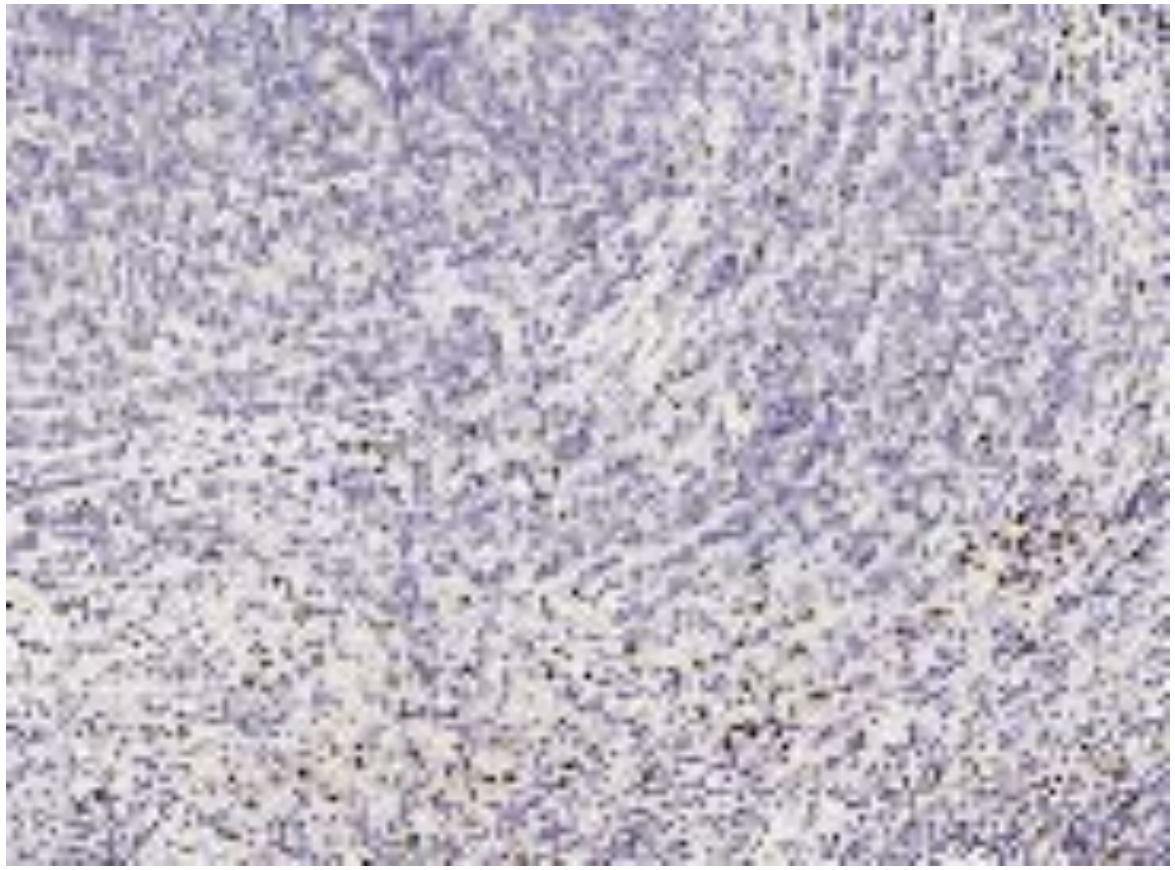

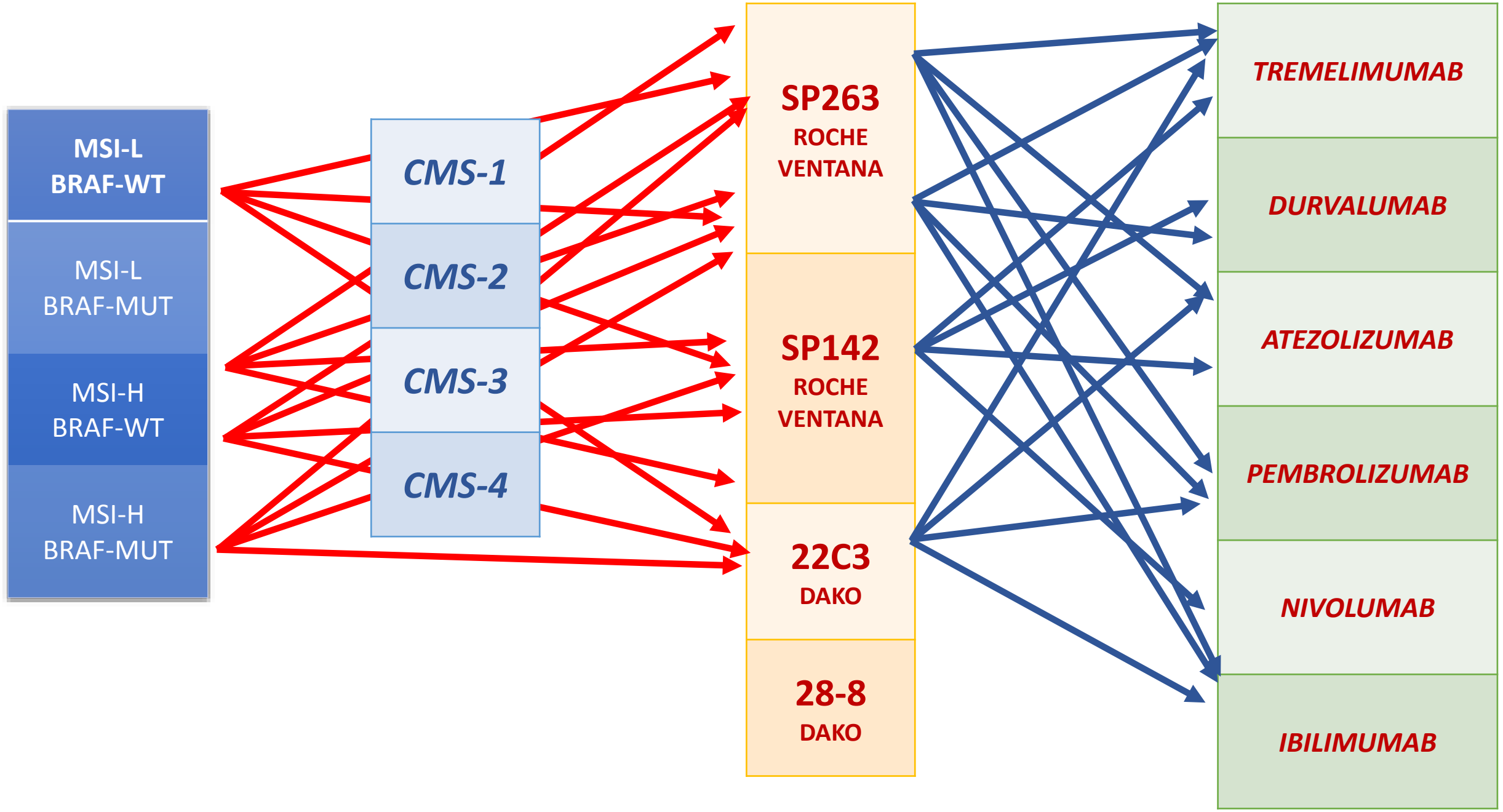
MSI-L
BRAF-WT
MSI-L
BRAF-MUT
MSI-H
BRAF-WT
MSI-H
BRAF-MUT
CMS-1
CMS-2
CMS-3
CMS-4
SP263
ROCHE
VENTANA
SP142
ROCHE
VENTANA
22C3
DAKO
28-8
DAKO
TREMELIMUMAB
DURVALUMAB
ATEZOLIZUMAB
PEMBROLIZUMAB
NIVOLUMAB
IBILIMUMAB

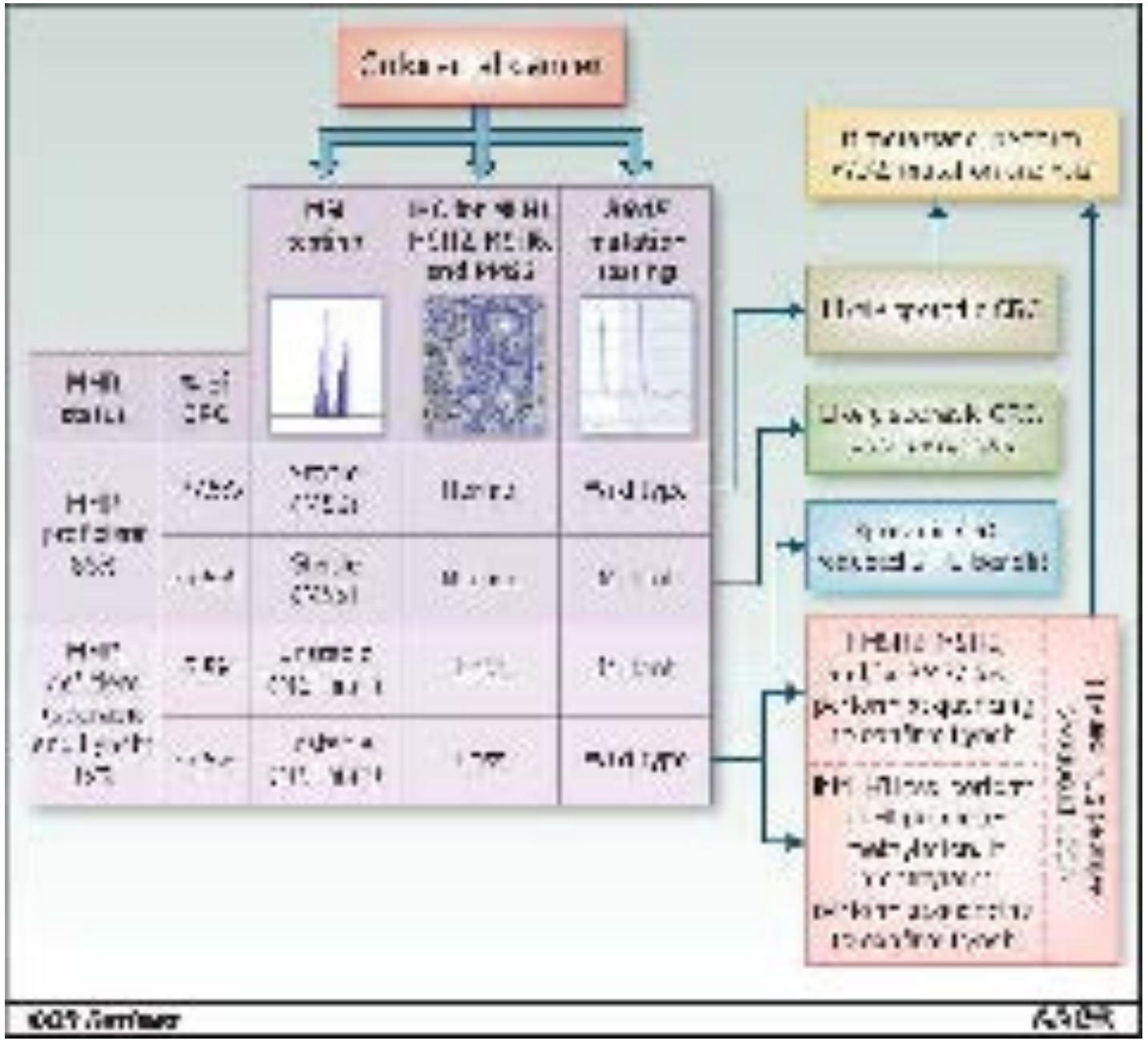

Clin Cancer Res; 22(4); 813–20. 2016

NOTE DI “SEMANTICA”
DELLE LESIONI NEOPLASTICHE EPITELIALI INIZIALI
DEL COLON-RETTO

Lesioni epiteliali neoplastiche del tratto GI: «assiomi linguistici»

➡ ***displasia***

➡ ***carcinoma***

Linguistica delle lesioni epiteliali neoplastiche del tratto gastroenterico: STOMACO

Les. neoplastica contenuta entro l'epitelio («membrana basale» NON superata) → *displasia* → *NO MTS*

Les. neoplastica estesa oltre l'epitelio («membrana basale» superata) → *carcinoma* → *MTS*

τάξις

1977

νόμος

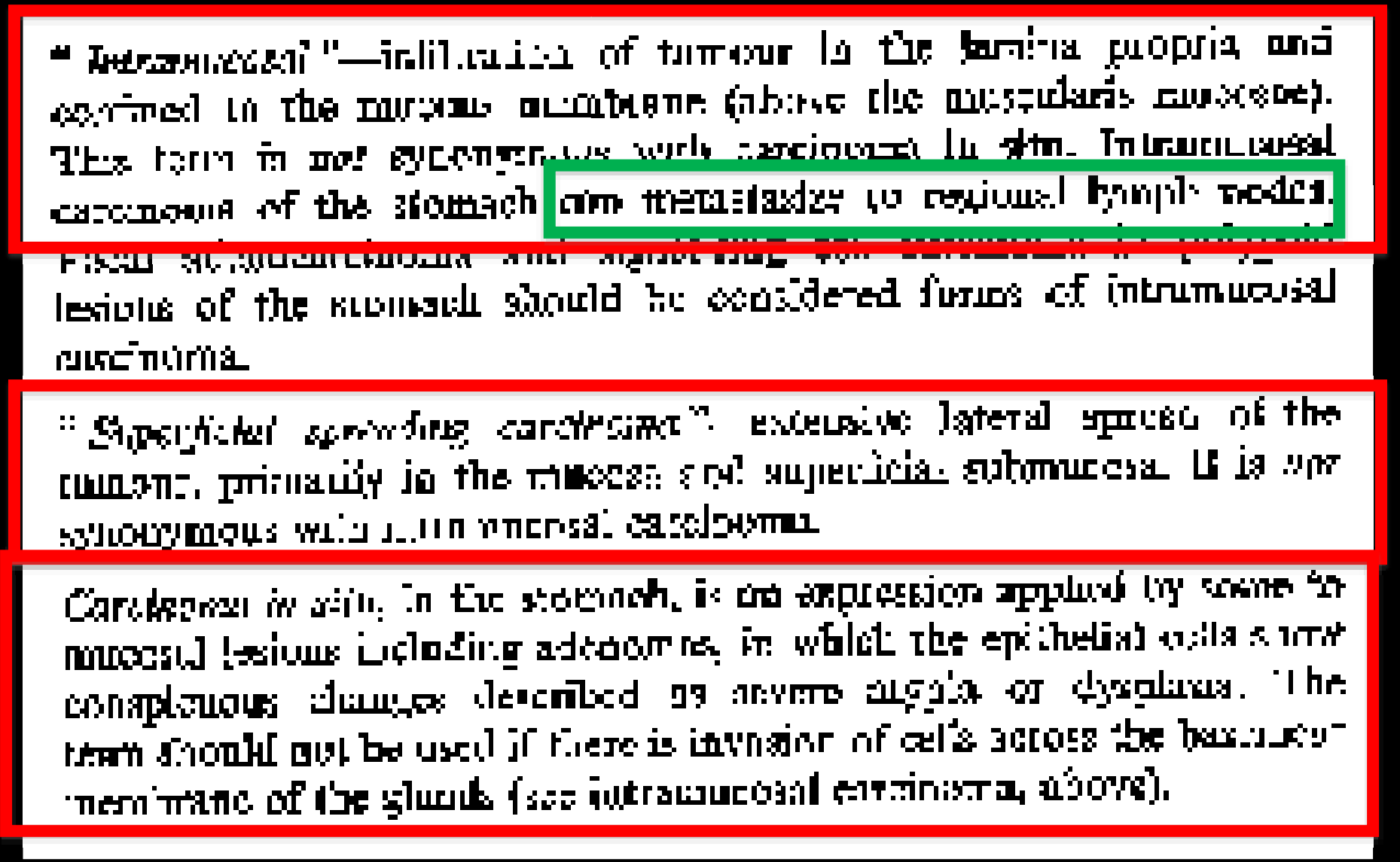

Stomach, WHO 1976

τάξις

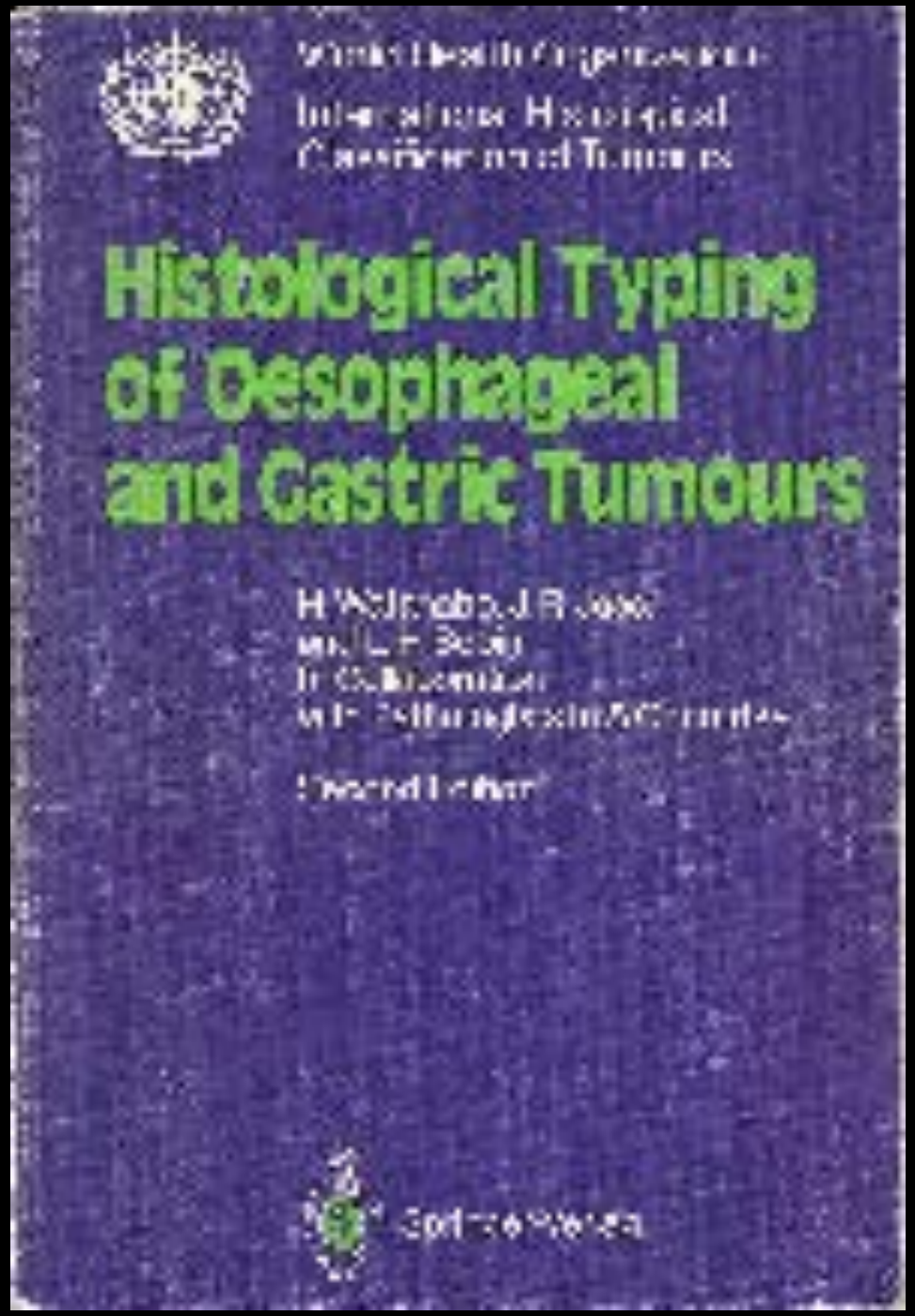

1990

νόμος

Superficial spreading carcinoma: extensive lateral spread of the tumour, primarily in the mucosa and superficial submucosa. It is not synonymous with intramucosal carcinoma.

Carcinoma in situ: adenocarcinoma which has not invaded the lamina propria (Sect. 8). This diagnosis may be difficult or impossible to make with certainty especially on endoscopic biopsy.

Intramucosal carcinoma: carcinoma has spread within the lamina propria but not beyond the muscularis mucosae. Lymph node metastasis is found in about 2%–3% of the cases.

Stomach,
WHO 1990

Ma nel
1996
accadde
che...

→ *Digestive Disease Week (USA, 1996)*

Un gastroenterologo giapponese presenta immagini istologiche di “Early Gastric Carcinoma” limitato alla mucosa. Qualche patologo, in platea, osserva che si tratta di “dysplasia”

→ *Ronald Schlemper* (gastroenterologo olandese che lavora in Giappone) osserva che “carcinoma” in giapponese ≠ “carcinoma” in lingua inglese; organizza uno slide-seminar in Tokyo con patologi occidentali e patologi giapponesi -> valutazione comune di lesioni gastriche

Differences in diagnostic criteria for gastric carcinoma between Japanese and Western pathologists

[illegible]

Lancet 1997; 349: 1725–29

Interpretation In Japan, gastric carcinoma is diagnosed on nuclear and structural criteria even when invasion is absent according to the Western viewpoint. This diagnostic practice [illegible]

	Japanese viewpoint		Total
	Adenoma or atypical epithelium	Intramucosal carcinoma	
Western viewpoint			
Adenoma or atypical epithelium	2	7	27
[illegible]	0	4	8
Total	2	31	35

Table 4: Agreement between viewpoints for all 35 slides

Occidente vs Giappone: sulla classificazione delle neoplasie gastriche iniziali

➔ 2 differenti sistemi x diagnosi di “carcinoma”!

Occidente = criterio dell’infiltrazione del connettivo;
Giappone = criterio citologico (forma del nucleo), indipendentemente dal carattere infiltrativo;

Lesioni classificate in occidente come “displasia” sono classificate in Giappone come “adenocarcinoma”

*Problema “**SEMANTICO**”*

Questo problema “SEMANTICO” era così irrilevante?

Nuovi casi di carcinoma gastrico diagnosticati nel 1998 in Istituti occidentali e in Giappone

Patologo	*Sede*	*n. casi*
K Lewin	Los Angeles, USA	27
R Riddell	Hamilton, Canada	20
P Sipponen	Espoo, Finland	19
M Stolte	Bayereuth, Germany	782
M Itabashi	Tomobe, Japan	97
Y Kato	Tokyo, Japan	400
T Shimoda	Tokyo, Japan	350
H Watanabe	Niigata, Japan	500

Virchows Arch 2003, 442: 99-106

I patologi cercano di “parlarsi”:

- *aprile 1998* → Consensus Meeting in Padova

Gastric Dysplasia

The Padova International Classification

Massimo Rugge, M.D., Pelayo Correa, M.D., Michael F. Dixon, M.D., Takanori Hattori, Ginacchino Leandro, M.D., Klaus Lewin, M.D., Robert H. Riddell, M.D., Pentti Sipponen, M.D., and

The American Journal of Surgical Pathology 24(2): 167–176, 2000

TABLE 1. Gastric dysplasia and related lesions: the Padova classification

1. Negative for dysplasia
   1.1 Reactive foveolar hyperplasia
   1.2 Intestinal metaplasia (IM)
      1.2.1 IM Complete type
      1.2.2 IM Incomplete type
2. Indefinite for dysplasia
   2.1 Foveolar hyperproliferation
   2.2 Hyperproliferative IM
3. Non-invasive neoplasia (flat or elevated [synonym adenoma])
   3.1 Low-grade
   3.2 High-grade
      3.2.1 Including suspicious for carcinoma without invasion (intraglandular)
      3.2.2 Including carcinoma without invasion (intraglandular)
4. Suspicious for invasive carcinoma
5. Invasive adenocarcinoma

Come «se la passava» la semantica delle lesioni del grosso intestino?

Lesioni epiteliali neoplastiche del tratto gastroenterico: «assiomi linguistici»

Les. neoplastica contenuta entro l'epitelio («membrana basale» NON superata) ➡ ***displasia***

Les. neoplastica estesa oltre l'epitelio («membrana basale» superata) ➡ ***carcinoma***

Linguistica delle lesioni epiteliali neoplastiche del tratto gastroenterico: GROSSO INTESTINO

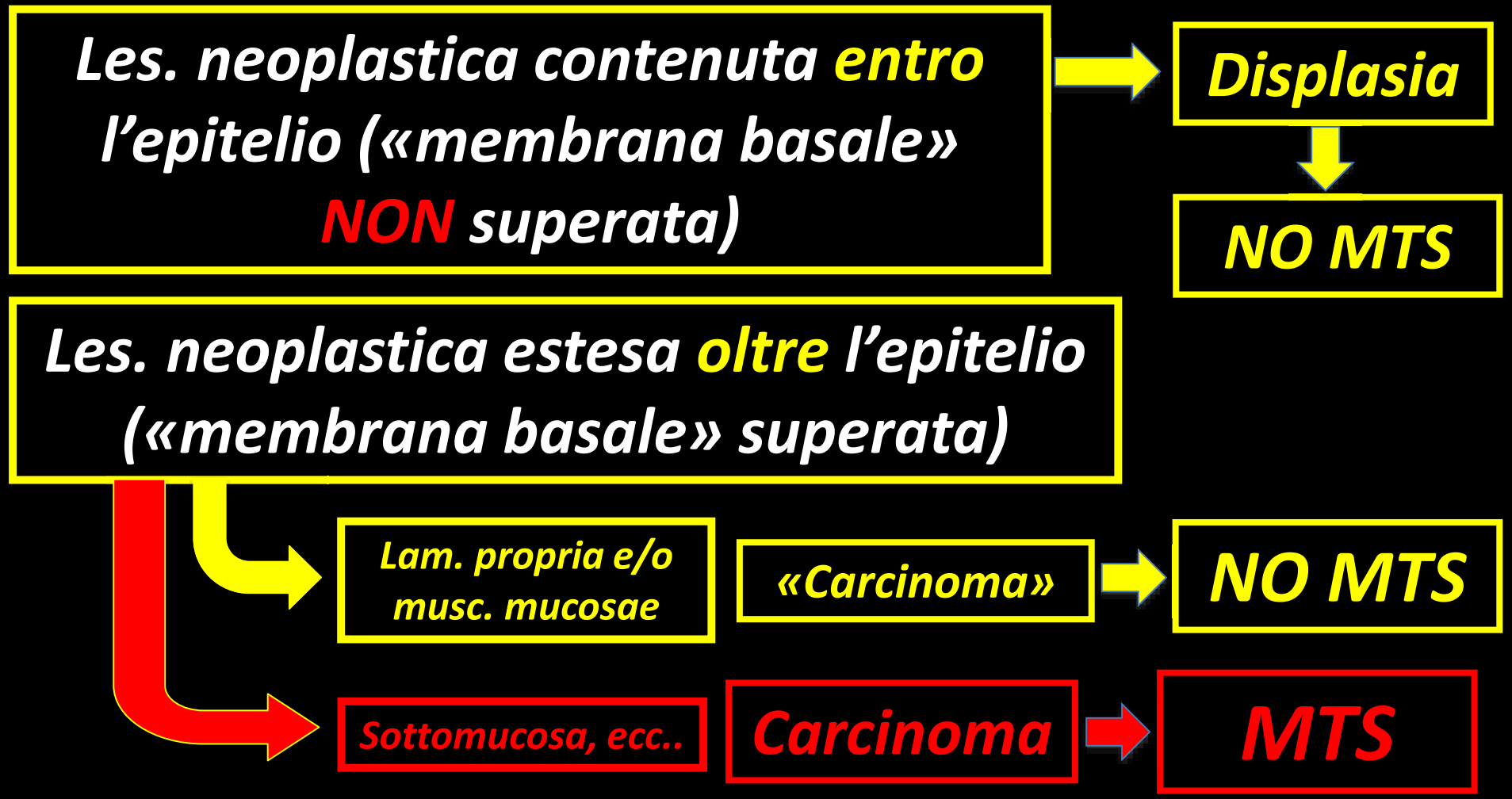

τάξις



1976

νόμος

Large intestine
Epithelial tumours

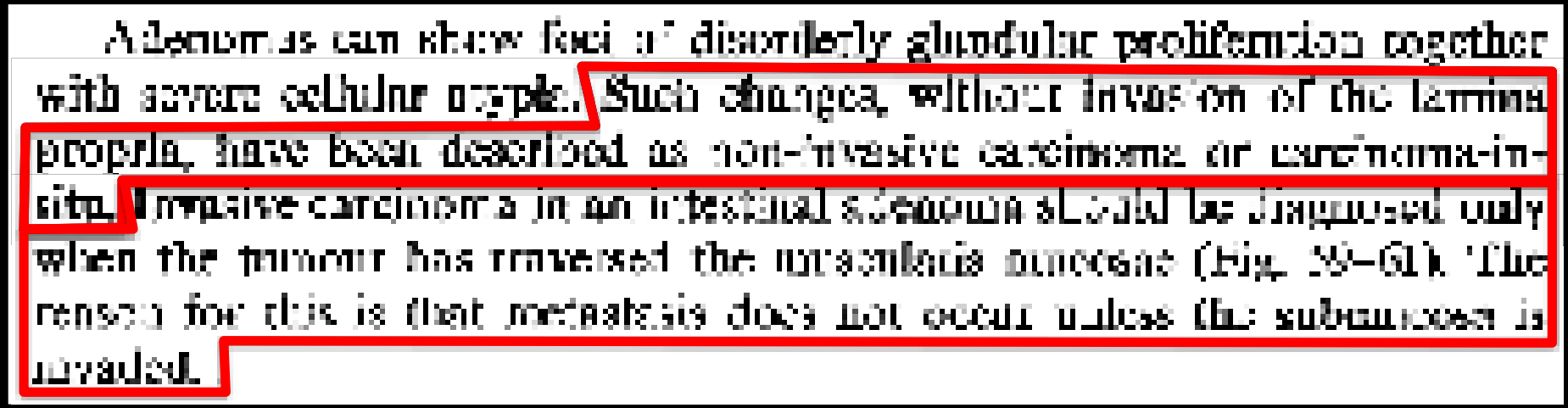

Adenomas can show foci of disorderly glandular proliferation together with severe cellular atypia. Such changes, without invasion of the lamina propria, have been described as non-invasive carcinoma or carcinoma-in-situ. Invasive carcinoma in an intestinal adenoma should be diagnosed only when the tumour has traversed the muscularis mucosae (Fig. 59–61). The reason for this is that metastasis does not occur unless the submucosa is invaded.

WHO 1976

τάξις

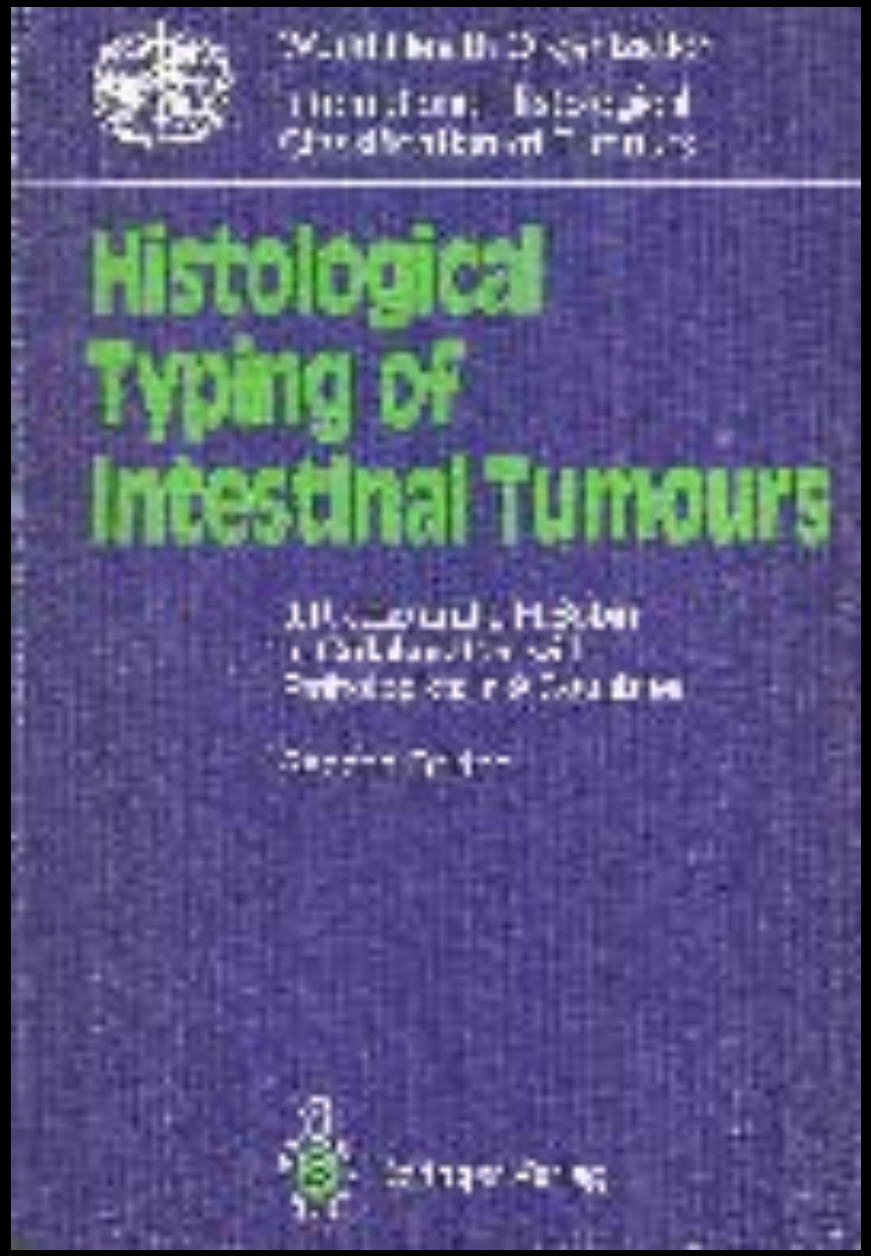

1989

νόμος

Large intestine - Epithelial tumours

It is not unusual to see several grades of dysplasia within one adenoma. The diagnostic grade is based on the most severely dysplastic area. When there is invasion by neoplastic epithelium into the lamina propria but no penetration beyond the muscularis mucosae, the descriptive term 'intramucosal carcinoma' is strictly speaking correct. However, intramucosal carcinoma of the colon has not been shown to metastasize, and for this reason 'carcinoma in situ' is more appropriate. Invasive carcinoma should only be reported when spread through the muscularis mucosae into the submucosa has been demonstrated. To prevent potential confusion, the term 'intramucosal carcinoma' is best avoided in the large bowel. The term 'borderline carcinoma' should likewise be avoided since it does not indicate whether invasion into the submucosa has occurred.

WHO 1989

→ *Sempre* *Ronald* *Schlemper* (il gastroenterologo olandese che lavora in Giappone) osserva che “carcinoma” in giapponese significa qualcosa di diverso rispetto a “carcinoma” in lingua inglese; organizza uno slide-seminar in Tokyo con patologi occidentali e patologi giapponesi -> valutazione comune di lesioni del grosso intestino **(Cancer 1998, 82 60)**

Differences in the Diagnostic Criteria Used by Japanese and Western Pathologists to Diagnose Colorectal Carcinoma

[redacted]

It is our impression that Japanese pathologists often use the term "colorectal carcinoma" to describe lesions that Western pathologists consider to be adenomas. To test this hypothesis, each pathologist was

[redacted]

TABLE 4
[redacted]

		Type of response	
		[redacted]	[redacted]
[redacted]	[redacted]	[redacted]	[redacted]
	[redacted]	[redacted]	[redacted]
[redacted]		[redacted]	[redacted]

Background

Large discrepancies between Western and Japanese pathologists have been found in the diagnosis of adenoma/dysplasia versus carcinoma for gastric and colorectal glandular lesions and for oesophageal squamous lesions. These differences in diagnostic criteria have caused considerable problems in the interpretation of Japanese cancer research by Western clinicians and researchers, and vice versa. These discrepancies therefore called for a united effort to reach a consensus on the nomenclature of gastrointestinal epithelial neoplastic lesions.

Esigenza di utilizzare una terminologia omogenea per stomaco e grosso intestino, per rendere più semplice la comunicazione tra produttori e fruitori di diagnosi:

1) rendere univoci i termini
2) rendere univoci i concetti significati dai termini
3) Produrre una classificazione «universalmente accettata»

- *Aprile 1998* → Consensus Meeting in Padova (solo x stomaco!)
- *Settembre 1998* → World Congress in Gastroenterology in Vienna
- *2000* → "The Vienna classification of gastrointestinal epithelial neoplasia."

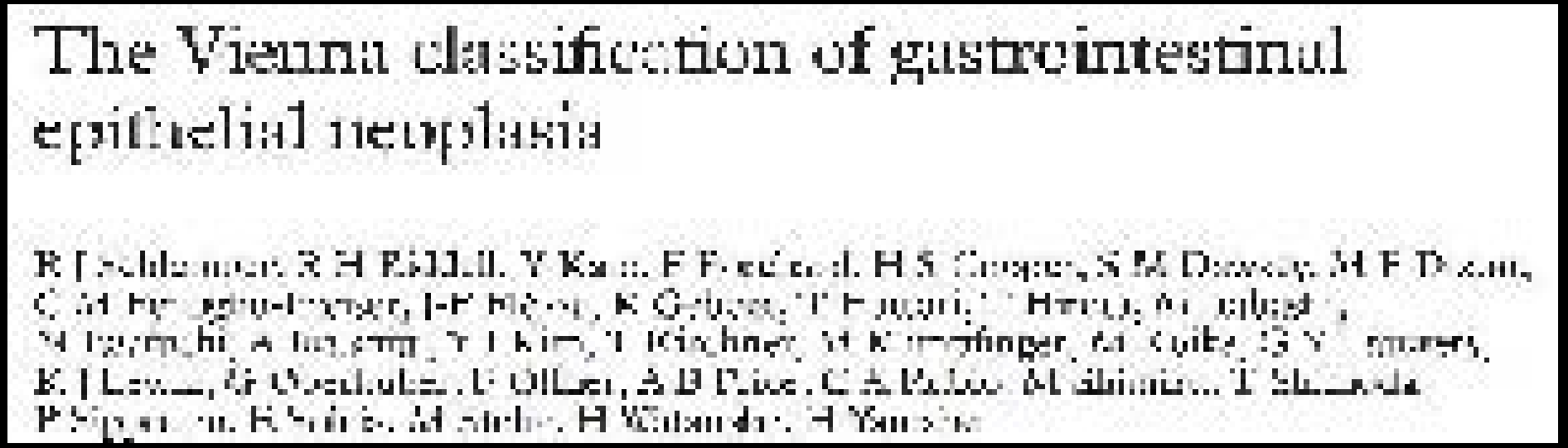

The Vienna classification of gastrointestinal epithelial neoplasia

Gut 2000;47:251–255

Table 1 Vienna classification of gastrointestinal epithelial neoplasia

Category 1	Negative for neoplasia/dysplasia
Category 2	Indefinite for neoplasia/dysplasia
Category 3	Non-invasive low grade neoplasia (low grade adenoma/dysplasia)
Category 4	Non-invasive high grade neoplasia
	4.1 High grade adenoma/dysplasia
	4.2 Non invasive carcinoma (carcinoma in situ)*
	4.3 Suspicion of invasive carcinoma
Category 5	Invasive neoplasia
	5.1 Intramucosal carcinoma†
	5.2 Submucosal carcinoma or beyond

*Non-invasive indicates absence of evident invasion.
†Intramucosal indicates invasion into the lamina propria or muscularis mucosae.

(J Gastroenterol Hepatol 2000; 15(suppl) G49-G57

Vienna classification of gastrointestinal epithelial neoplasia

(Gut 2000; 47: 251-255)

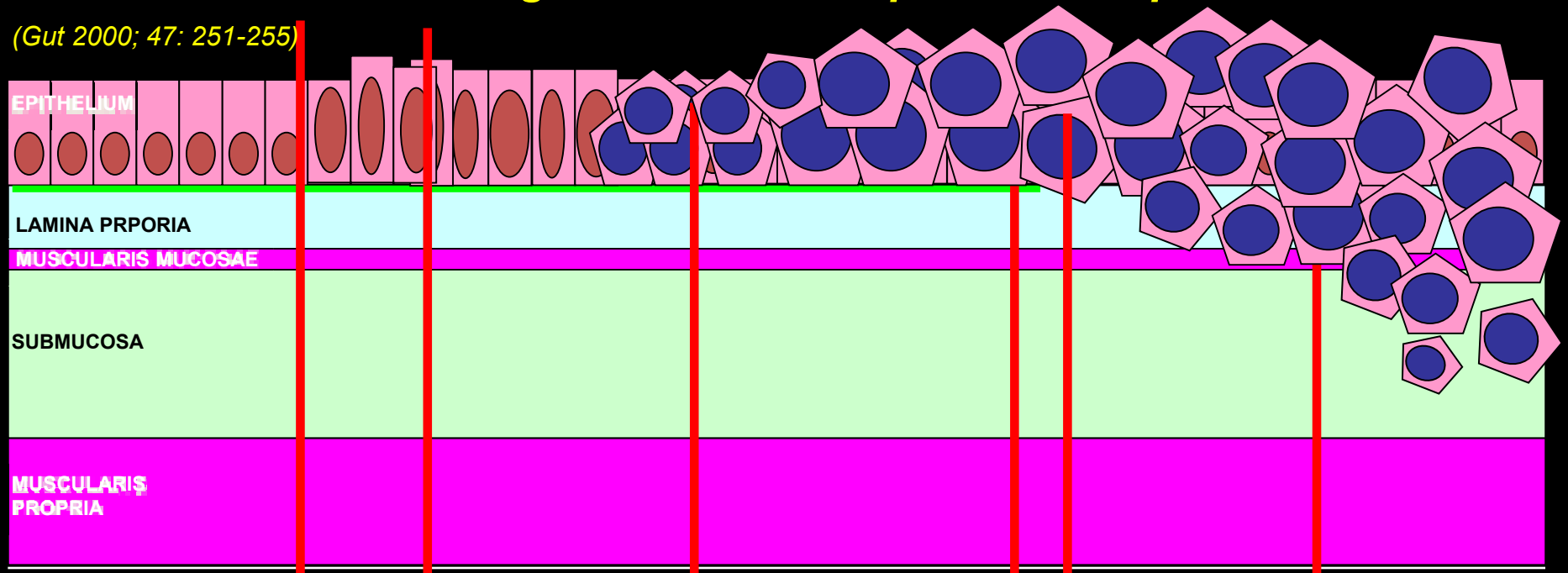

Cat	Diagnosis	
1	Negative	Nothing or F-UP
2	Indefinite	F-UP
3	Non invasive Low Grade Neoplasia	F-UP or local treatment
4	Non invasive High Grade Neoplasia	Local treatment endoscopic or surgical
	4.1 HG Adenoma / Dysplasia	
	4.2 Non Invasive Ca (Ca Is)	
	4.3 Suspicion of Invasive Ca	
5	Invasive Neoplasia	Surgical treatment
	5.1 Intramucosal Carcinoma	
	5.2 Submucosal Carcinoma or beyond	

Se il “Ca intramucoso” veniva spostato dalla categoria

“5. Invasive Neoplasia”

alla categoria

“4. Non invasive High Grade Neoplasia”

→ la concordanza tra patologi occidentali e giapponesi aumentava!

Si rendeva opportuna una modifica della classificazione di Vienna:

la “Vienna revised”

Vienna classification of gastrointestinal epithelial neoplasia

(Gut 2000; 47: 251-255)

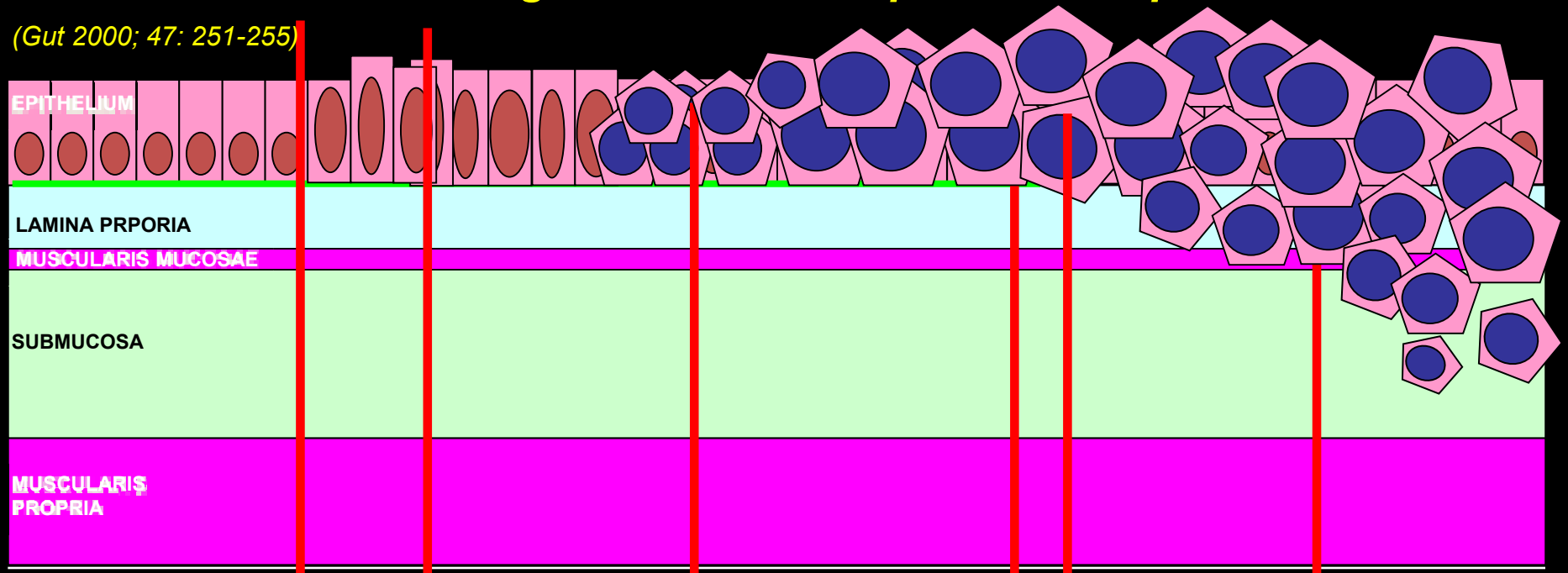

Cat	Diagnosis
1	Negative
2	Indefinite
3	Non invasive Low Grade Neoplasia
4	Non invasive High Grade Neoplasia
	4.1 HG Adenoma / Dysplasia
	4.2 Non Invasive Ca (Ca Is)
	4.3 Suspicion of Invasive Ca
5	Invasive Neoplasia
	5.1 Intramucosal Carcinoma
	5.2 Submucosal Carcinoma or beyond

Vienna classification of gastrointestinal epithelial neoplasia revised

(J Gastroenterol Hepatol 2000; 15(suppl) G49-G57)

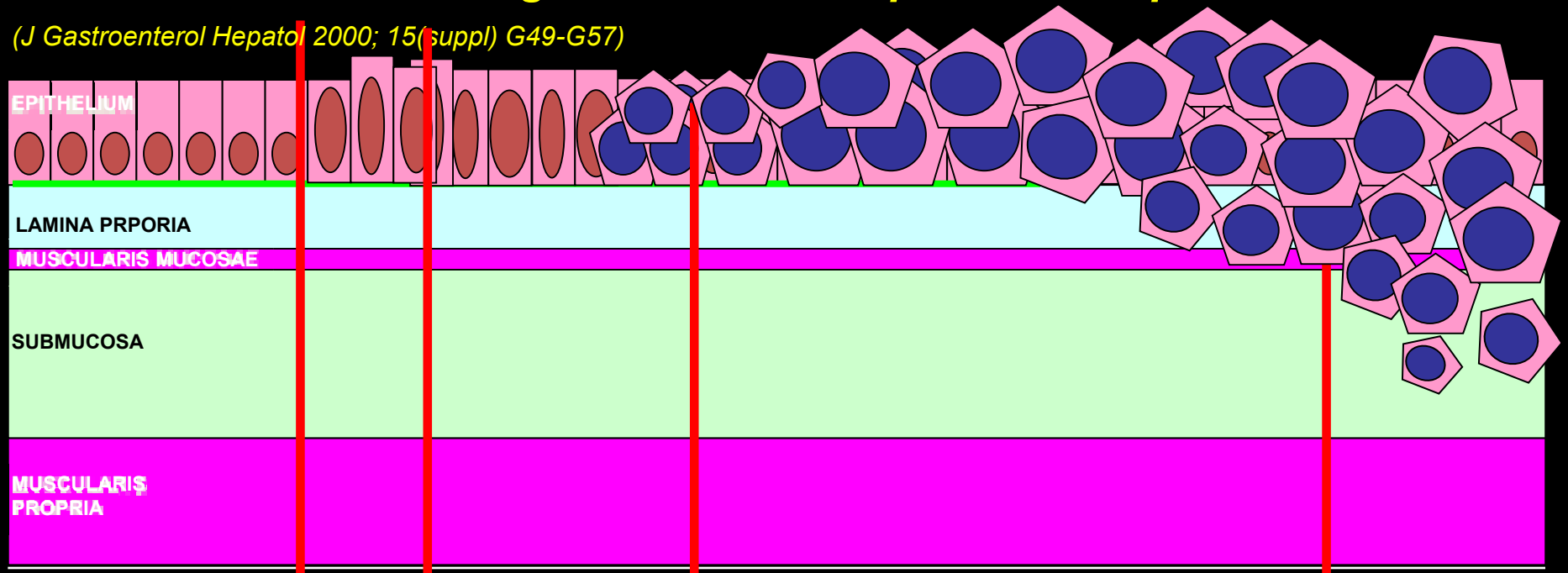

Cat	Diagnosis	
1	Negative	
2	Indefinite	
3	Non invasive Low Grade Neoplasia	
4	Mucosal High Grade Neoplasia	4.1 HG Adenoma / Dysplasia
		4.2 Non Invasive Ca (Ca Is)
		4.3 Suspicion of Invasive Ca
		4.4 Intramucosal Carcinoma
5	Submucosal invasion of Neoplasia	(Ca invading the submucosa or beyond)

Vienna classification of gastrointestinal epithelial neoplasia revised

(J Gastroenterol Hepatol 2000; 15(suppl) G49-G57)

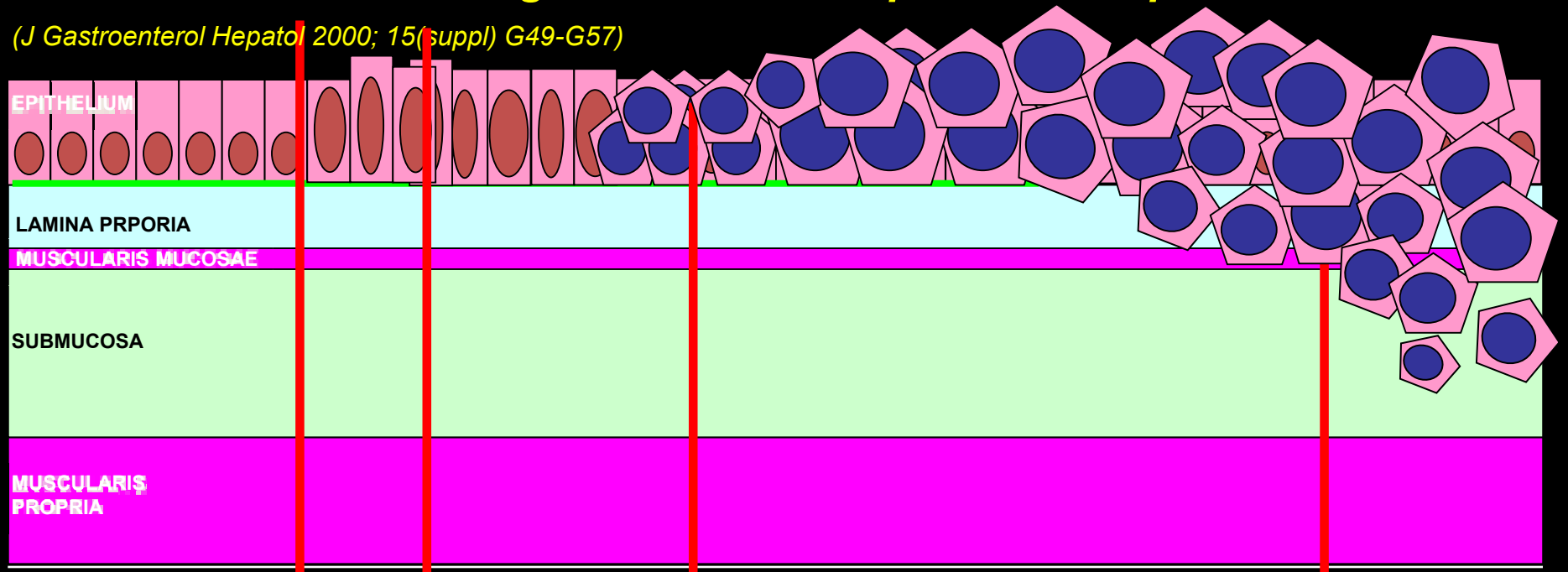

Cat	Diagnosis	
1	Negative	Nothing or F-UP
2	Indefinite	F-UP
3	Non invasive Low Grade Neoplasia	F-UP or local treatment
4	Mucosal High Grade Neoplasia	4.1 HG Adenoma / Dysplasia 4.2 Non Invasive Ca (Ca Is) 4.3 Suspicion of Invasive Ca 4.4 Intramucosal Carcinoma → Endoscopic or surgical resection
5	Submucosal invasion of Neoplasia	(Ca invading the submucosa or beyond) → Surgical treatment

Vienna classification of gastrointestinal epithelial neoplasia revised

(J Gastroenterol Hepatol 2000; 15(suppl) G49-G57)



Dopo la Vienna, per lo stomaco fila tutto diritto, senza grossi problemi; per il grosso intestino l'evoluzione della semantica è un po' più complicata...

τάξις



2000

Large intestine epithelial neoplasms

νόμος

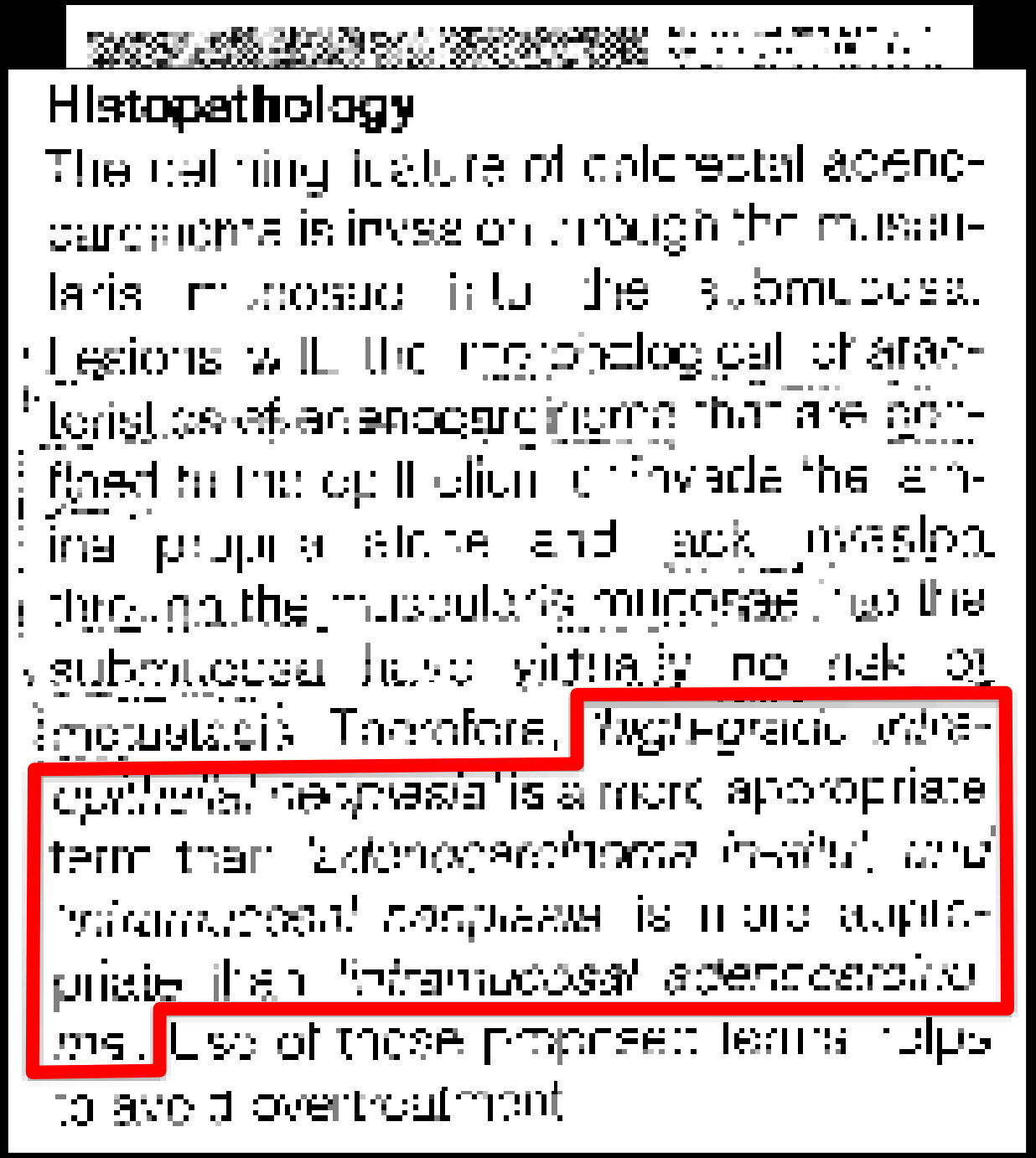

Histopathology

The defining feature of colorectal adenocarcinoma is invasion through the muscularis mucosae into the submucosa. Lesions with the morphological characteristics of adenocarcinoma that are confined to the epithelium or invade the lamina propria alone and lack invasion through the muscularis mucosae into the submucosa have virtually no risk of metastasis. Therefore, high-grade intraepithelial neoplasia is a more appropriate term than 'adenocarcinoma in situ', and 'intramucosal neoplasia' is more appropriate than 'intramucosal adenocarcinoma'. Use of these preferred terms helps to avoid overtreatment

2000

Large intestine epithelial neoplasms

Evolution…

Vienna system recommendation: change from “dysplasia” to “intraepithelial neoplasia”

- USA and EU: continue to use “dysplasia”
- JP: uses “intraepithelial neoplasia”

Confusion among pathologists and clinicians!!!

τάξις



2010

Large intestine epithelial neoplasms

WORLD HEALTH ORGANIZATION CLASSIFICATION OF TUMOURS

WHO Classification of Tumours of the Digestive System

International Agency for Research on Cancer

Lyon, 2010

νόμος

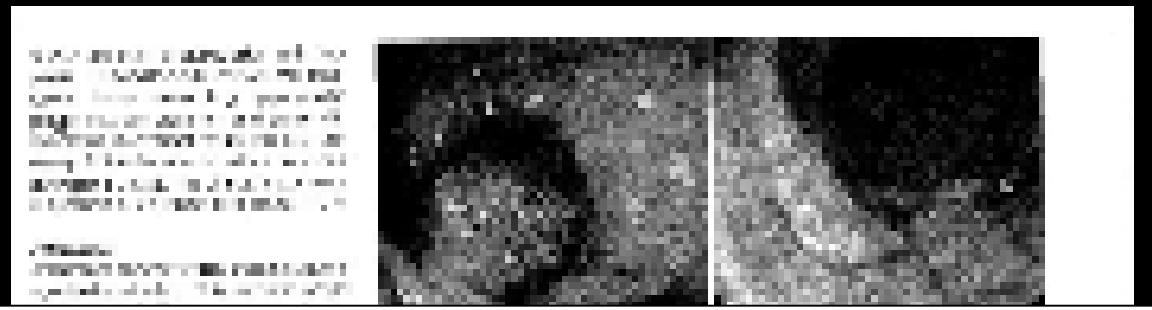

nuclear morphology. Foci in invasive growth can be encountered in an adenoma with high-grade dysplasia. For such lesions, the terms high-grade dysplasia as well as intramucosal carcinomas are used. Paneth



Large intestine epithelial neoplasms

Large intestine epithelial neoplasms: synopsis of terms

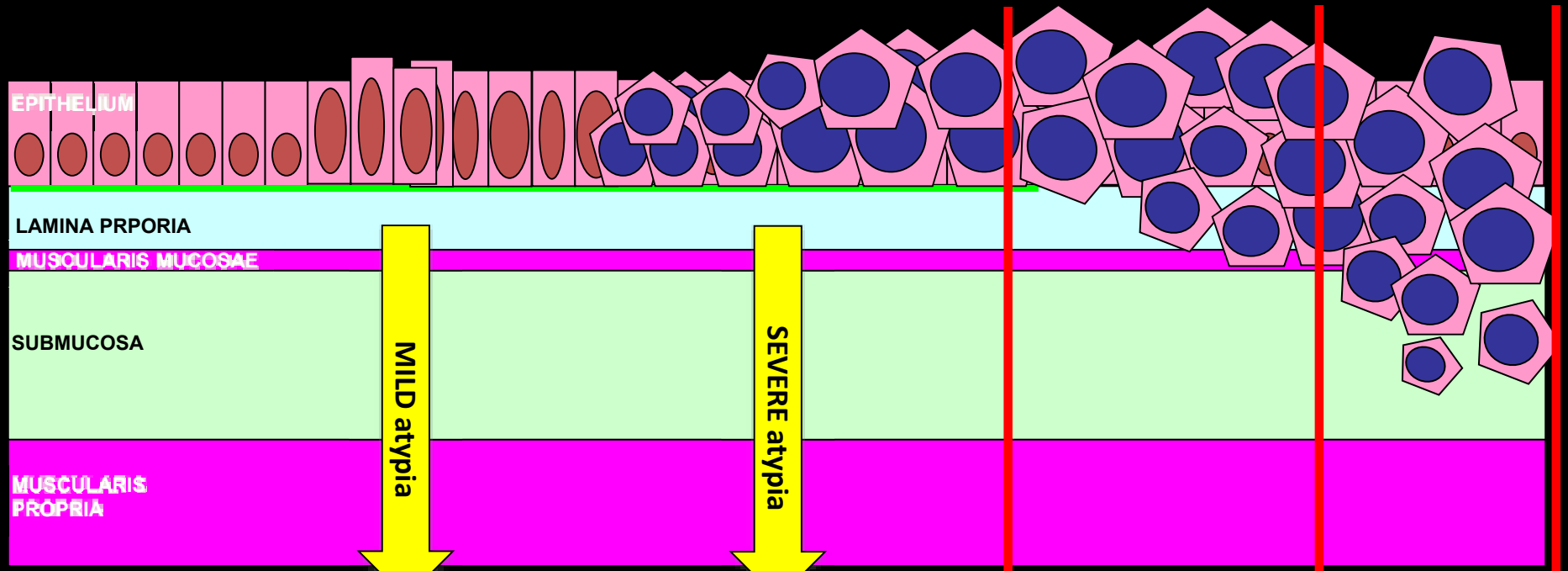

	Within BM	Within BM	LP or MM	Beyond MM
WHO 1976	Dysplasia	Non invasive Ca or Ca in situ		Ca, infiltrating
WHO 1989	Dysplasia	Non invasive Ca or Ca in situ	(Intramucosal Ca)	Ca, infiltrating
WHO 2000	Intraepithelial neoplasia (dysplasia)	HG intraepithelial neoplasia (in situ ADK)	Intramucosal neoplasia (intramucosal ADK)	Ca, infiltrating
WHO 2010	Intraepithelial neoplasia or dysplasia	Intraepithelial neoplasia or dysplasia (no Ca in situ)	Intramucosal Ca o HG dysplasia	Ca, infiltrating

A.D. 2011



"... Colonic intramucosal carcinoma behaves like a benign adenoma and for this reason polyps harbouring "in situ" or "intramucosal" cancer (Categories 4.2 and 4.4, respectively) are not generally regarded as "malignant" polyps and classified as high grade dysplasia, high grade intraepithelial neoplasia or mucosal high grade neoplasia".

A.D. 2012

European guidelines for quality assurance in colorectal cancer screening and diagnosis. First Edition
Annotations of colorectal lesions

The WHO definition of adenocarcinoma in use when the EU Guidelines were developed excluded diagnosis of intramucosal carcinoma in the colon or rectum, in contrast to the accepted WHO definitions for the stomach, oesophagus and small bowel. In the latter cases, a decision on surgical vs. local therapy is made based on respective protocols. Comparable lesions in the colon and rectum are reported as high-grade mucosal neoplasia because a carcinoma in the colon is defined by infiltration of the submucosa according to the WHO classification.

Endoscopy 2012; 44: SE13 - SE30

A.D. 2013

College of American Pathologists
Protocol for the Examination of Specimens From Patients With Primary Carcinoma of the Colon and Rectum

Based on AJCC/UICC TNM, 7th edition
Protocol web posting date: October 2013

"T Category Considerations

pTis. For colorectal carcinomas, "carcinoma in situ" (pTis) as a staging term includes cancer cells confined within the glandular basement membrane (intraepithelial carcinoma, synonymous with high grade dysplasia) or invasive into the mucosal lamina propria, up to but not through the muscularis mucosae (intramucosal carcinoma). Tumor extension through the muscularis mucosae into the submucosa is classified as T1".

A.D. 2014

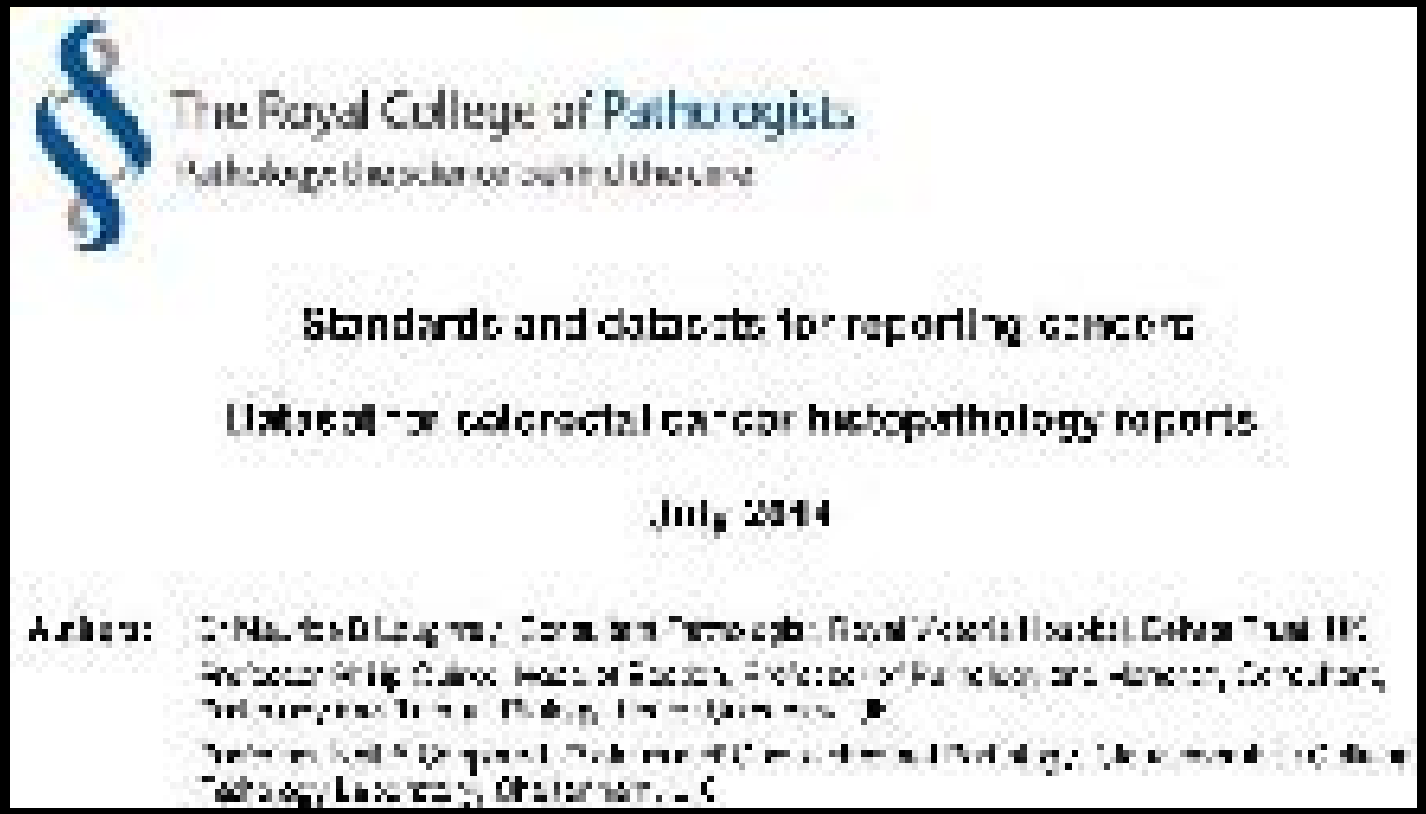

The Royal College of Pathologists

Standards and datasets for reporting cancers

Dataset for colorectal cancer histopathology reports

July 2014

malignancy. The diagnosis of colorectal cancer on biopsy, clearly depends on definition. In Japan and elsewhere in Asia it is largely a cytological diagnosis whilst in the US and some areas of Europe, architectural features are emphasised. In the UK we follow European and TNM guidance that requires definitive evidence of submucosal spread to make a diagnosis of colorectal cancer and does not allow the diagnosis of intramucosal adenocarcinoma.[1,2,3] The latter term, and plus are not encouraged in the lower gastrointestinal tract, to avoid overdiagnosis of lesions considered to have negligible risk of metastatic spread. The term 'high-grade dysplasia' should be used to describe these lesions.

Biop

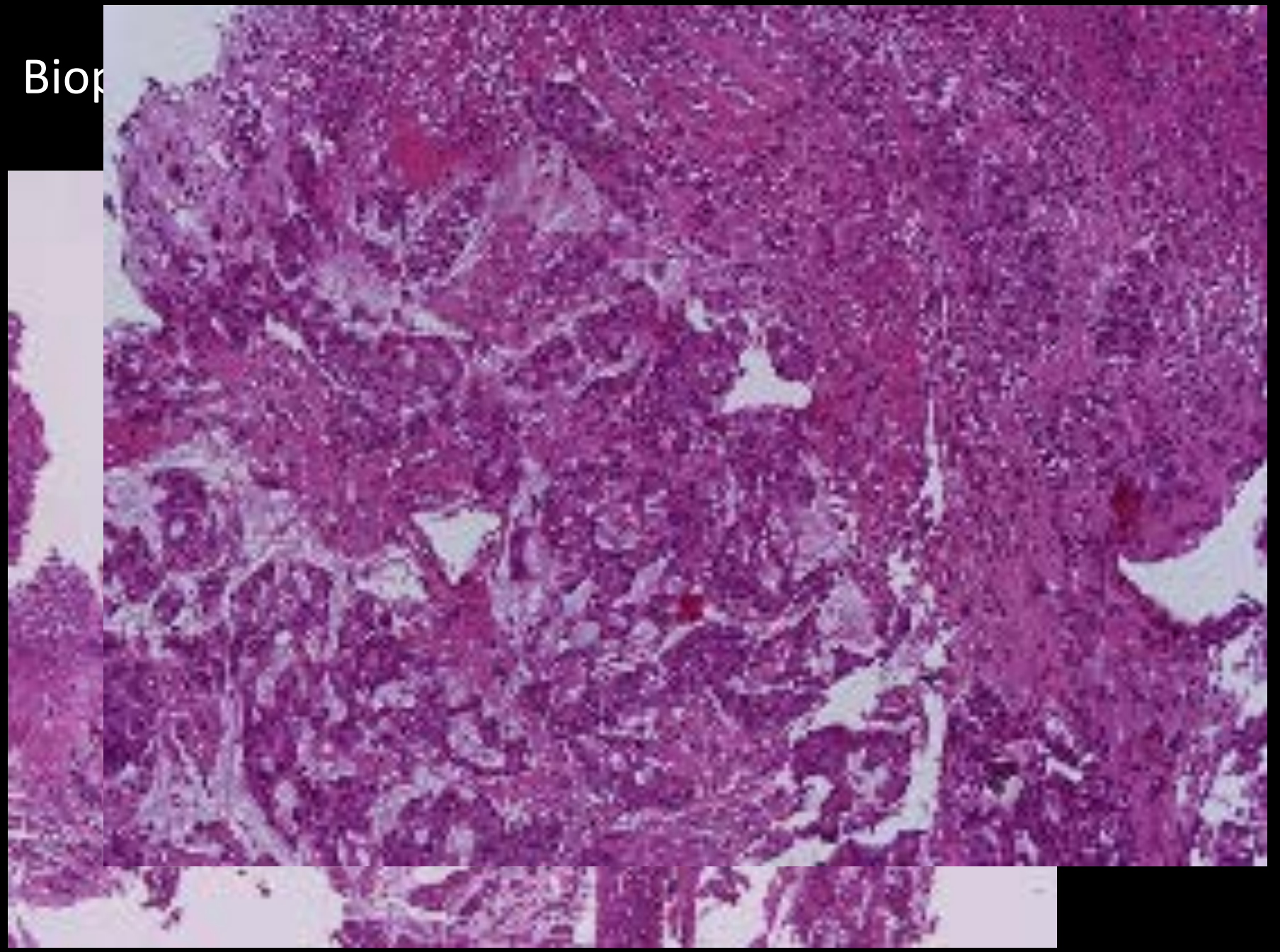

"… The requirement to demonstrate submucosal invasion undoubtedly creates diagnostic difficulties because biopsies may not show submucosal tissue. Biopsies from colorectal tumours therefore often fail to overtly demonstrate submucosal invasion. However, the presence of a desmoplastic stromal response to neoplastic glands is usually considered acceptable for a diagnosis of adenocarcinoma, as this is a rare finding in 'intramucosal adenocarcinoma'. Caution should be exercised with polyps or polypoid lesions, as a desmoplastic stroma might be encountered in these without submucosal invasion, related to surface ulceration and/or previous biopsy. "

RCPATH, Dataset on CRC histopathology report, 2014

"… Although not yet proven in definitive studies, we believe that juxtaposition of neoplastic glands to structures known to be in the submucosa, such as neural structures, fat and larger blood vessels, particularly arterioles and venules, are of considerable help in making a diagnosis of invasive adenocarcinoma. "

RCPATH, Dataset on CRC histopathology report, 2014

Nomina sunt consequentia rerum

(Giustiniano, Istitutiones, II, 7, 3)

COS'È QUELLA COSA TONDA, ROSSA E CON UN SEME DI CILIEGIA DENTRO?
CAREZ

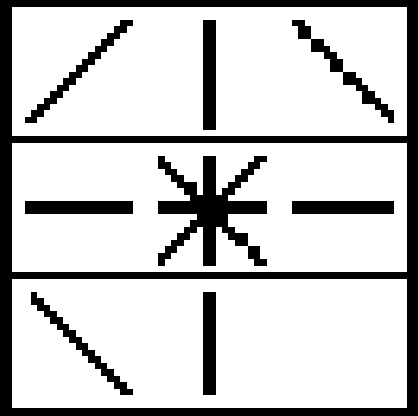

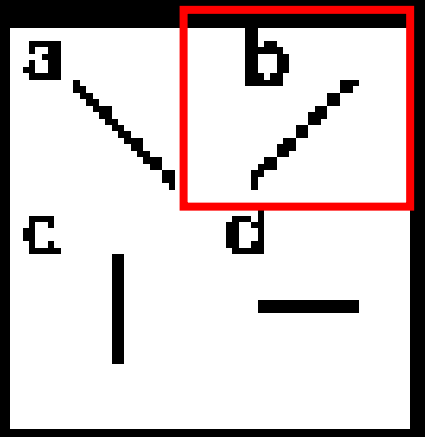
a
b
c
d

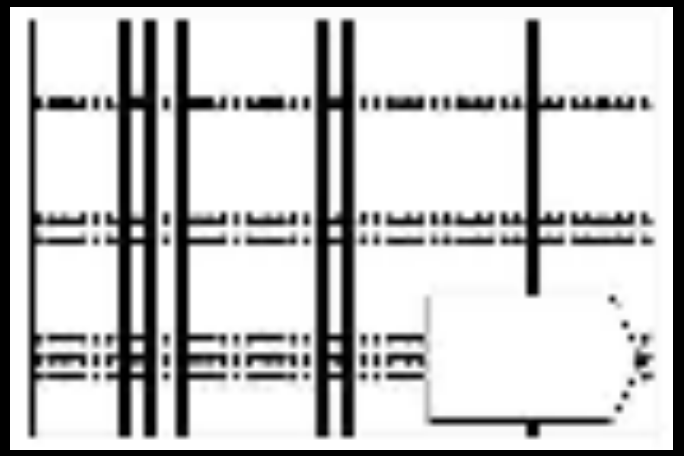



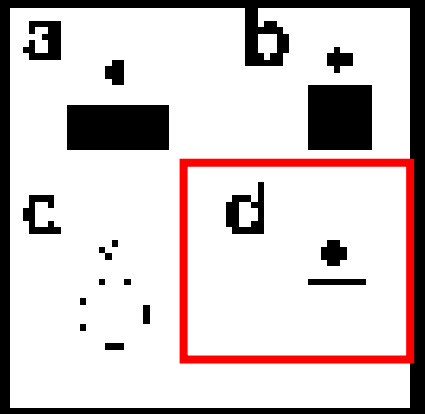
a
b
c
d

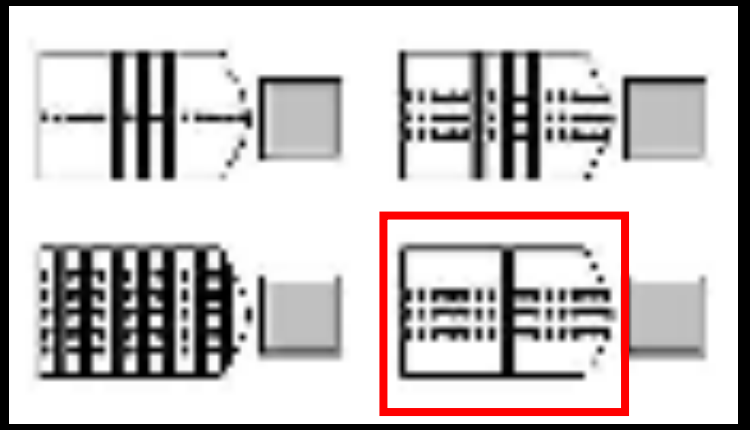



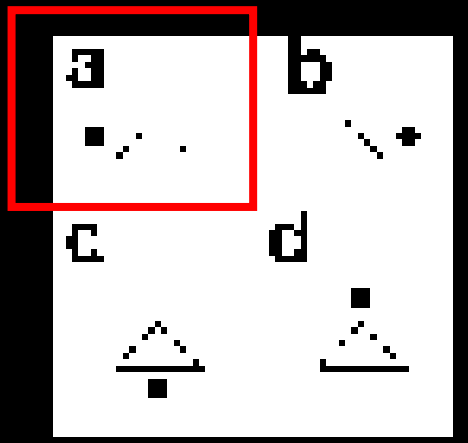
a
b
c
d

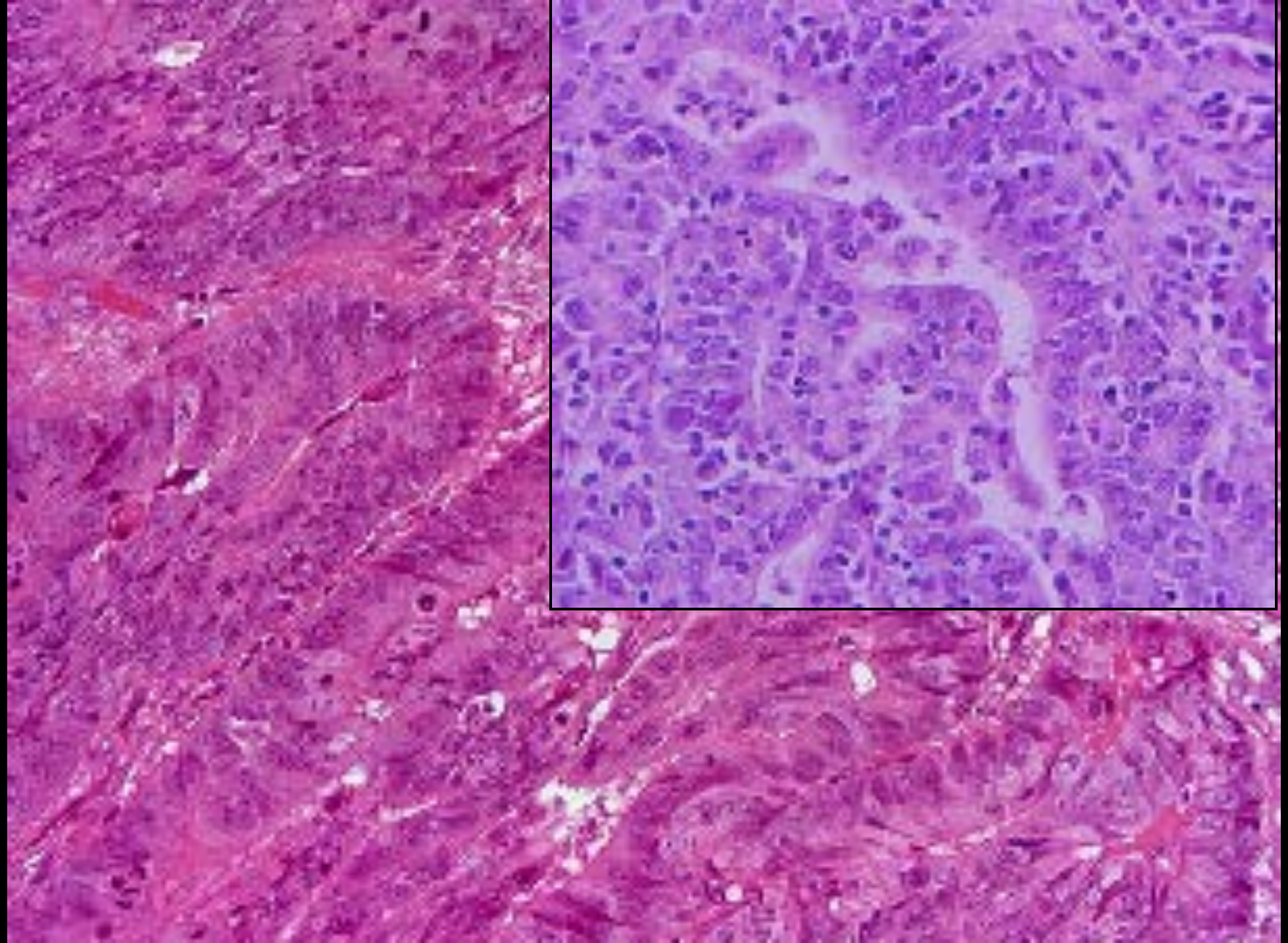

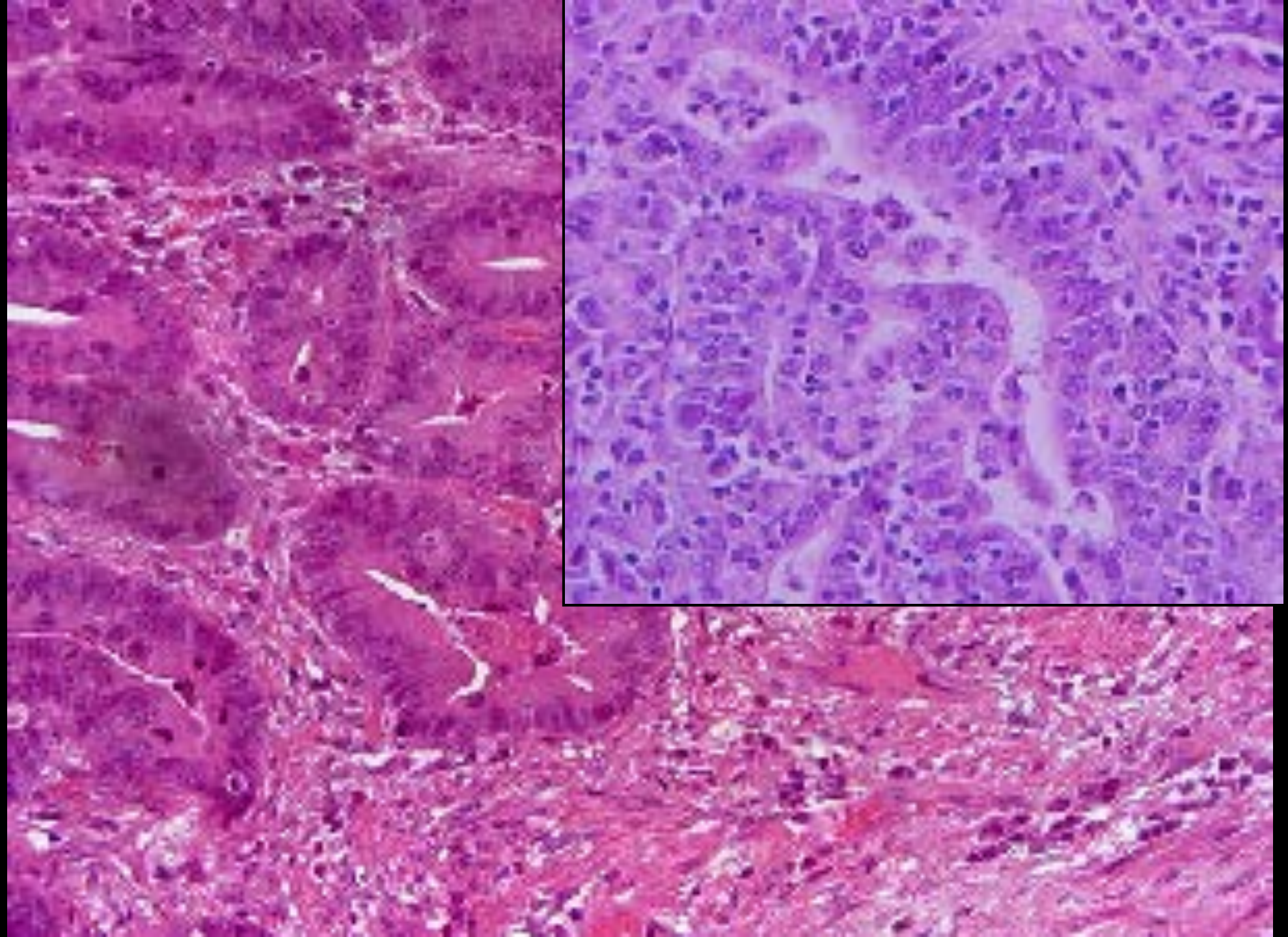

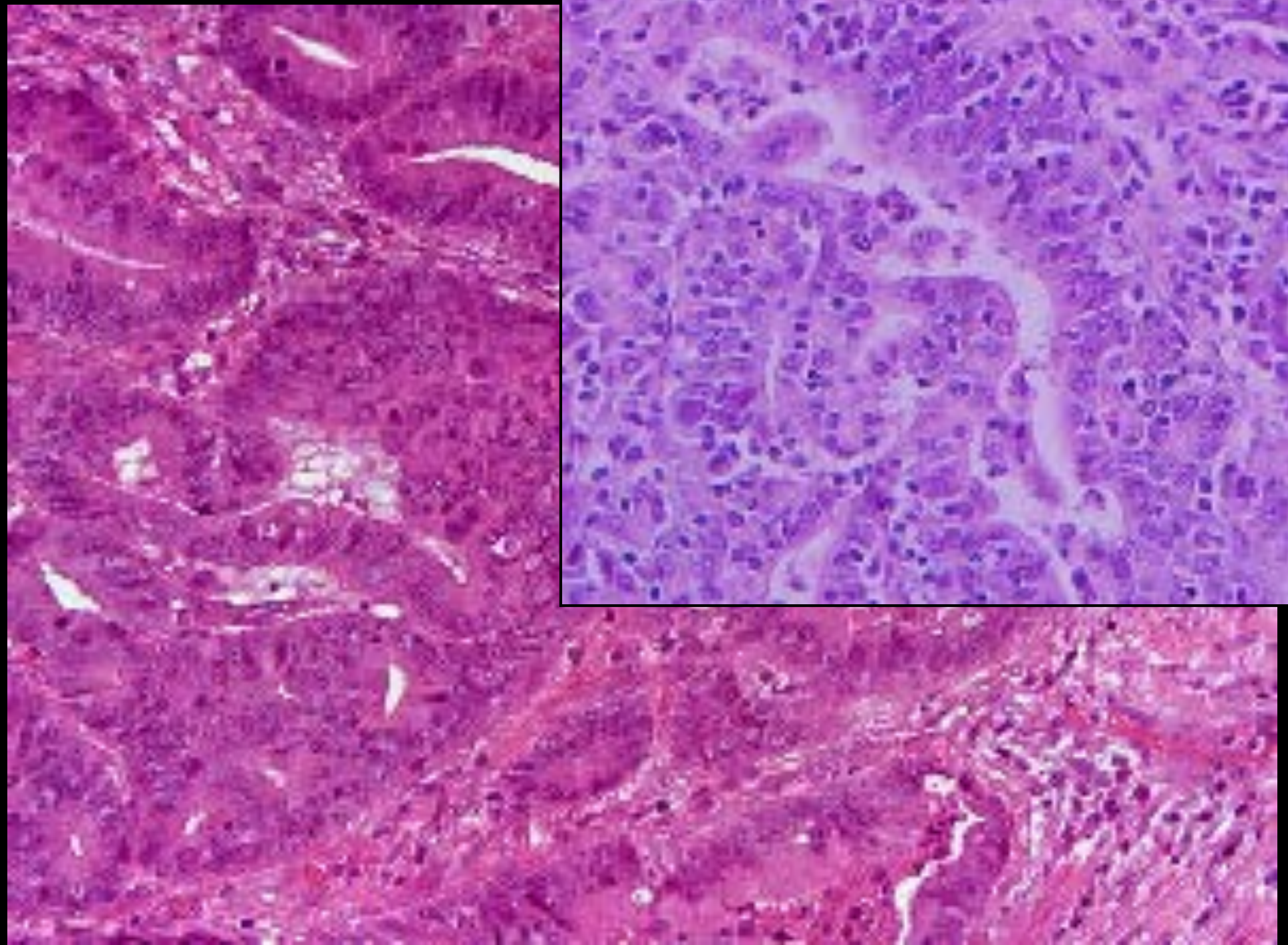

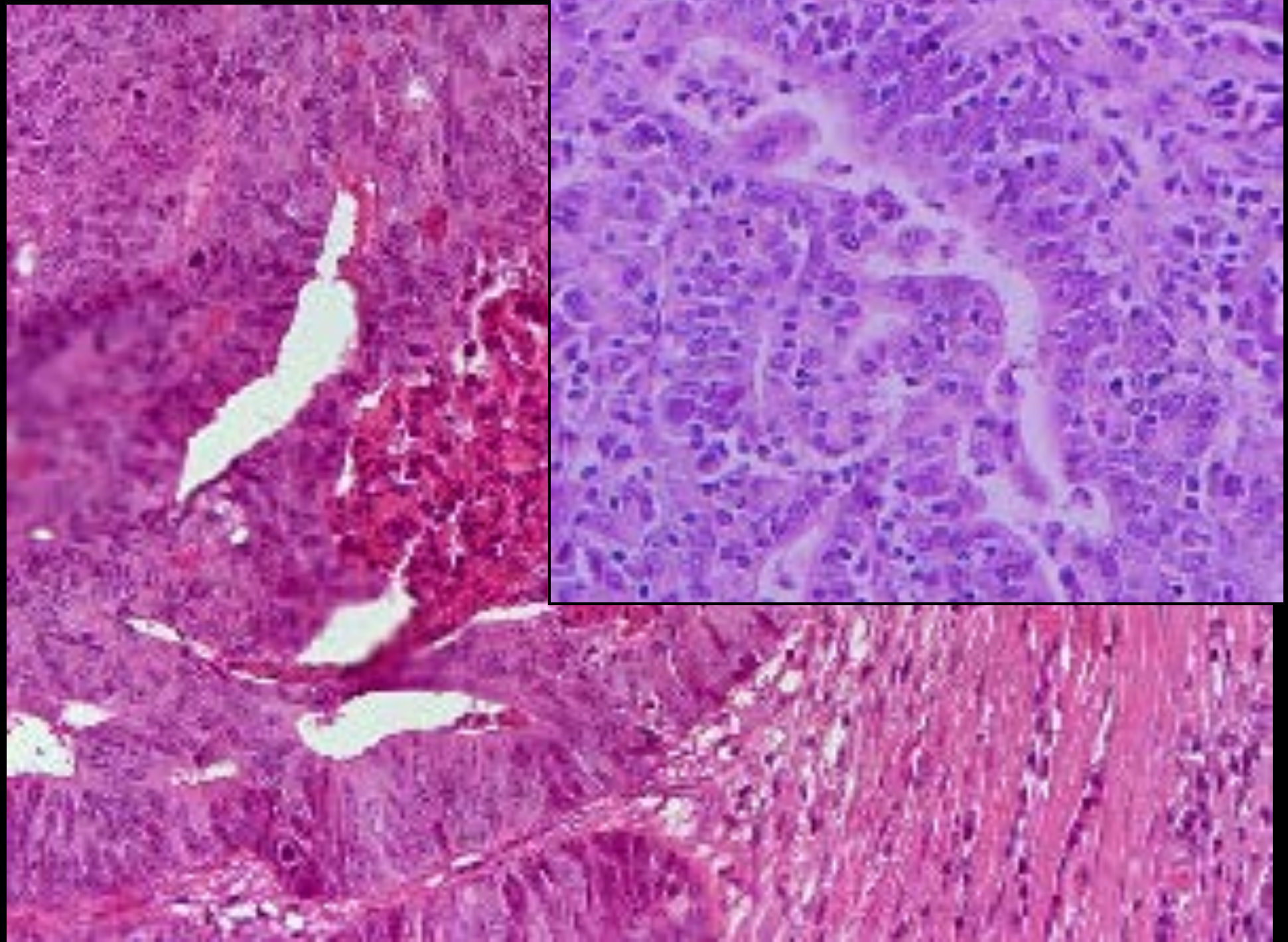

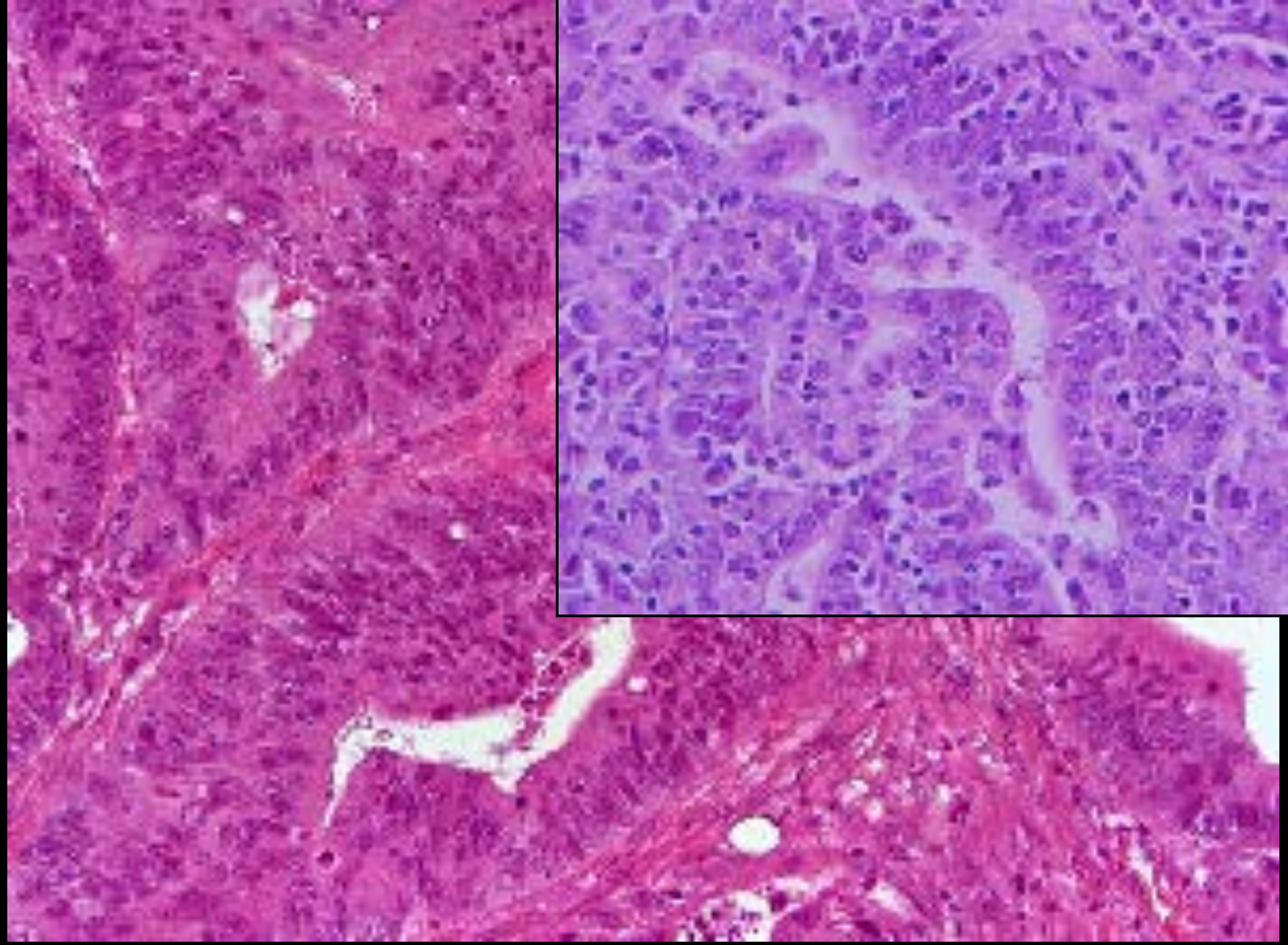

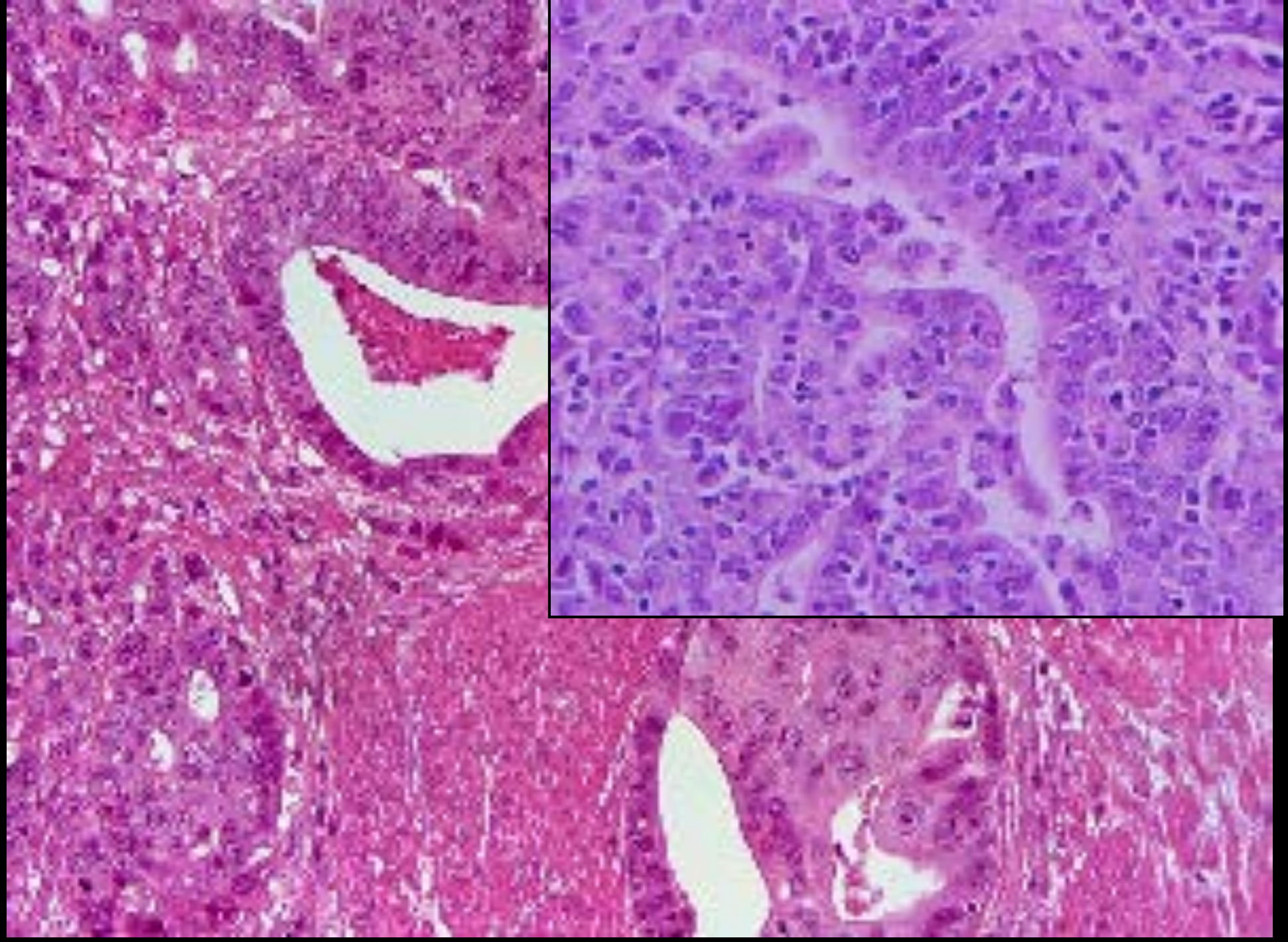

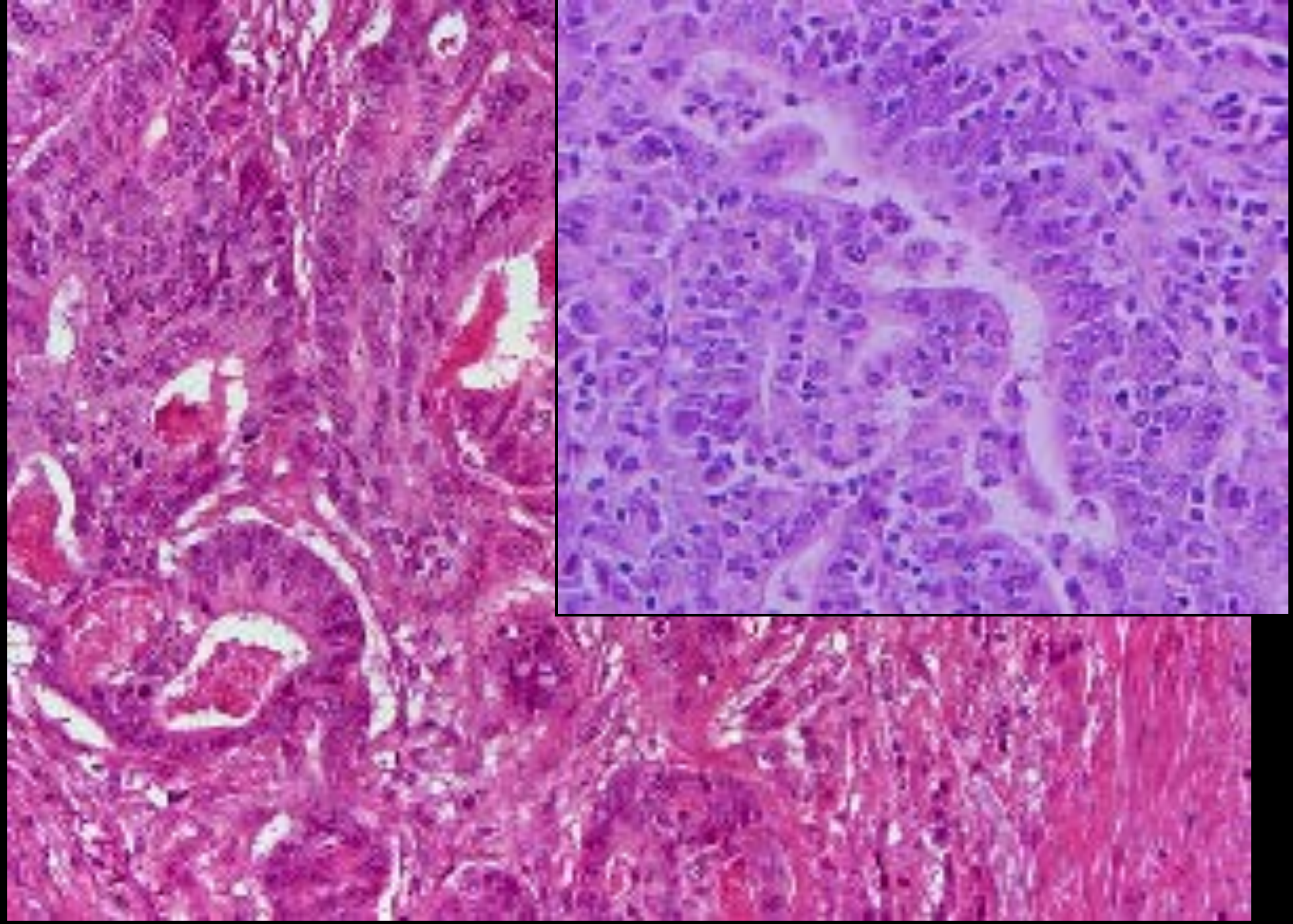

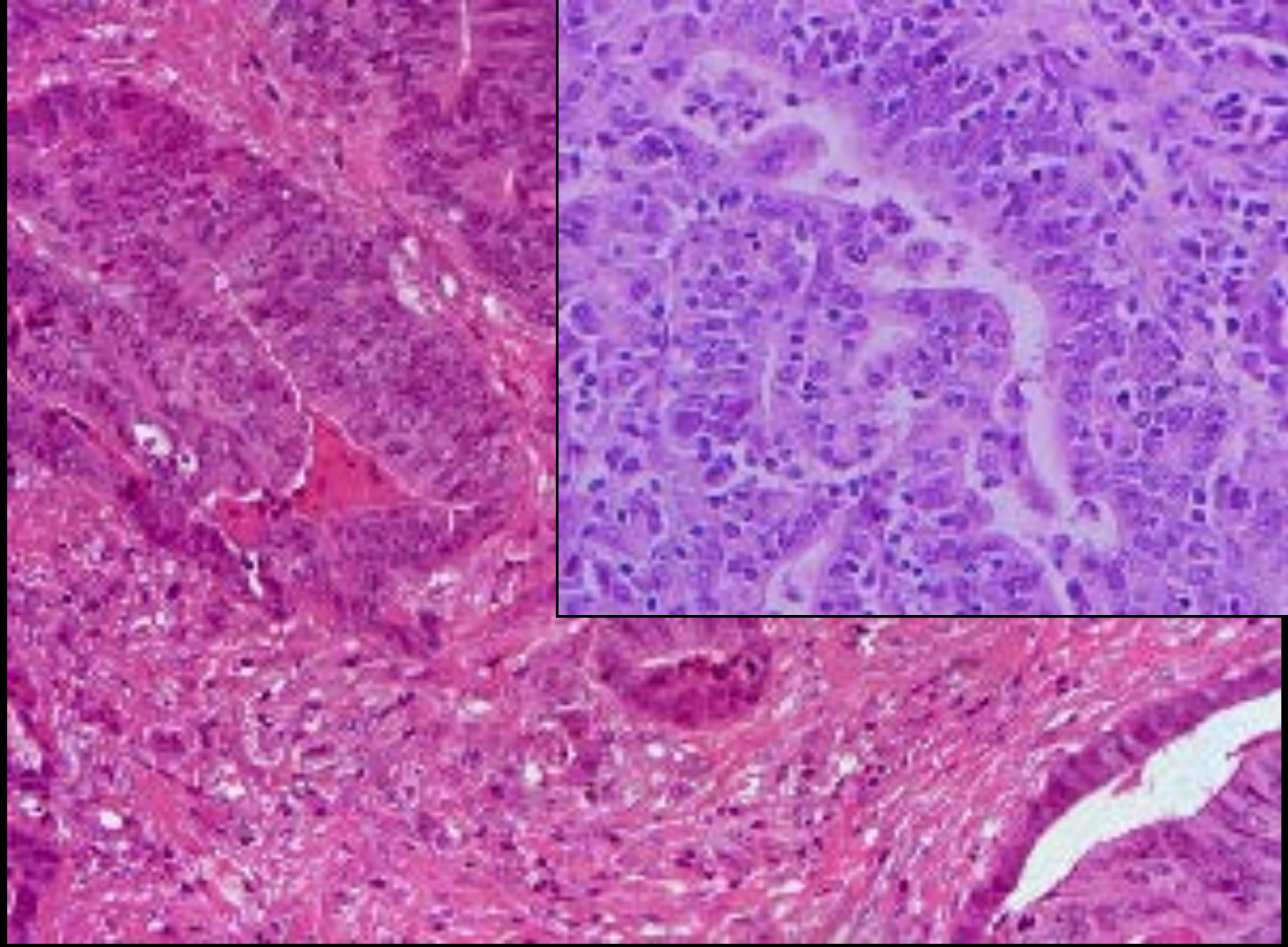

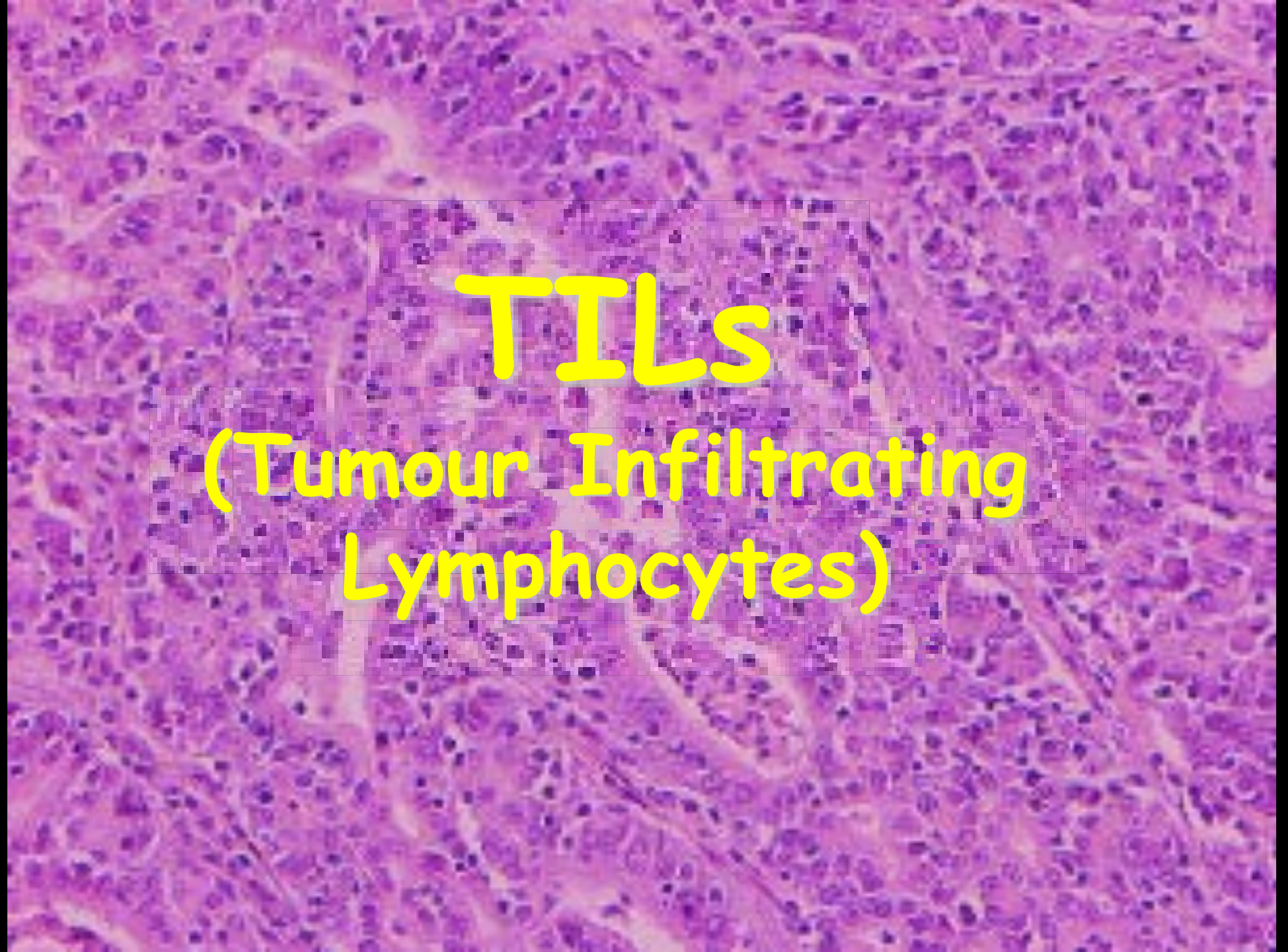
TILs
(Tumour Infiltrating
Lymphocytes)

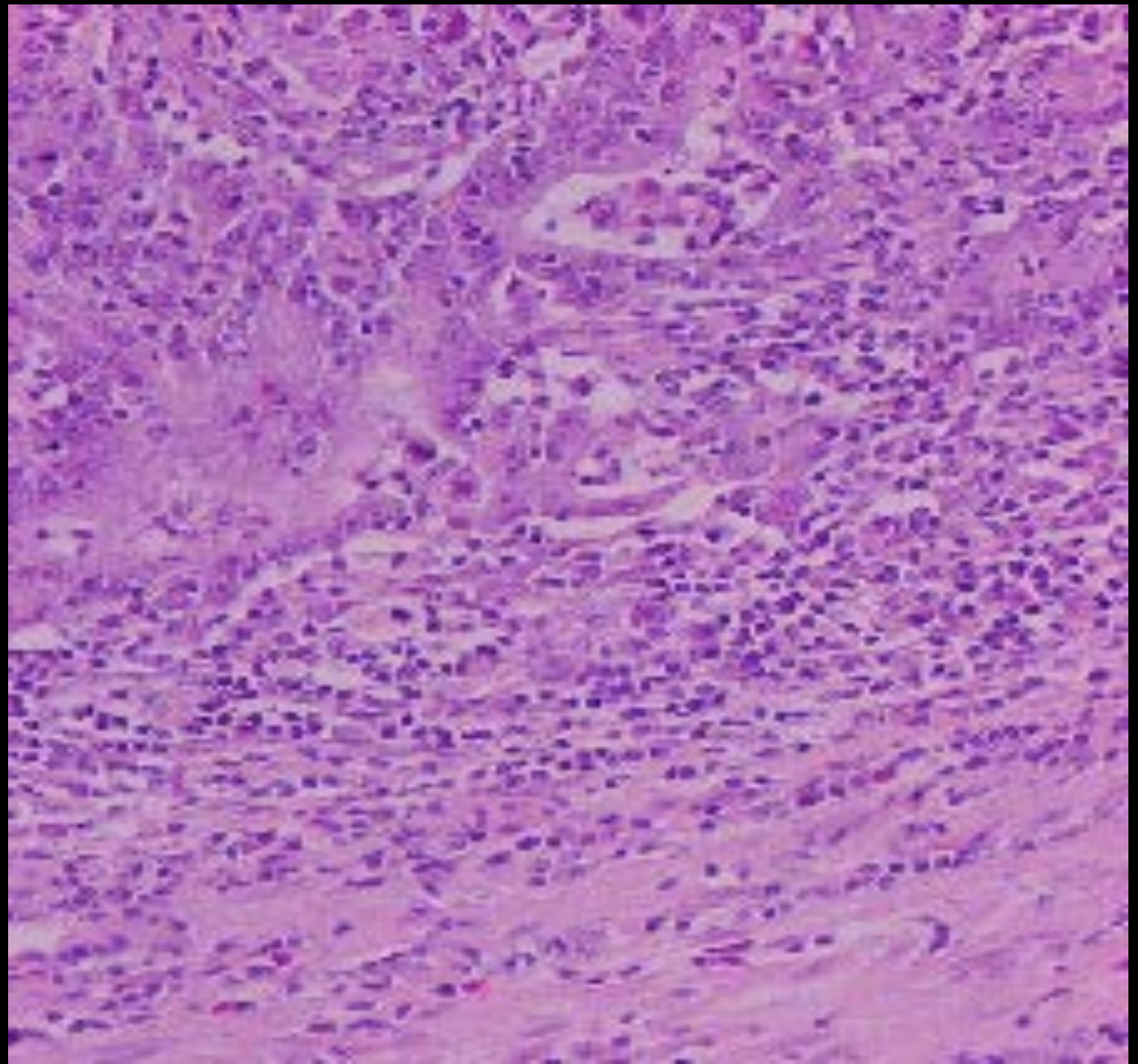

TILs

(Tumour Infiltrating Lymphocytes)

- It has been emphasized by Jass that the presence of tumor-infiltrating lymphocytes (TILs) identifies the majority of colorectal cancers with MSI-H phenotype

- Intraepithelial T-lymphocytes are more diagnostic of MSI-H phenotype than peritumoral and stromal infiltrates

- Alexander J, Watanabe T, Wu TT et al (2001) Histopathological identification of colon cancer with microsatellite instability. Am J Pathol 158:527–535

- Jass JR (2004) Role of the pathologist in the diagnosis of hereditary non-polyposis colorectal cancer. Dis Markers 20:215–224

Circle graph depicting the marked genotypic and phenotypic heterogeneity in hereditary colorectal cancer syndromes. Note those with an increased risk for small bowel cancer (Revised with permission from Lynch et al (2004) Cancer 100:53–64.)

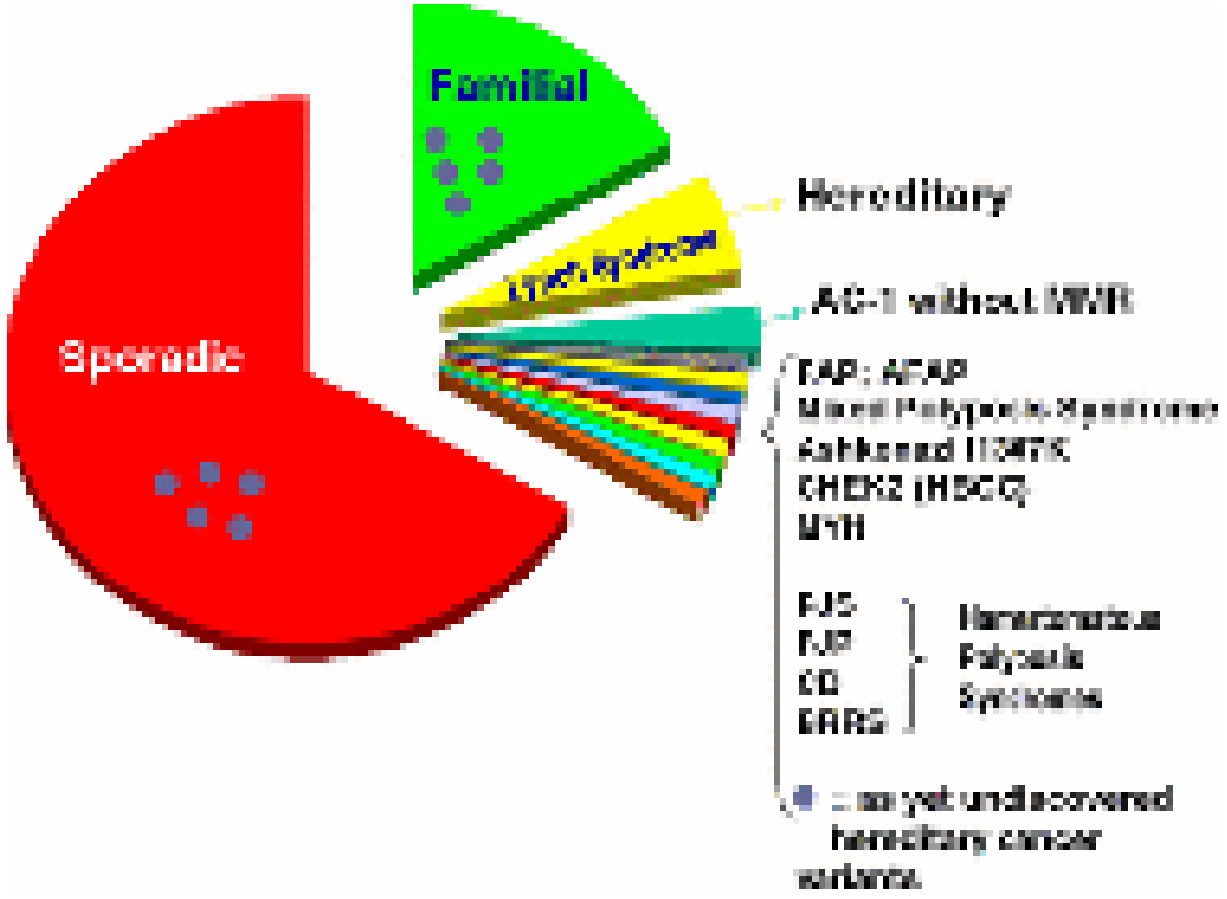

HNPCC (Lynch syndrome)
Cardinal Features

CRC in HNPCC

- **poorly differentiated,**
- **mucoid and signet-cell features,**
- **Crohn's-like reaction,**
- **excess of tumor infiltrating lymphocytes (TILs)**
- **MSI-H**

- Increased survival from CRC, when controlled for age and stage;

- Accelerated carcinogenesis and reduced interval CRC (adenoma-ca within 2–3 years, as opposed to 8–10 years in the general population)

- Sebaceous adenomas, sebaceous carcinomas, and multiple keratoacanthomas in the Muir–Torre syndrome variant of Lynch syndrome;

- The *sine qua non*, the identification of a germline MMR mutation segregating with syndrome-affected individuals in the family.

Pathology of the hereditary colorectal carcinoma

- Approximately 150,000 new patients with colorectal carcinomas (CRC) are diagnosed in the United States each year (8.5% of all new cancers [*1*].

- 30% of patients will have a positive familial history with first or second degree relative affected by cancer [*2*].

- Small proportion of such families have mutations in one of the currently identified susceptibility genes.

-Several autosomal dominant syndromes may have sufficiently characteristic pathologic presentation allowing their recognition even in the absence of relevant clinical information:

- **Lynch syndrome**
- **Familial Adenomatous Polyposis (FAP)**
- **Attenuated FAP**
- **Juvenile polyposis**
- **Cowden syndrome**
- **Peutz Jeghers syndrome**
- **Hereditary mixed polyposis syndrome (HMPS)**

- Hamilton SR et al (2000) Carcinoma of colon and rectum. In: Hamilton SR, Aaltonen LA (eds) Pathology and genetics tumours of the digestive system. WHO Classification of Tumours. IARC Press, Lyon, pp 105–119
- Burgart LJ (2005) Testing for defective mismatch repair in colorectal carcinoma. A practical guide. Arch Pathol Lab Med 129:1385–138

Lynch syndrome (HNPCC)

- The most common of the heritable colon cancer syndromes

- Autosomal dominant

- Germline mutations in mismatch repair (MMR) genes

- Lack of MMR proteins leads to genomic instability (high frequency microsatellite instability, MSI-H)

- Development of various cancers

- 3–5% of the total colon cancer in the United States

Gastroenterology 2001, 121:830–838

- Lynch syndrome (HNPCC): complex clinical presentation (syndrome), multiple colonic polyps + defining genetic abnormality (mutation in one of the MMR genes)

- “Familial colorectal cancer type-X” or “Familial CRC of undetermined type” should be used for familial occurrence of colorectal carcinoma in which no mutation in MMR genes or other genes known to predispose to CRC were found

Boland CR (2006) Decoding hereditary colorectal cancer. N Engl J Med 354:2815–2817
Jass JR (2006) Hereditary non-polyposis colorectal cancer: the rise and fall of a confusing term. World J Gastroenterol 12:4943–4950
Lindor NM, Rabe K, Petersen GM et al (2005) Lower cancer incidence in Amsterdam-I criteria families without mismatch repair deficiency: familial colorectal cancer type X. JAMA 293:1979–1985
Lynch HT, Boland CR et al (2006) Phenotypic and genotypic heterogeneity in the Lynch syndrome: diagnostic, surveillance and management implications. Eur J Hum Genet 14:390–402

Amsterdam Criteria I and II (International Collaborative Group) for the Diagnosis of HNPCC

Amsterdam Criteria I

1. Three or more relatives with histologically verified colorectal cancer, one of whom is a first-degree relative of the other two; FAP should be excluded
2. Colorectal cancer involving at least two generations
3. One or more colorectal cancer cases diagnosed before the age of 50

Amsterdam Criteria II

1. Three or more relatives with histologically verified HNPCC-associated cancer (colorectal cancer, cancer of the endometrium, small bowel, ureter, or renal pelvis), one of whom is a first-degree relative of the other two; FAP should be excluded
2. Colorectal cancer involving at least two generations
3. One or more cancer cases diagnosed before the age of 50

HNPCC, hereditary nonpolyposis colorectal cancer; FAP, familial adenomatous polyposis.

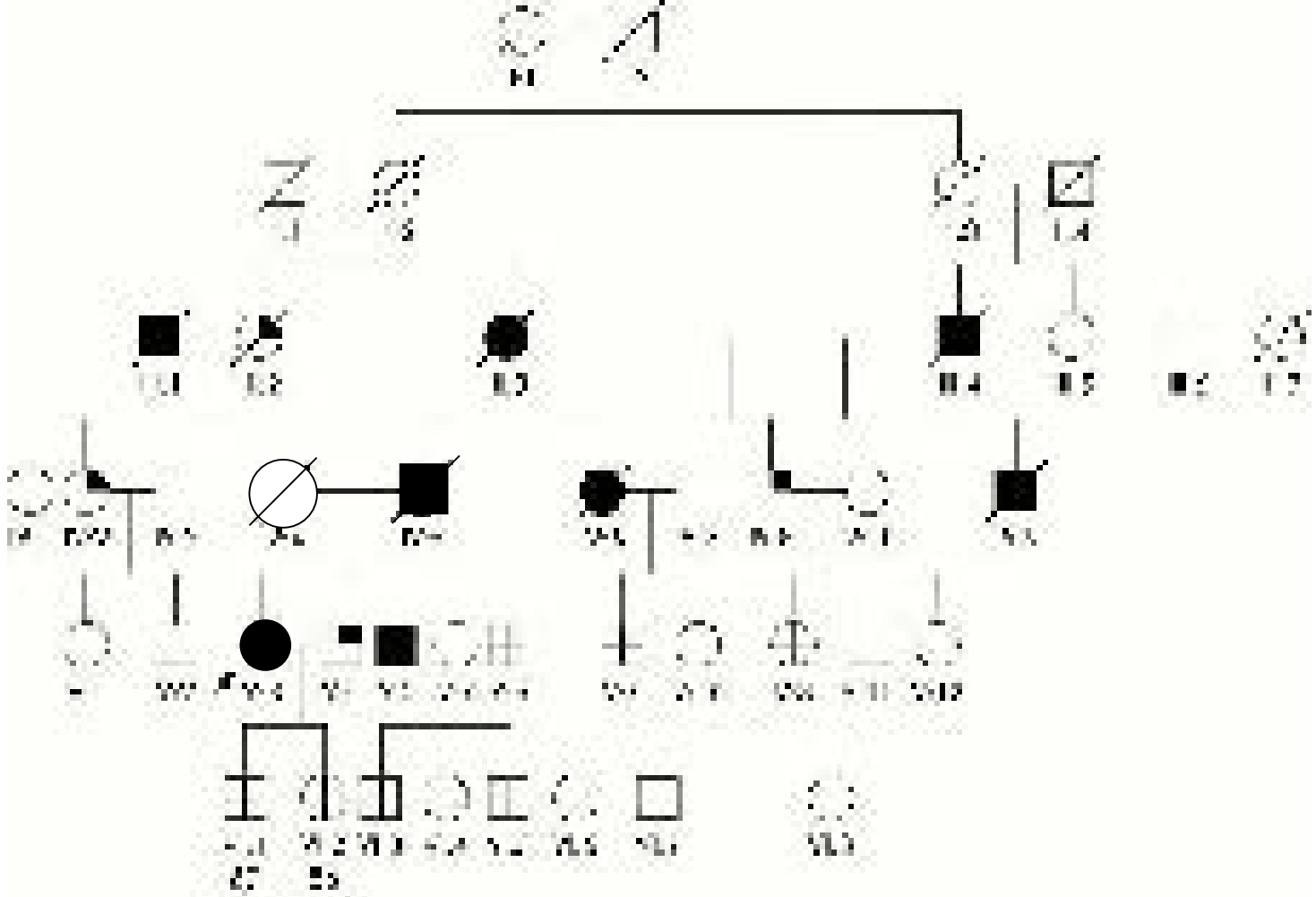

Amsterdam Criteria II

1. Three or more relatives with histologically verified HNPCC-associated cancer (colorectal cancer, cancer of the endometrium, small bowel, ureter, or renal pelvis), one of whom is a first-degree relative of the other two; FAP should be excluded

2. Colorectal cancer involving at least two generations

3. One or more cancer cases diagnosed before the age of 50

Bethesda Criteria for Testing Colorectal Tumors for MSI

1. Individuals with cancer in families that meet the Amsterdam criteria
2. Individuals with two HNPCC-related cancers, including synchronous and metachronous colorectal cancers or associated extracolonic cancers*
3. Individuals with colorectal cancer and a first-degree relative with colorectal cancer and/or HNPCC-related extracolonic cancer and/or a colorectal adenoma; one of the cancers diagnosed at age < 45 years,† and the adenoma diagnosed at age < 40 years
4. Individuals with colorectal cancer or endometrial cancer diagnosed at age < 45 years†
5. Individuals with right-sided colorectal cancer with an undifferentiated pattern (solid/cribriform) on histology diagnosed at age < 45 years†‡
6. Individuals with signet-ring cell-type colorectal cancer diagnosed at age < 45 years†§
7. Individuals with adenomas diagnosed at age < 40 years

Abbreviations: MSI, microsatellite instability; HNPCC, hereditary nonpolyposis colorectal cancer; AGA, American Gastroenterological Association.

- Endometrial, ovarian, gastric, hepatobiliary, small bowel, or transitional cell carcinoma of the renal pelvis or ureter.
- † Guidelines for age of cancer diagnosis have been adapted to <50 years in the AGA Medical Position Statement (Bethesda criteria modified).
- ‡ Solid/cribriform defined as poorly differentiated or undifferentiated carcinoma composed of irregular, solid sheets of large eosinophilic cells and containing small gland-like spaces.
- § Composed of >50% signet ring cells.

Revised Bethesda guidelines for MSI testing

Who should be tested for MSI:
1. Colorectal cancer diagnosed in a patient who is less than 50 yr of age
2. Presence of synchronous, metachronous colorectal, or other Lynch syndrome-associated tumors (colorectal, endometrial, stomach, ovarian, pancreas, ureter and renal pelvis, biliary tract, small bowel, brain, and sebaceous gland adenomas and keratoacanthomas), regardless of age
3. Colorectal cancer with the MSI-H histology (presence of tumor infiltrating lymphocytes, Crohn's-like lymphocytic reaction, mucinous/signet-ring differentiation, or medullary growth pattern) diagnosed in a patient who is less than 60 yr of age
4. Colorectal cancer diagnosed in one or more first-degree relatives with an HNPCC-related tumor, with one of the cancers being diagnosed under age 50 yr
5. Colorectal cancer diagnosed in two or more first- or second-degree relatives with HNPCC-related tumors, regardless of age

Umar A, Boland CR, Terdiman JP et al (2004) Revised Bethesda guidelines for hereditary nonpolyposis colorectal cancer (Lynch syndrome) and microsatellite instability. J Natl Cancer Inst 96:261–268

Clinicopathological characteristics

Patients with Lynch syndrome usually present with:

- adenocarcinoma of the proximal colon
- with or without synchronous or metachronous CRC or other malignancy typical of the syndrome (e.g. skin, stomach, urinary tract, biliary tree or brain and in women endometrial and ovarian carcinomas)

The set of clinical and pathologic criteria for identification of patients with high probability of Lynch syndrome constitutes the revised Bethesda guidelines

In applying these criteria, practicing pathologists need to recognize the occurrence of CRC in a patient with the history of other tumors characteristic of Lynch syndrome and to recognize characteristic morphology of MSI-H adenocarcinomas

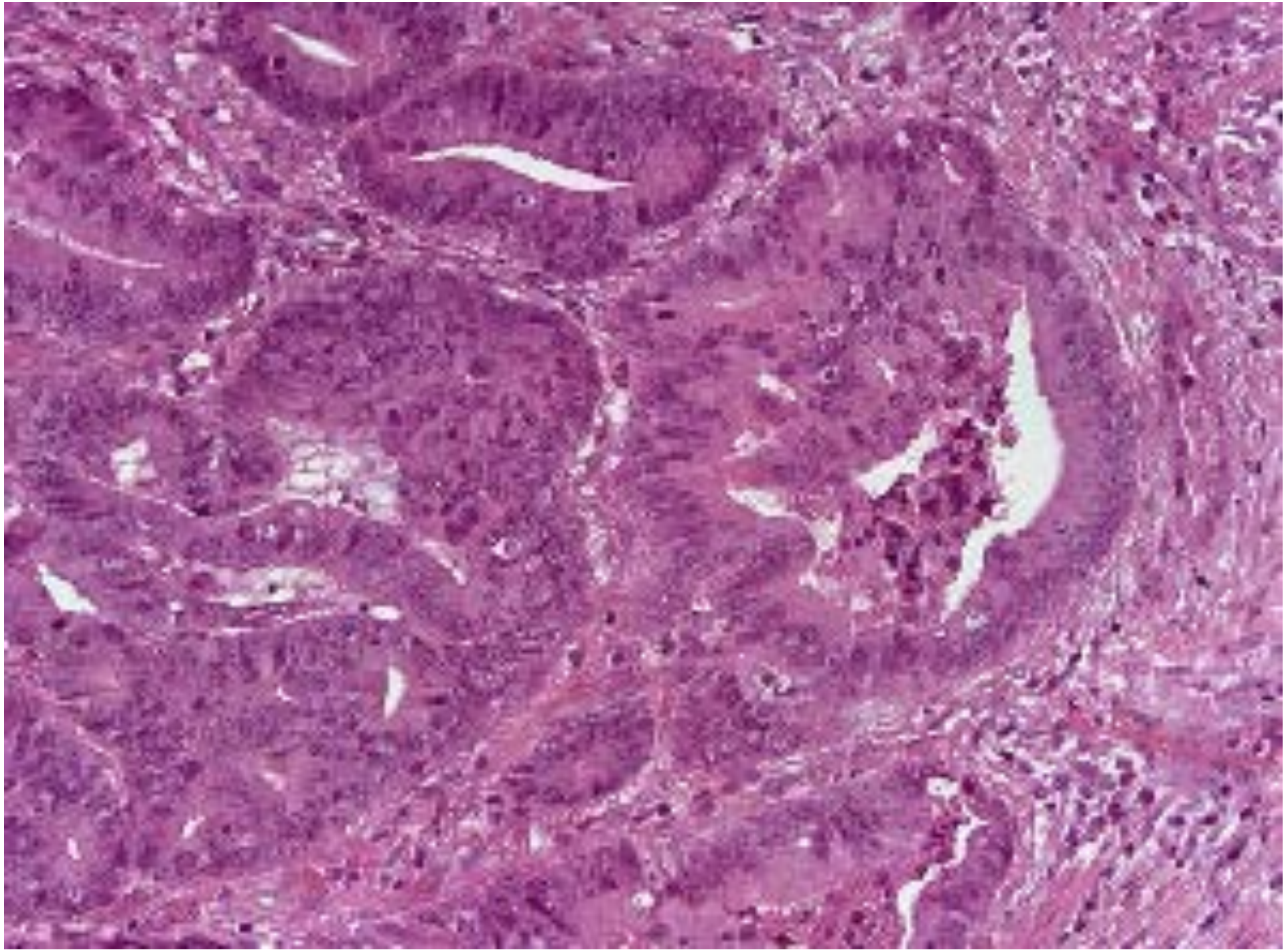

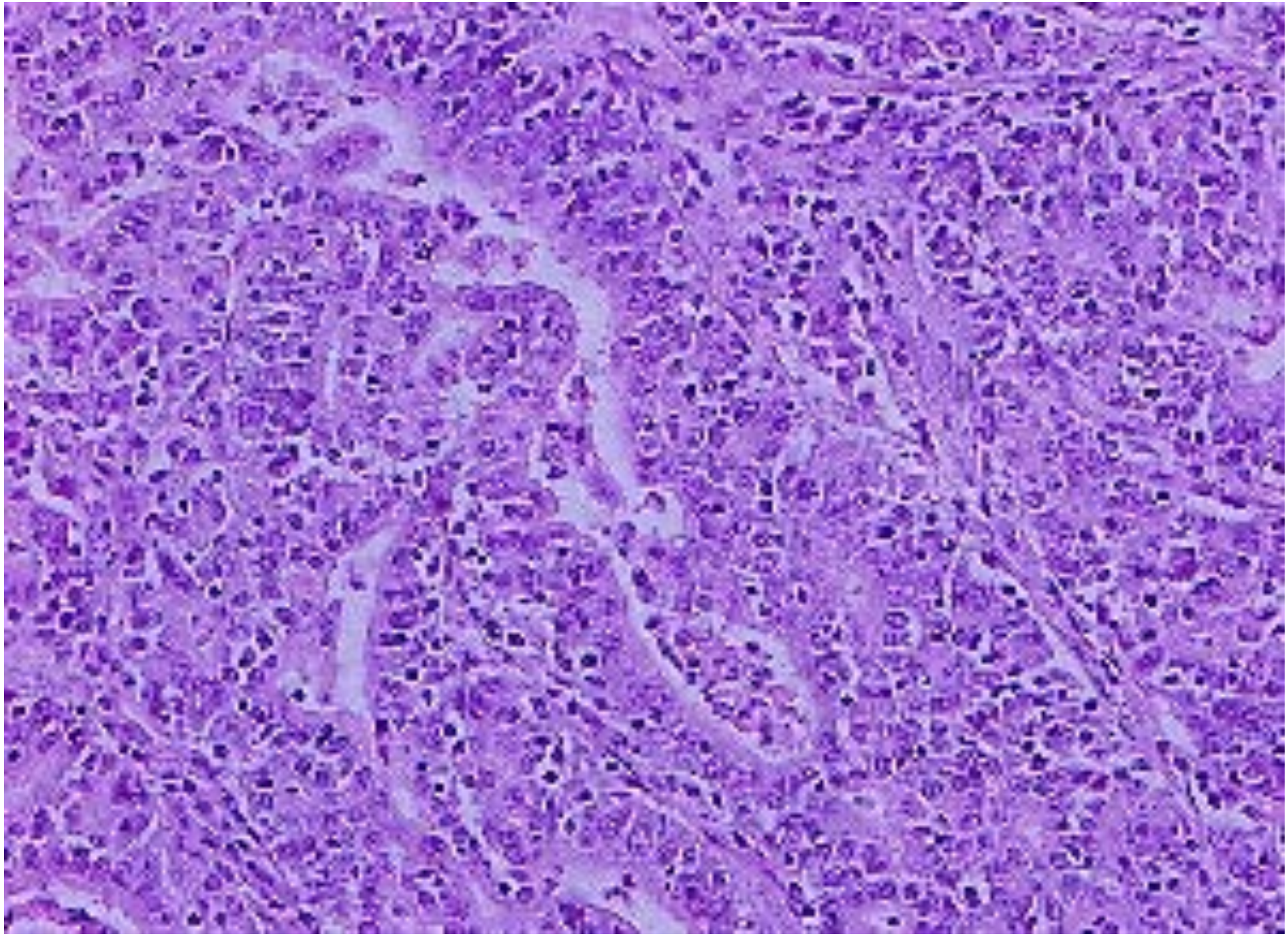

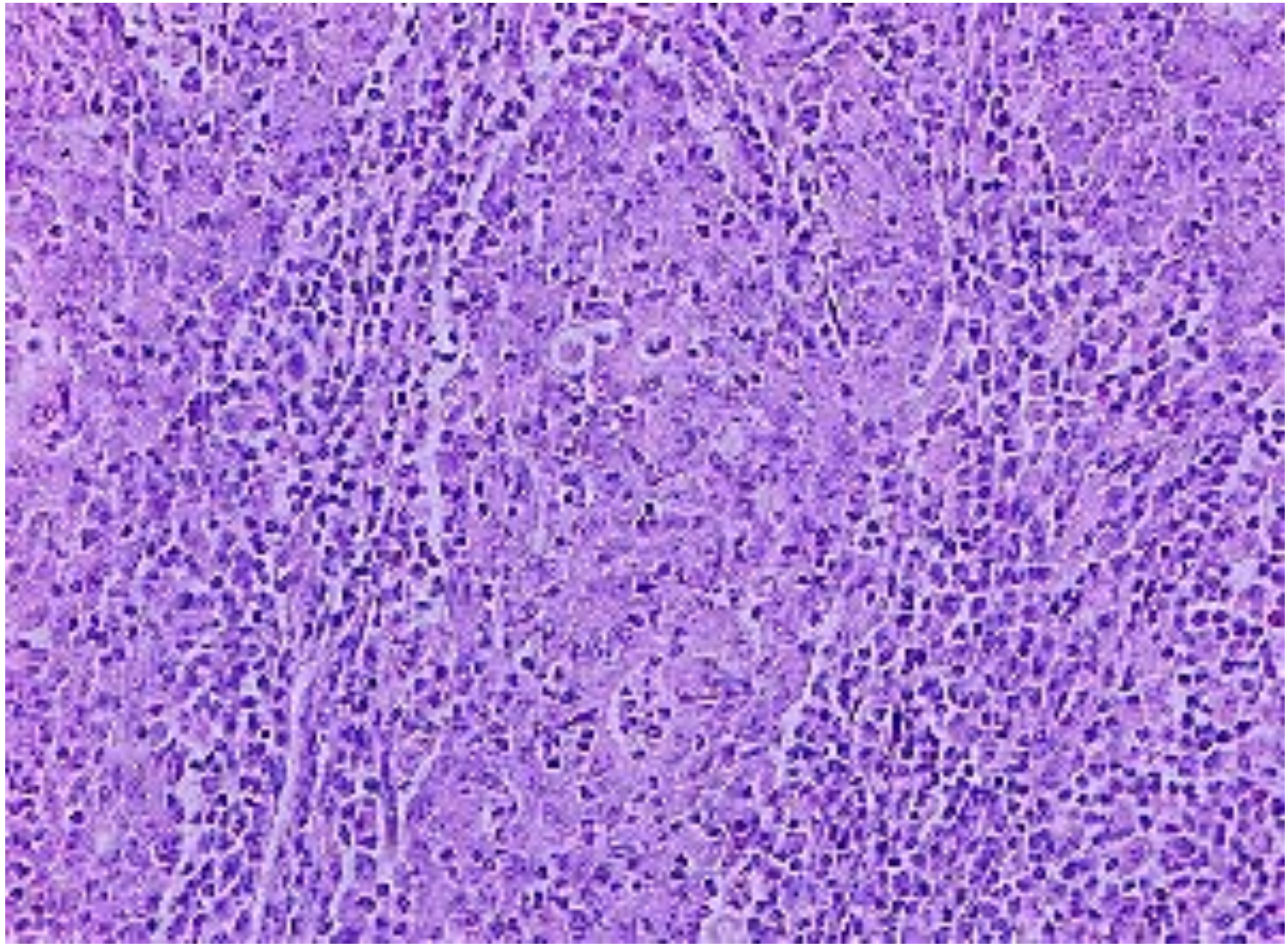

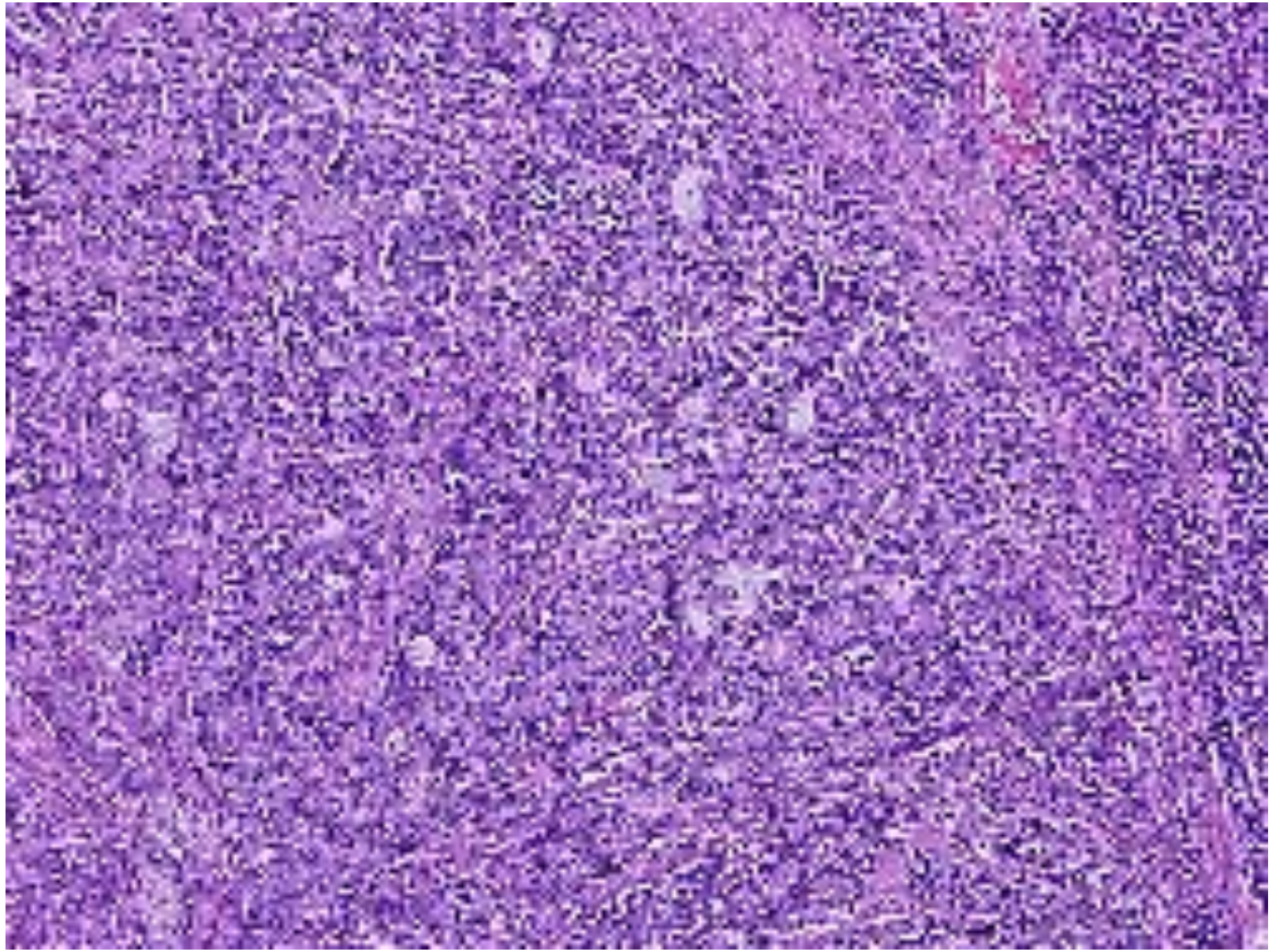

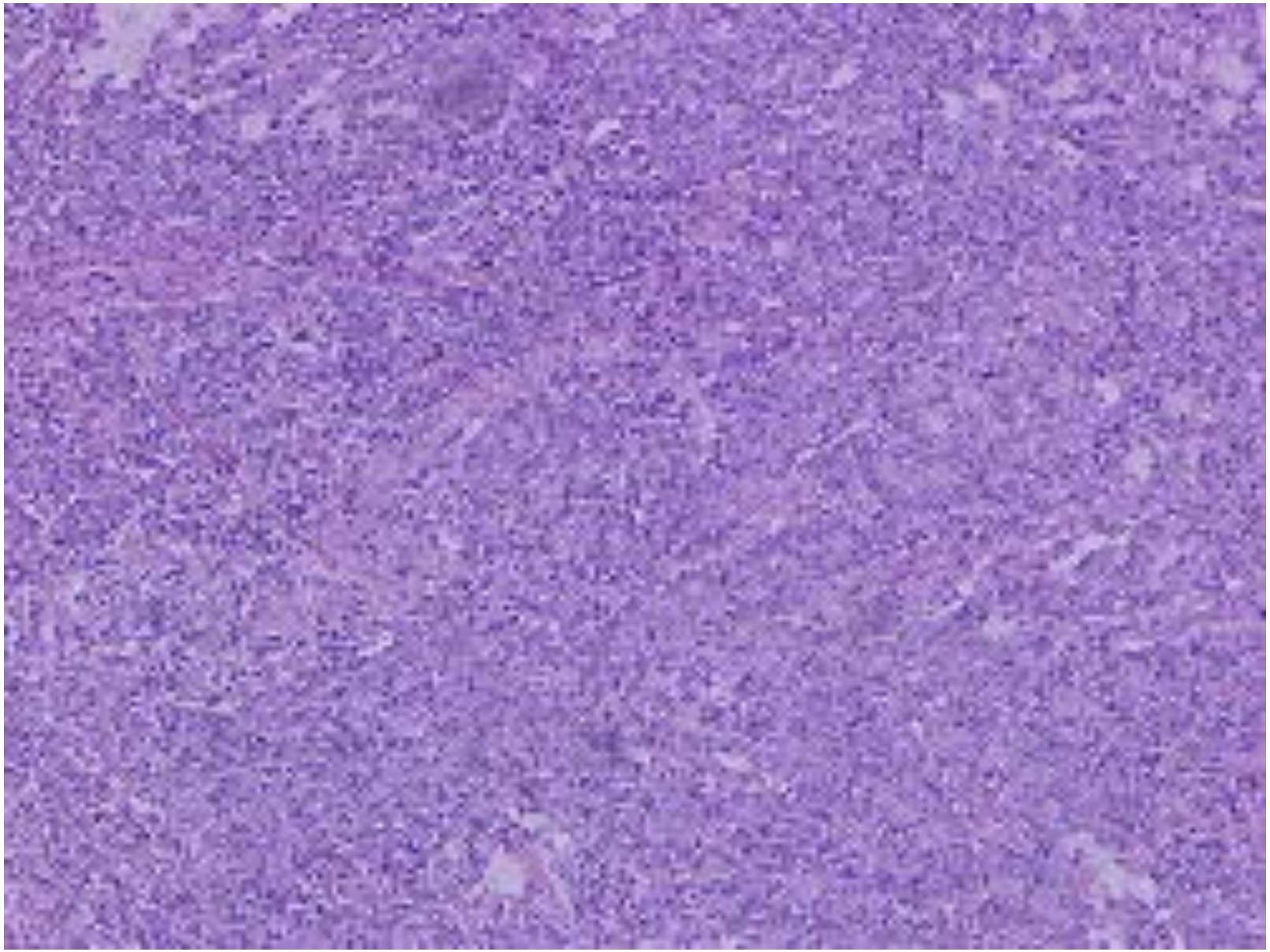

050506535

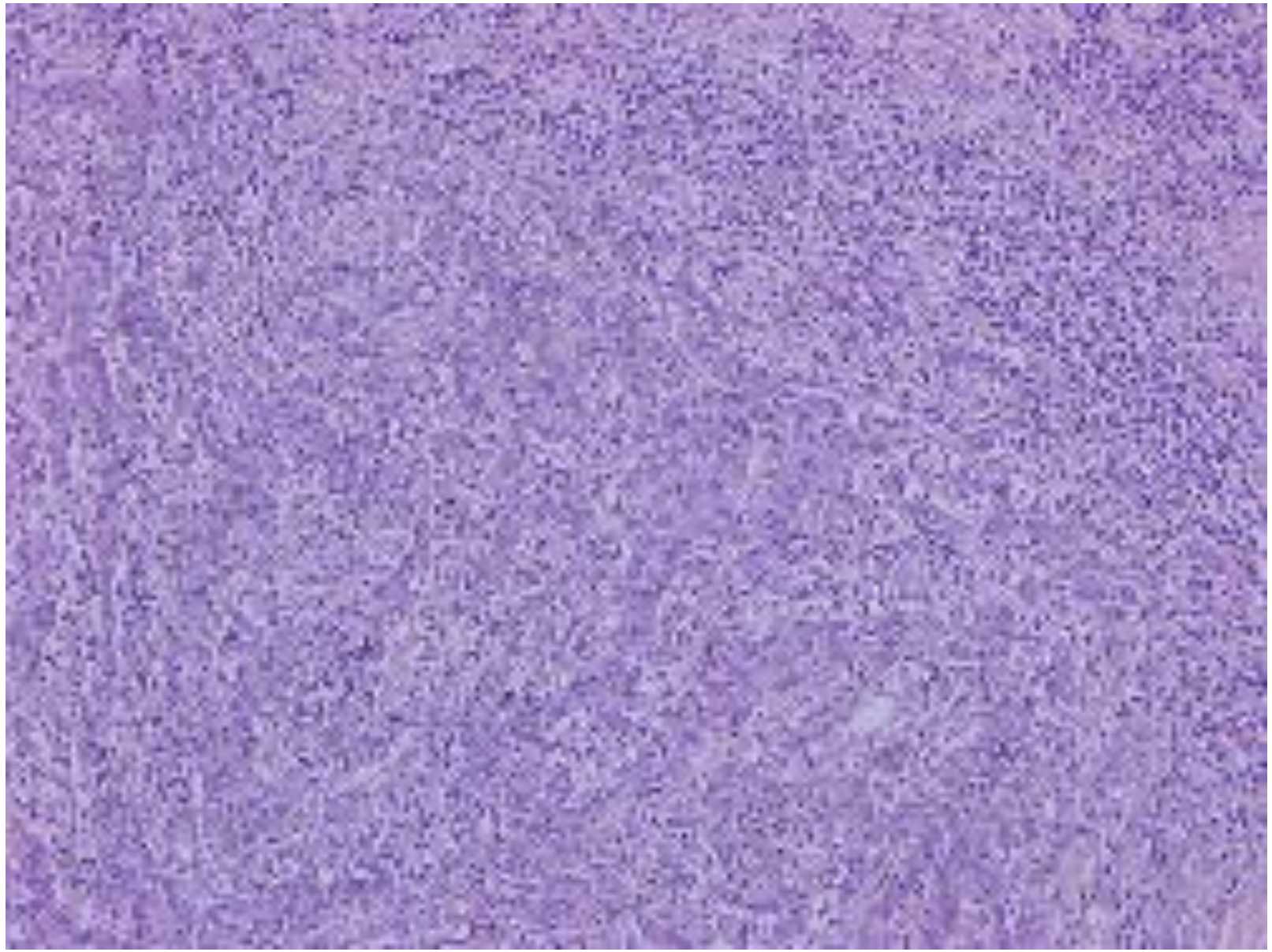

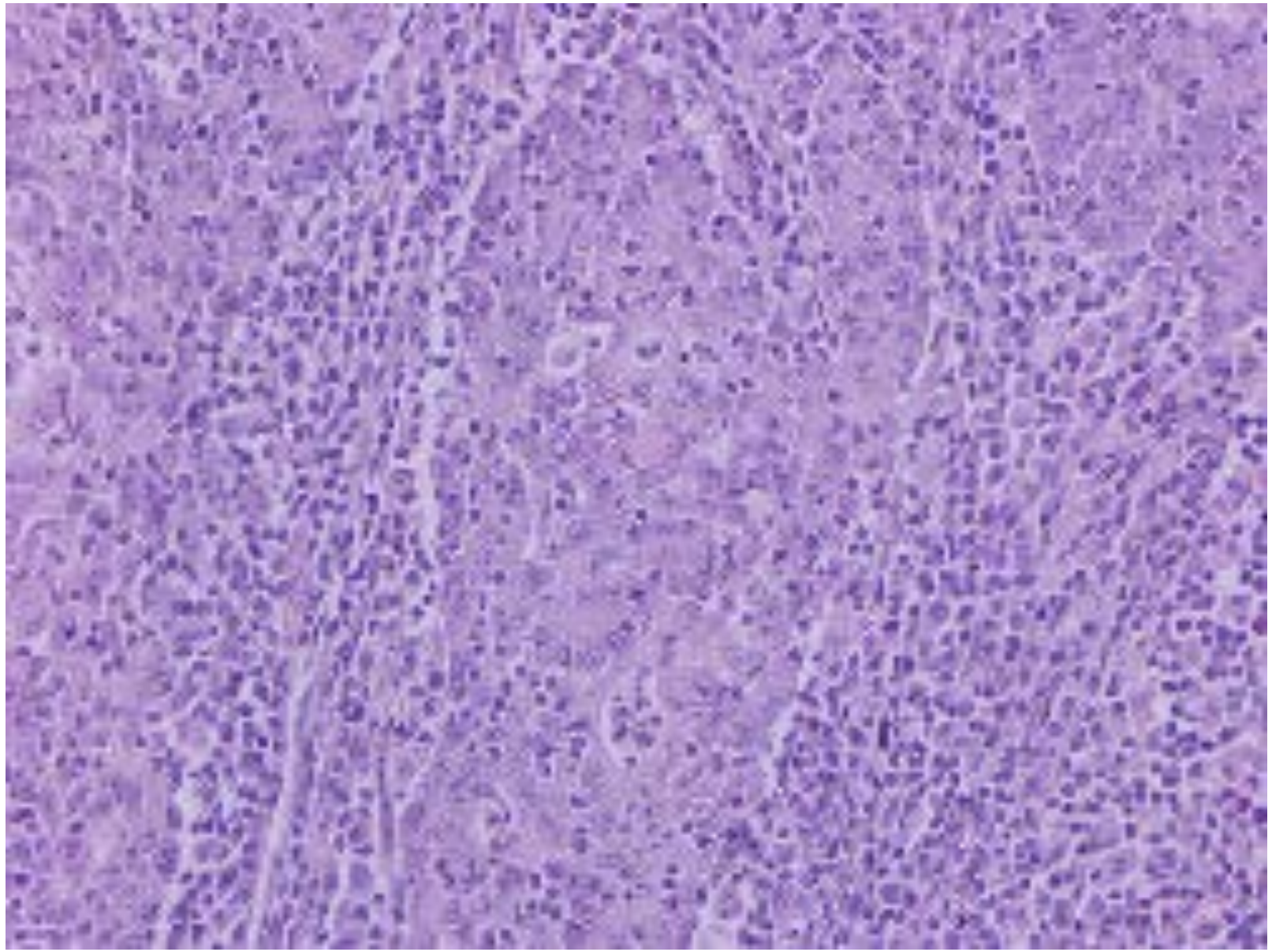

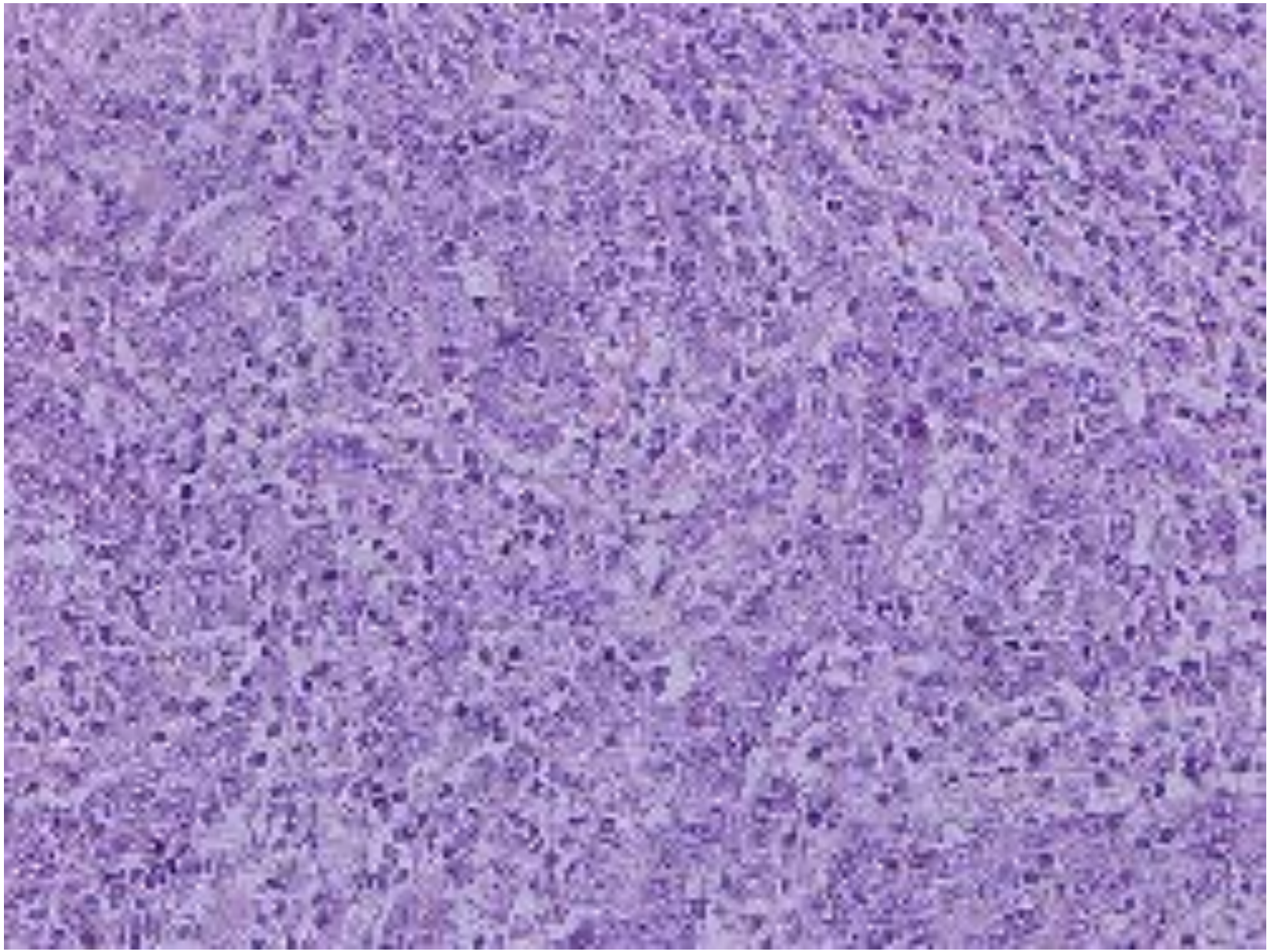

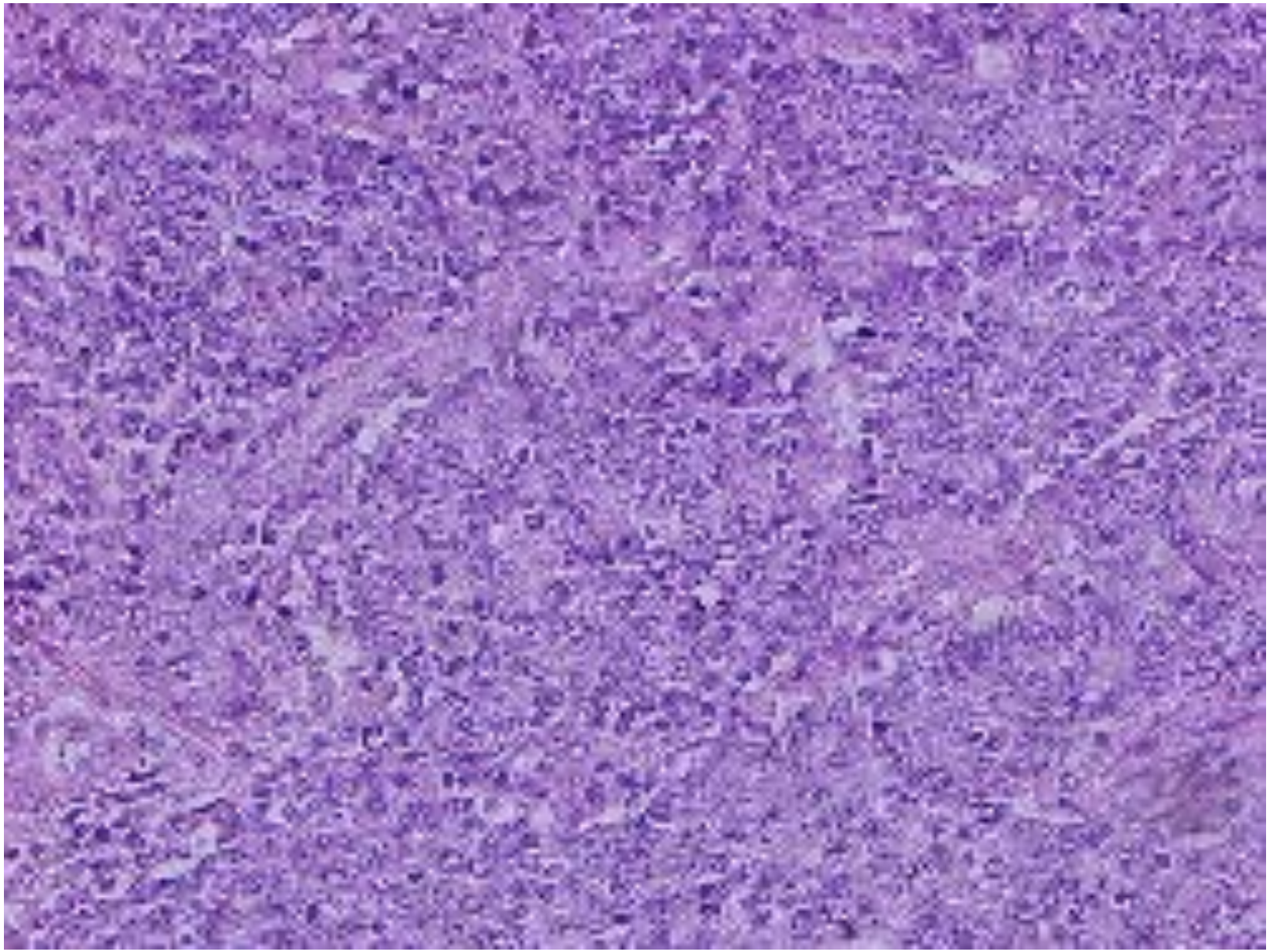

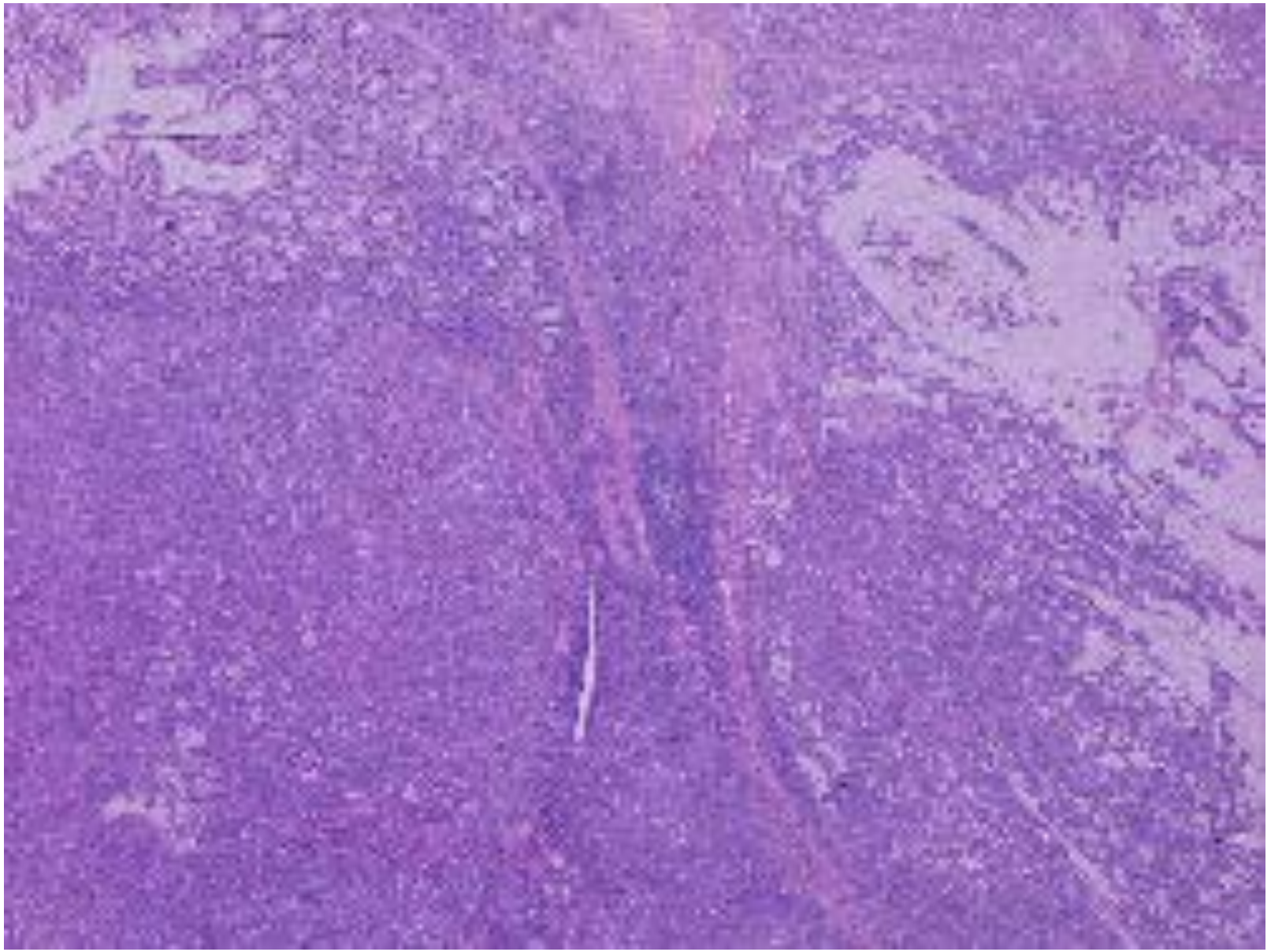
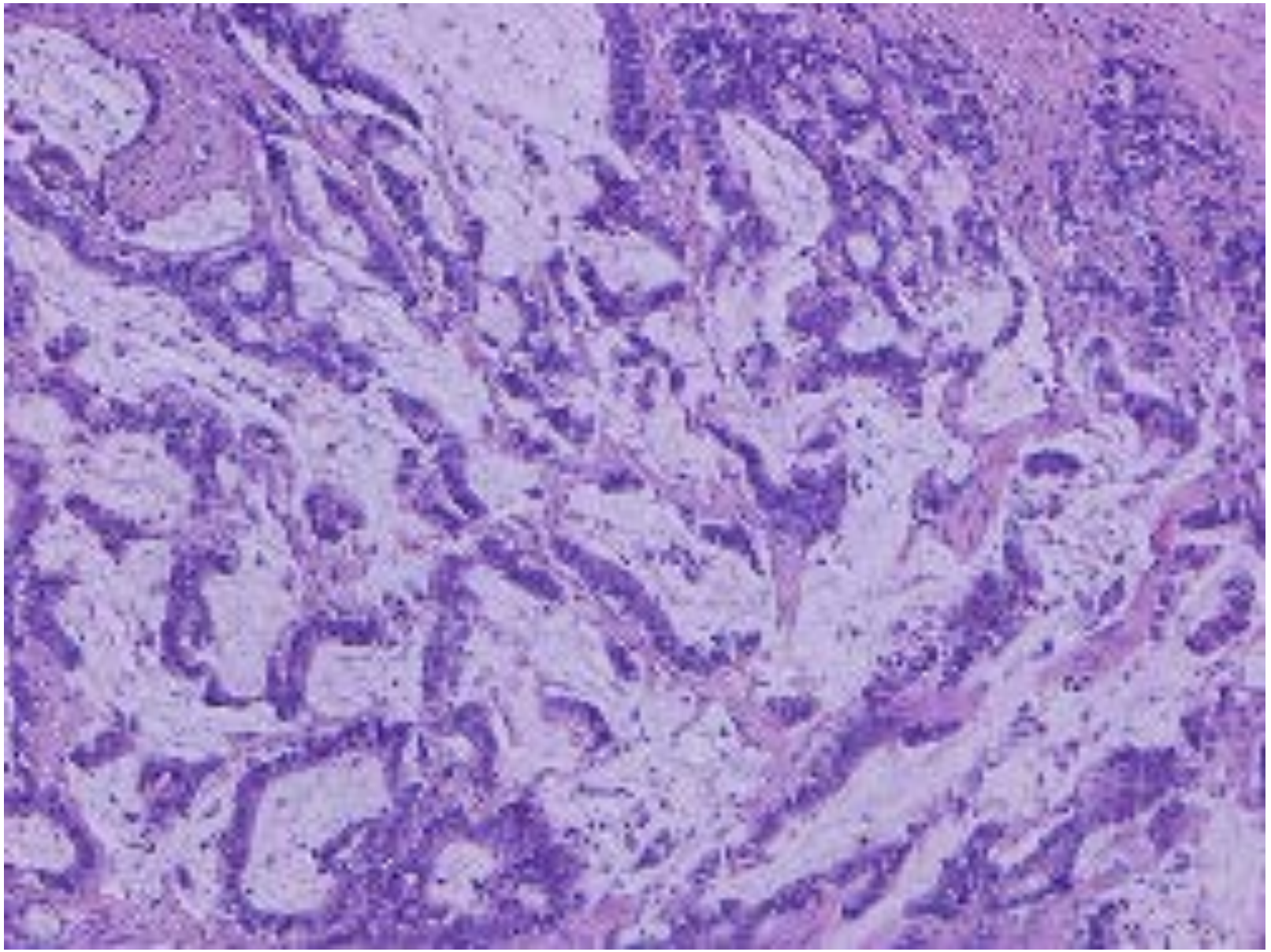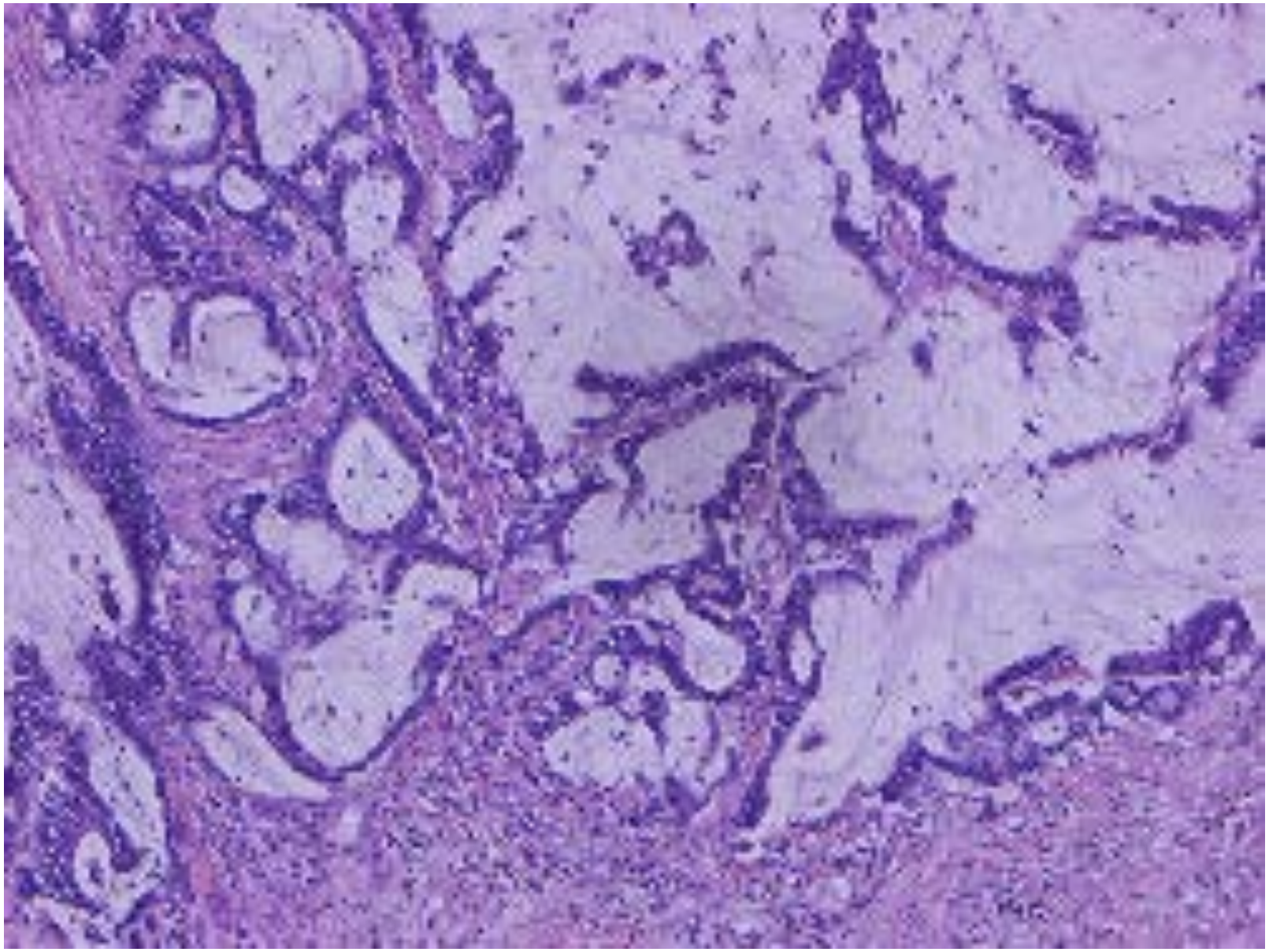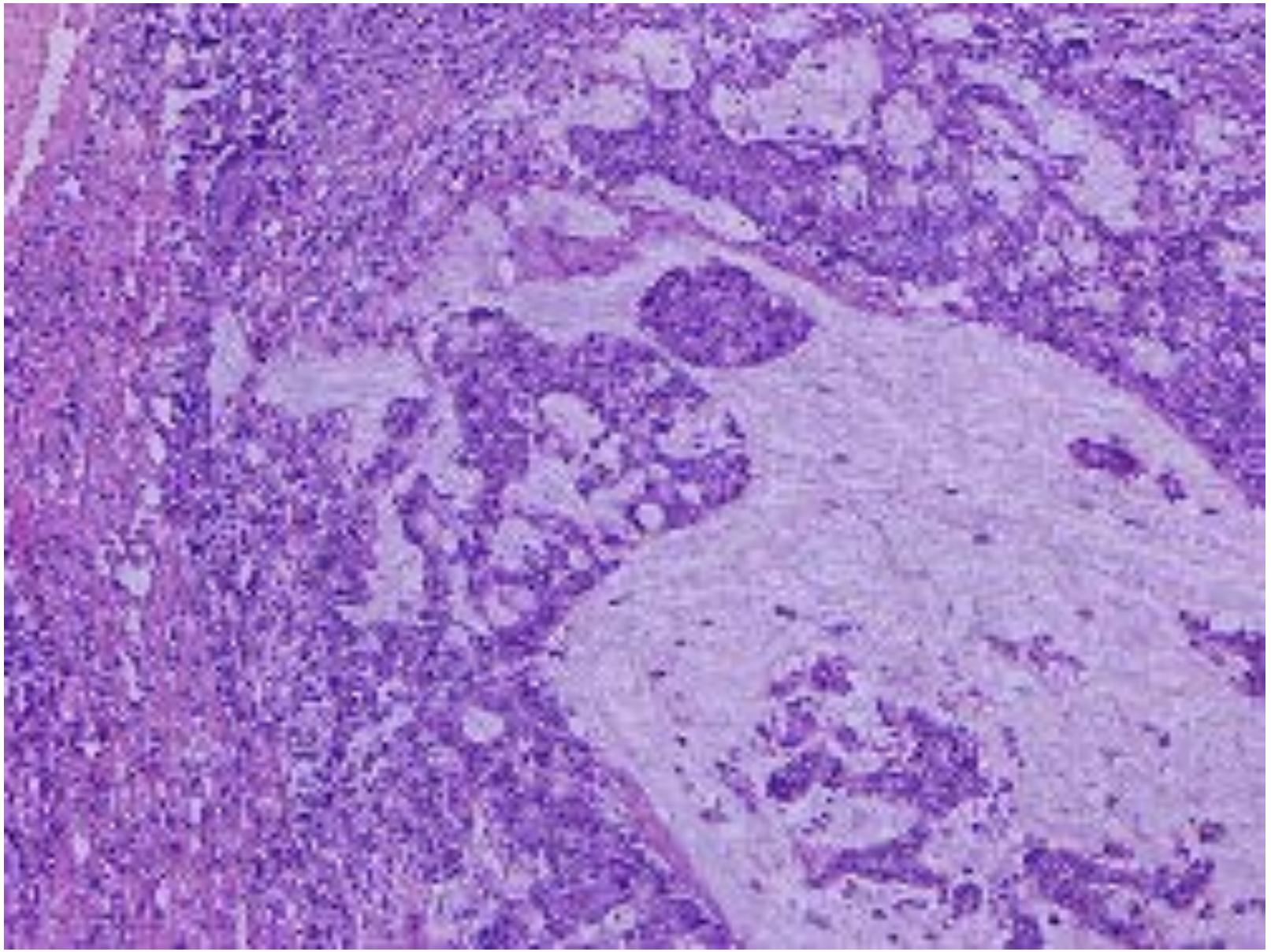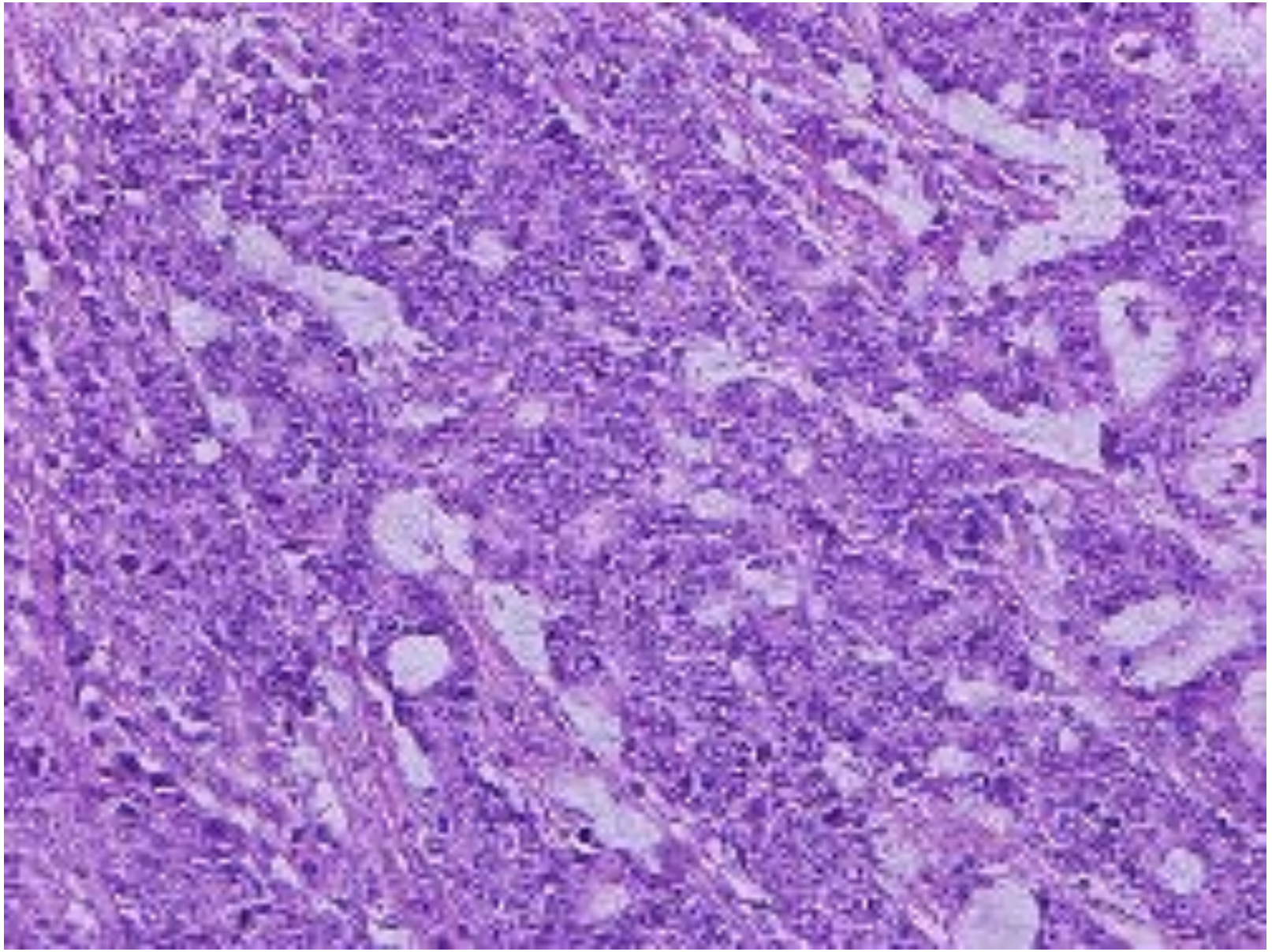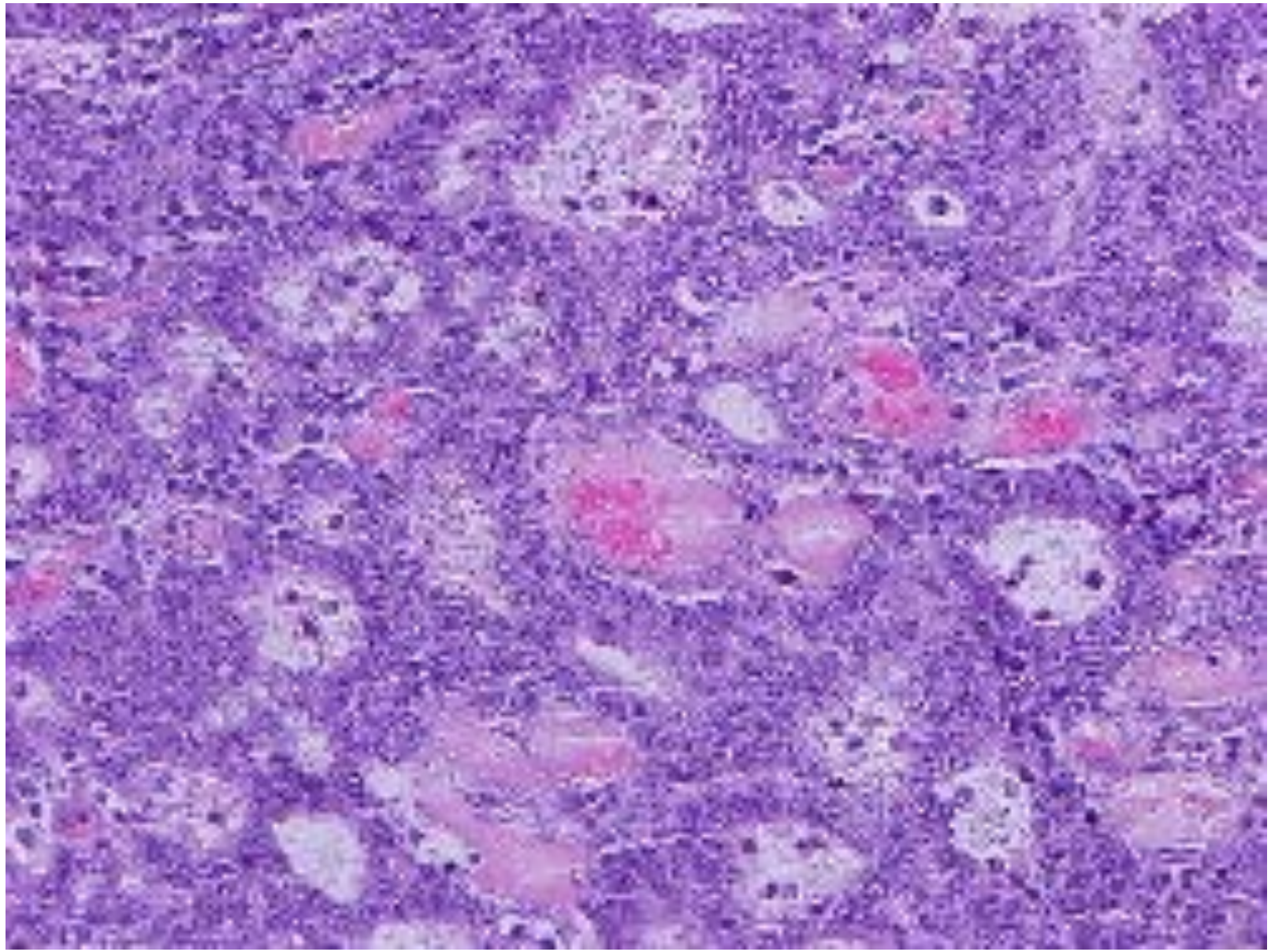
050506535