

RM
della Mammella:
Altre indicazioni
e
problem solving
Casistica

Carbonaro L.A.

Unità di Radiologia, IRCCS Policlinico San Donato, San Donato, Milanese, Milano

**BREAST MRI:
BASES AND CASES**



**21 SETTEMBRE 2018
SEGRATE (MI)**
HOTEL NH MILANO 2
via Fratelli Cervi
SEGRATE (MI)



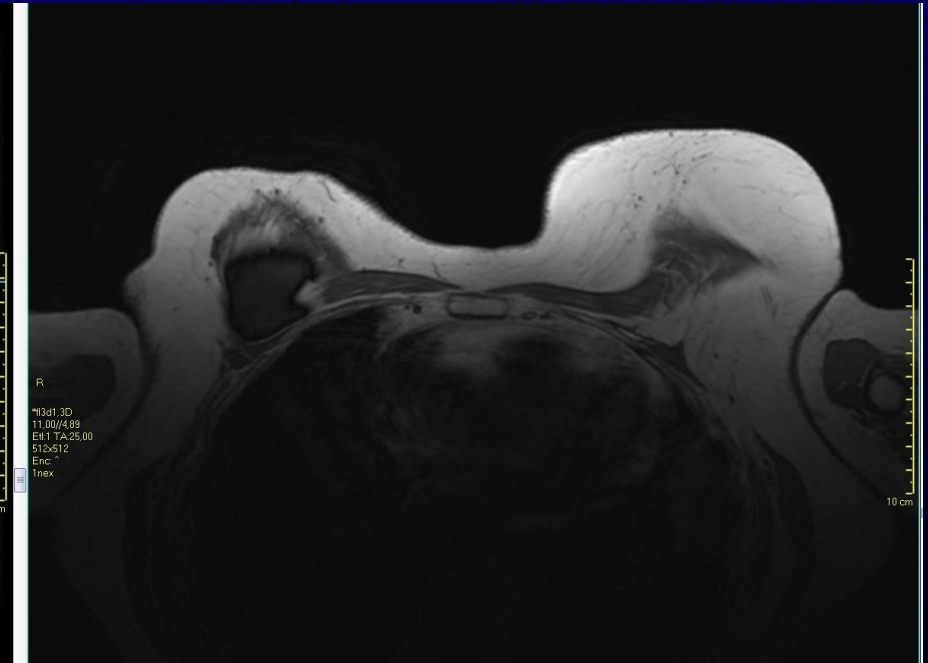
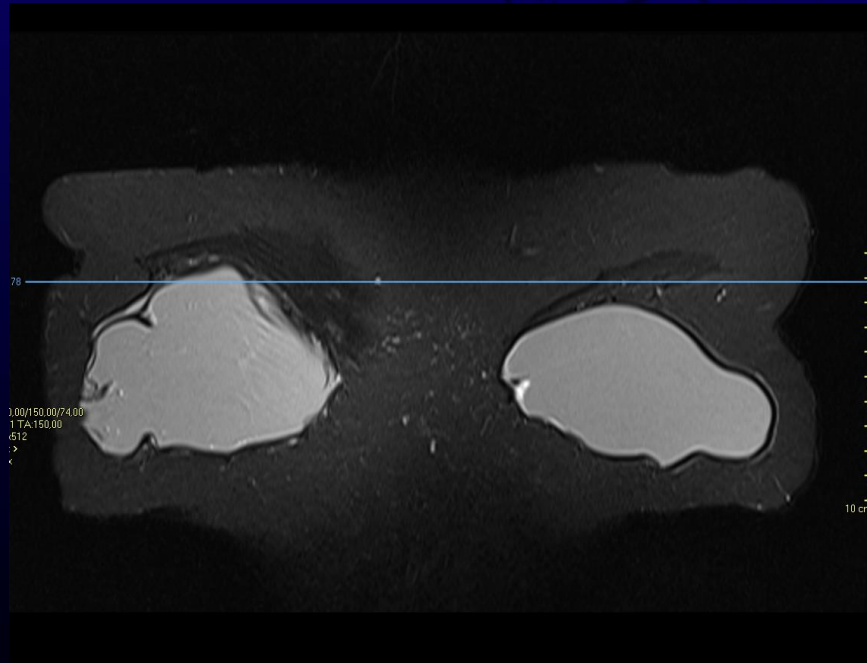
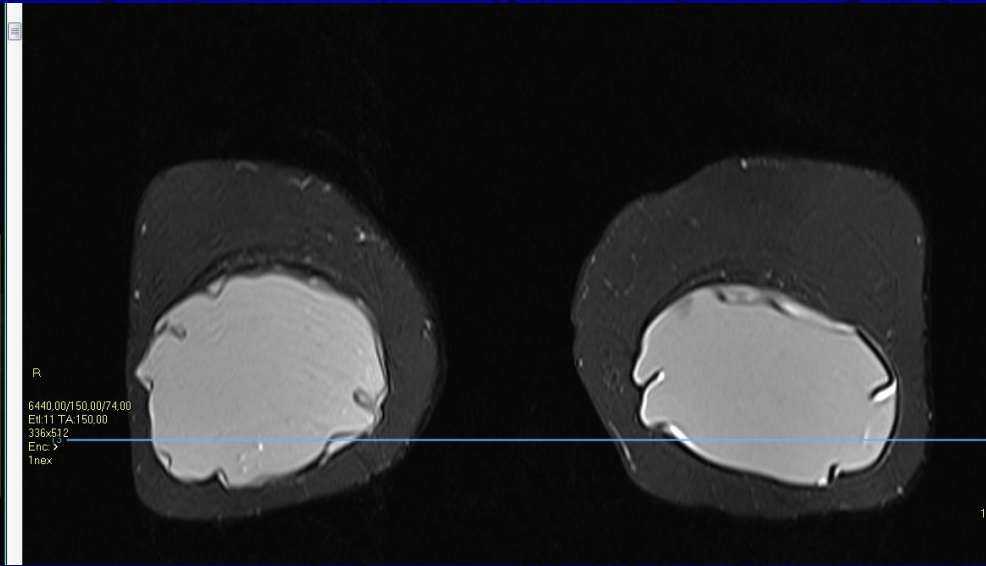
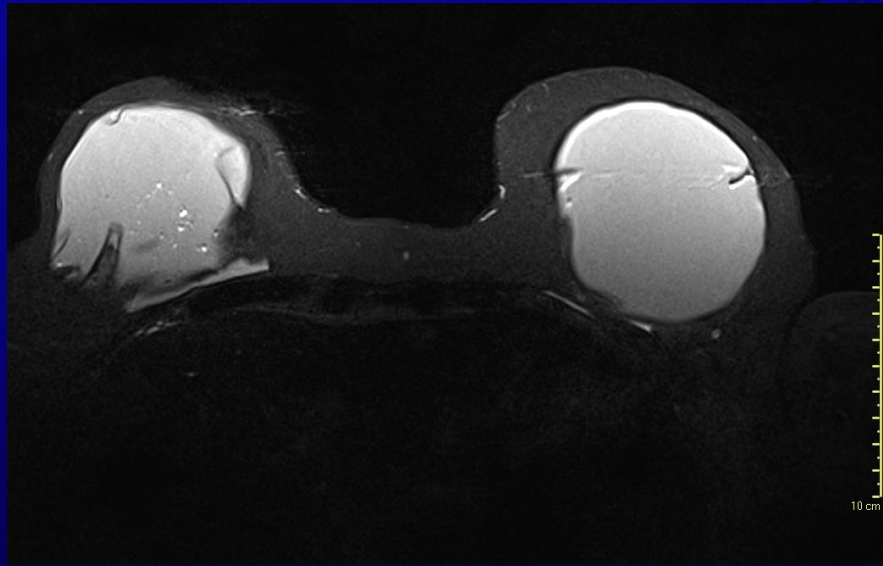
I.R.C.C.S.
POLICLINICO
SAN DONATO

Caso P1

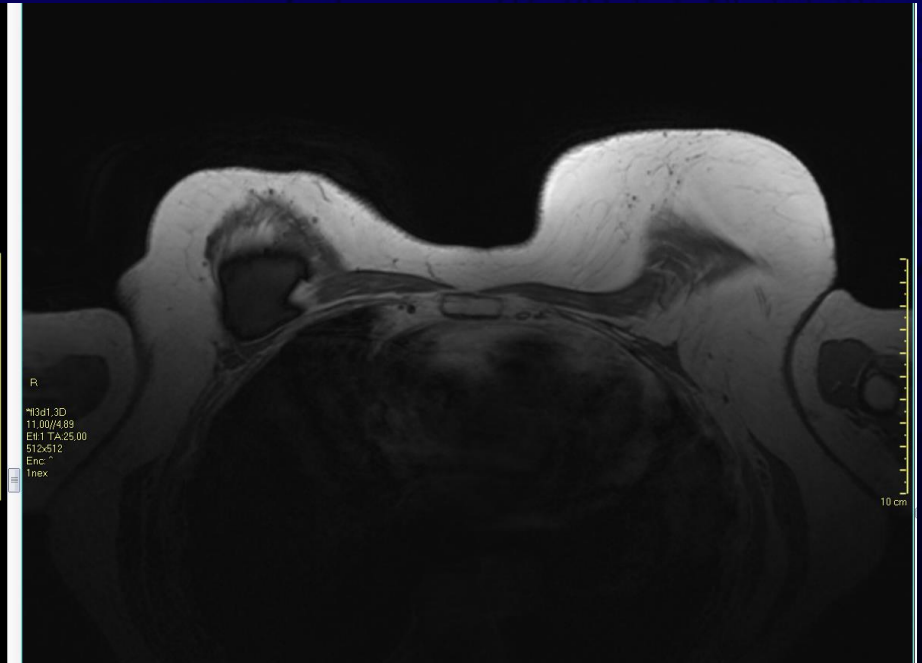
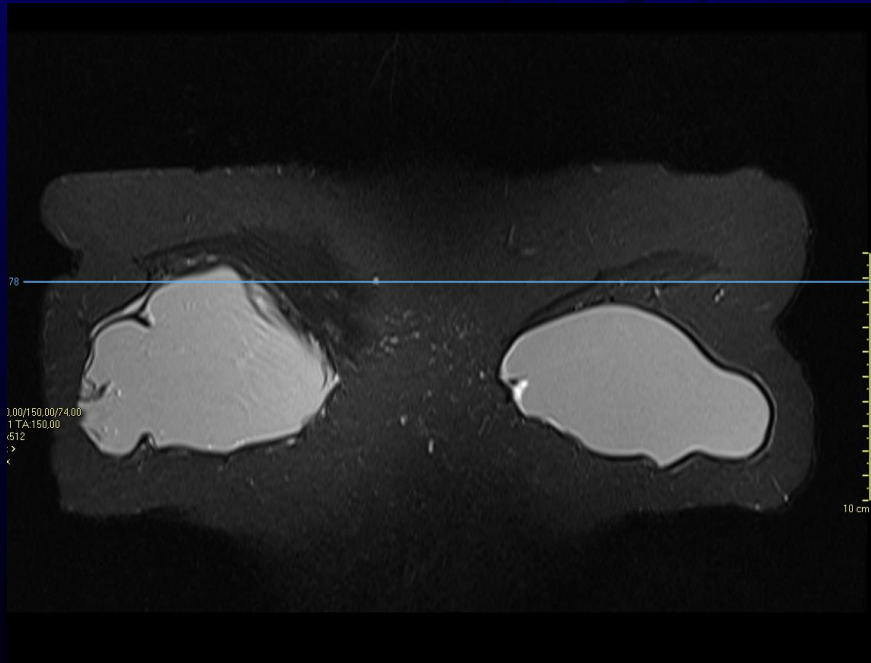
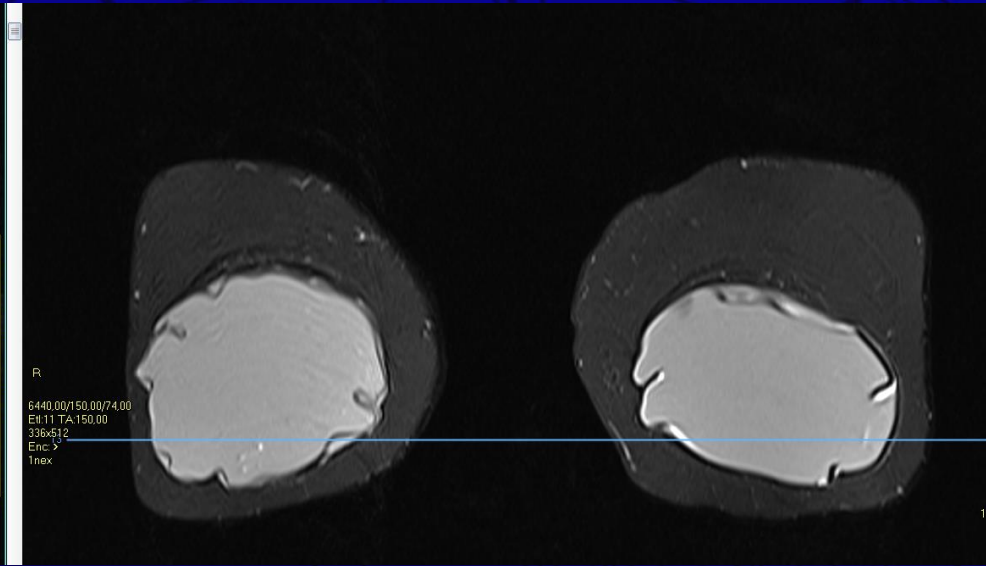
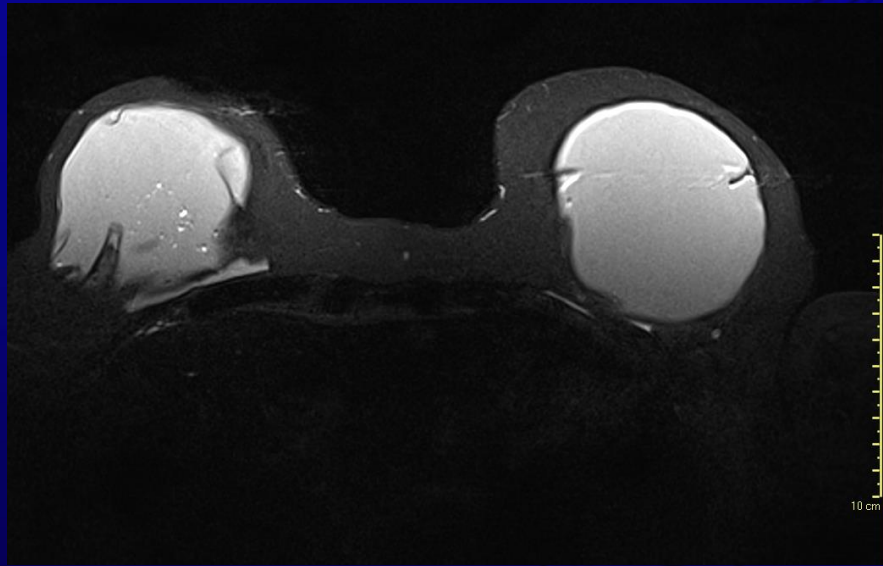


71 aa.

Protesi additiva 11 anni prima



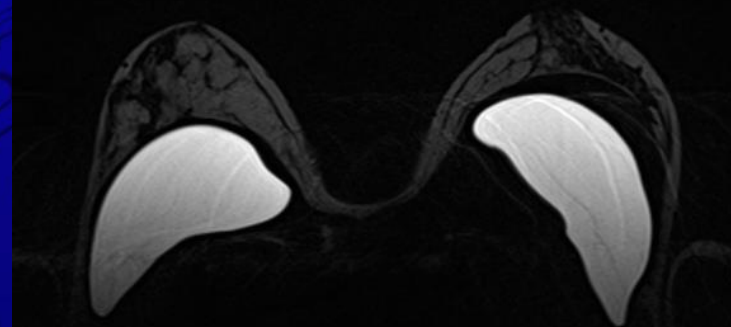
Sottomuscolare bilaterale. Rottura intracapsulare destra; pieghe radiali sinistra



Caso P2



MELE SENZA CONTRASTO



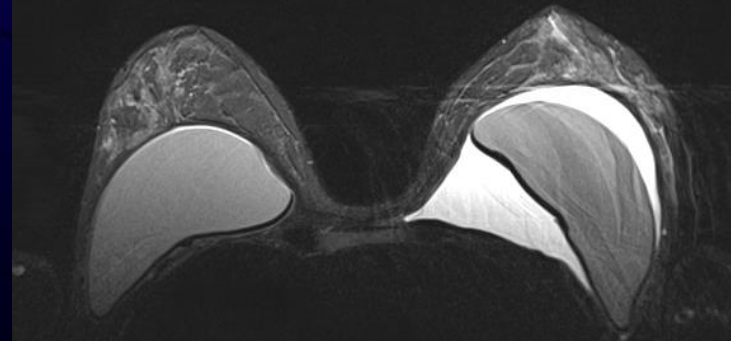
STIR wat sat

P

[02/12/2016 , 12:43:53]

STIR

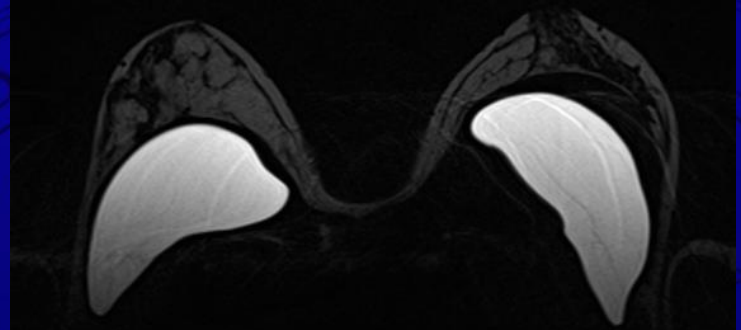
MELE SENZA CONTRASTO



45 aa.
Protesi additiva nel 2011.
Asimmetria e sospetta
rottura protesica sinistra

No rottura
Rotazione sinistra
Falda periprotesica

MELE SENZA CONTRASTO



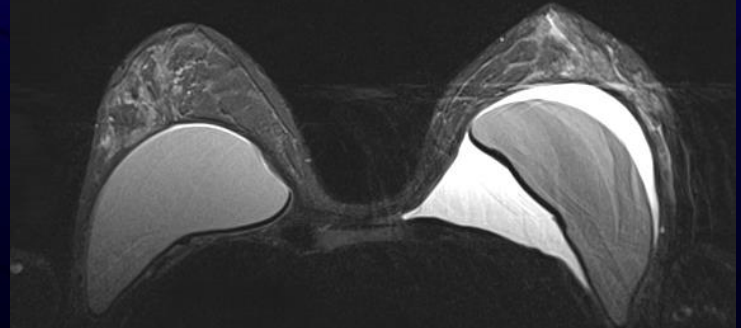
STIR wat sat

P

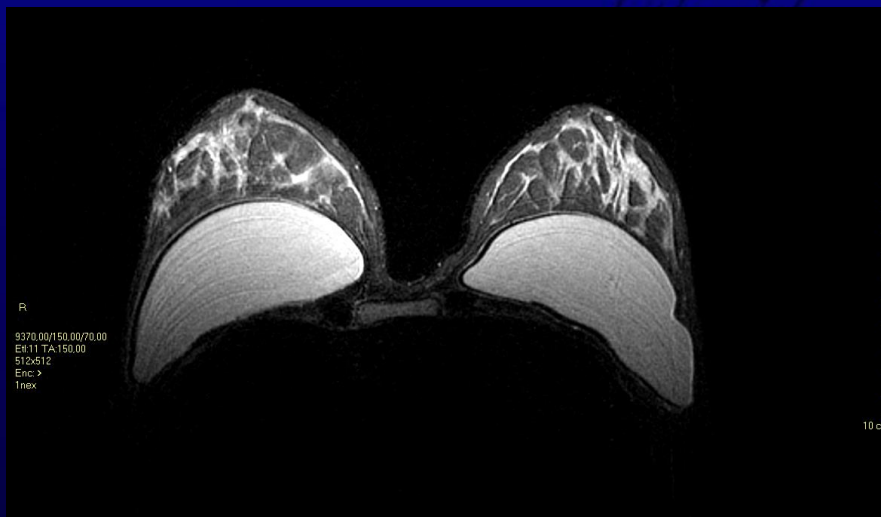
[02/12/2016 , 12:43:53]

STIR

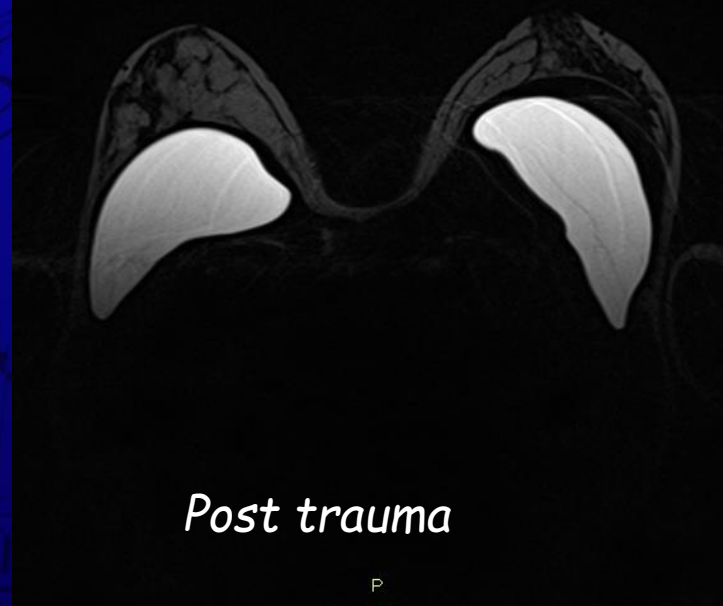MELE SENZA CONTRASTO



Pre trauma

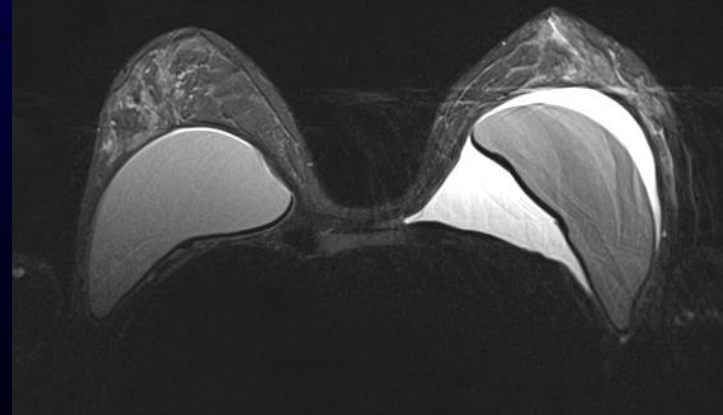


MELE SENZA CONTRASTO



[02/12/2016 , 12:43:53]

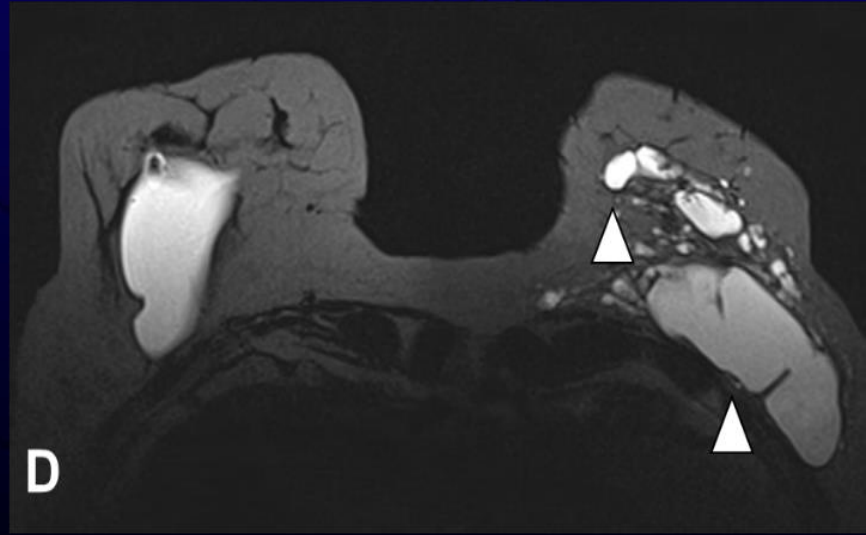
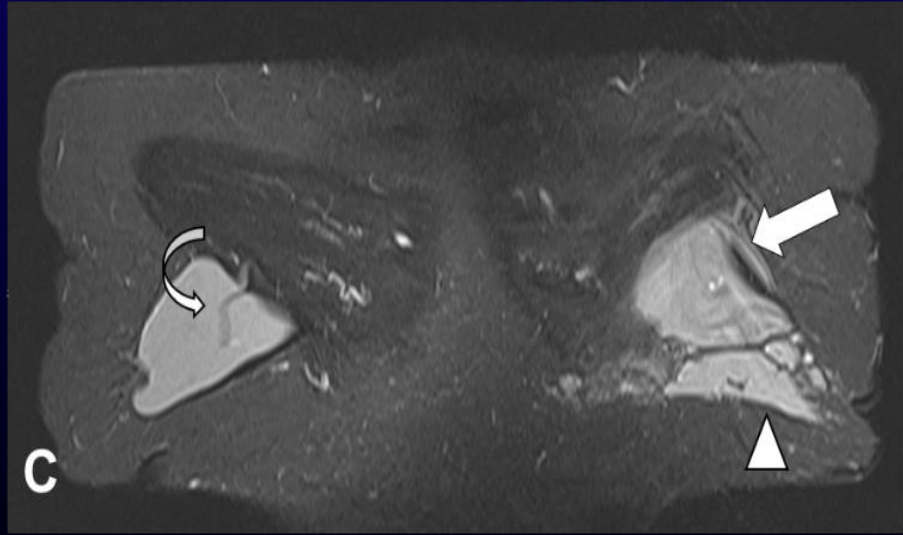
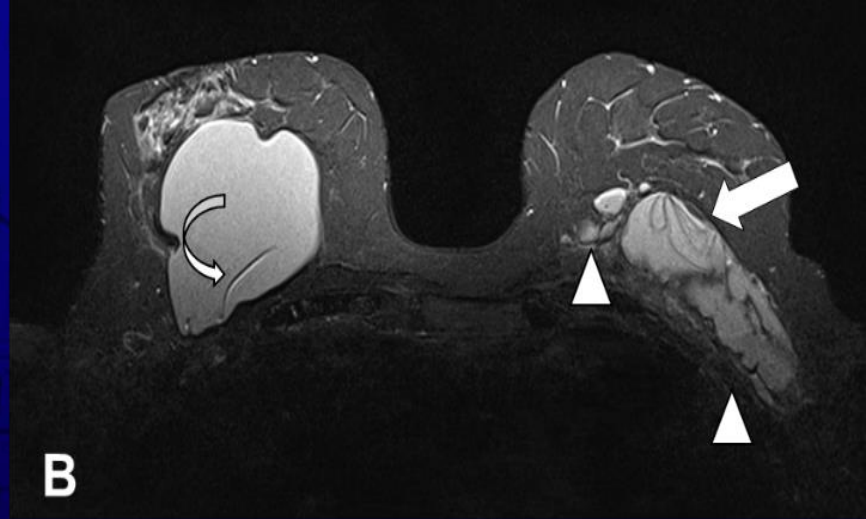
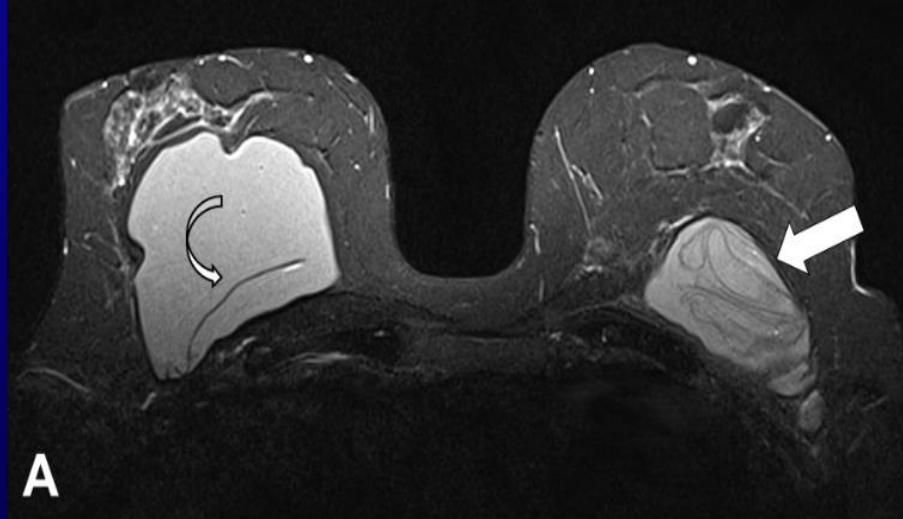
MELE SENZA CONTRASTO



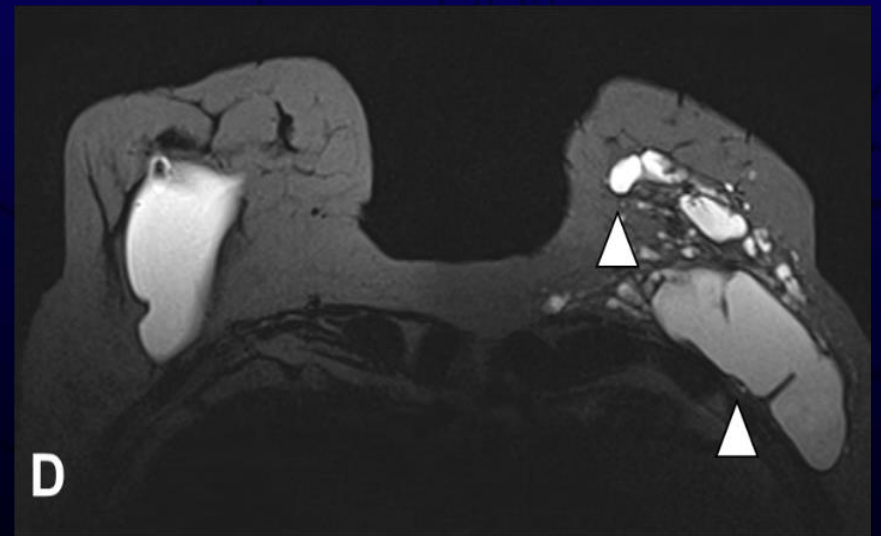
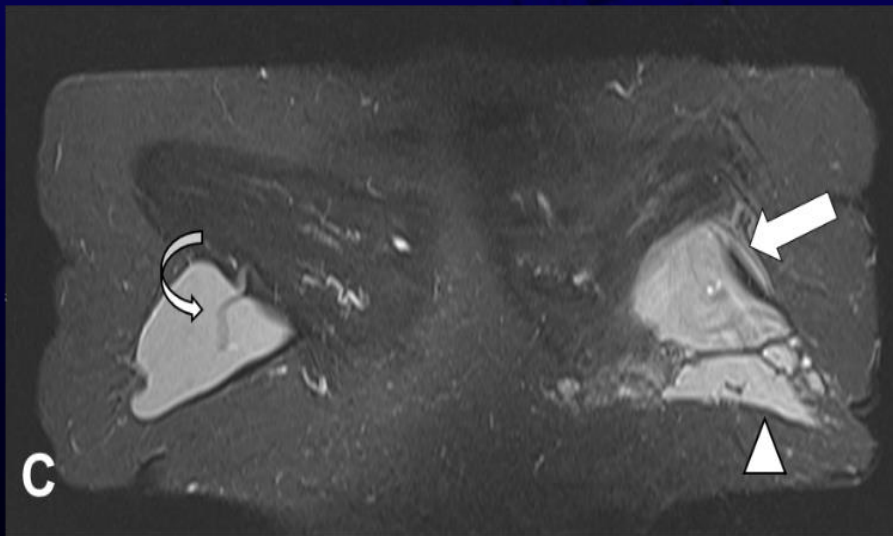
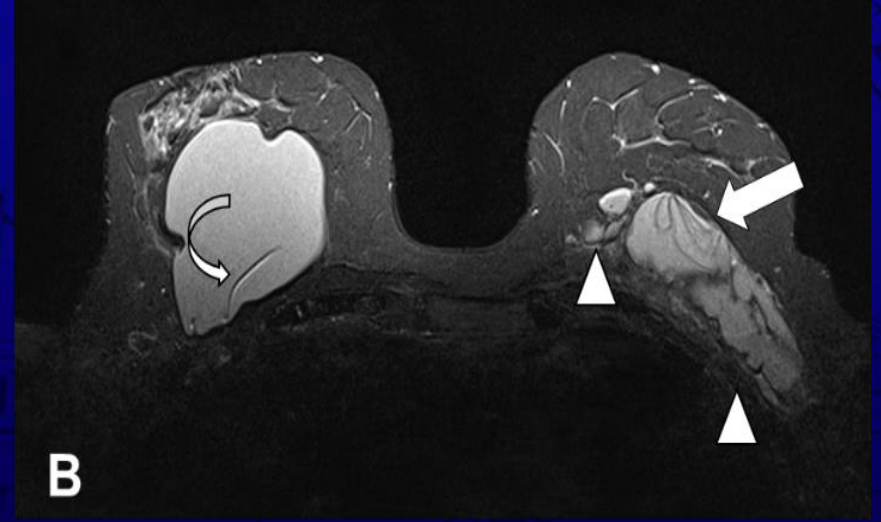
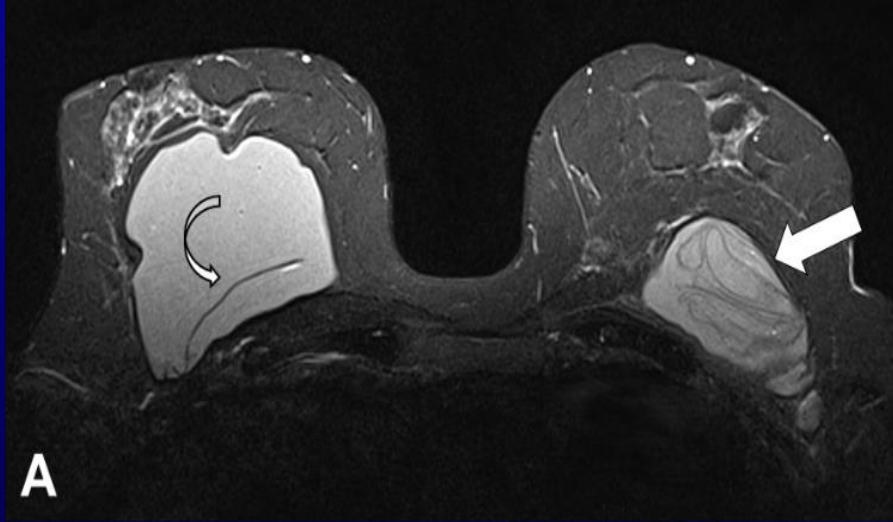
Caso P3



64 aa.
Protesi additiva 15aa prima



Protesi retroghiandolari
Rottura intra-extracapsulare a sinistra
Pieghe a destra

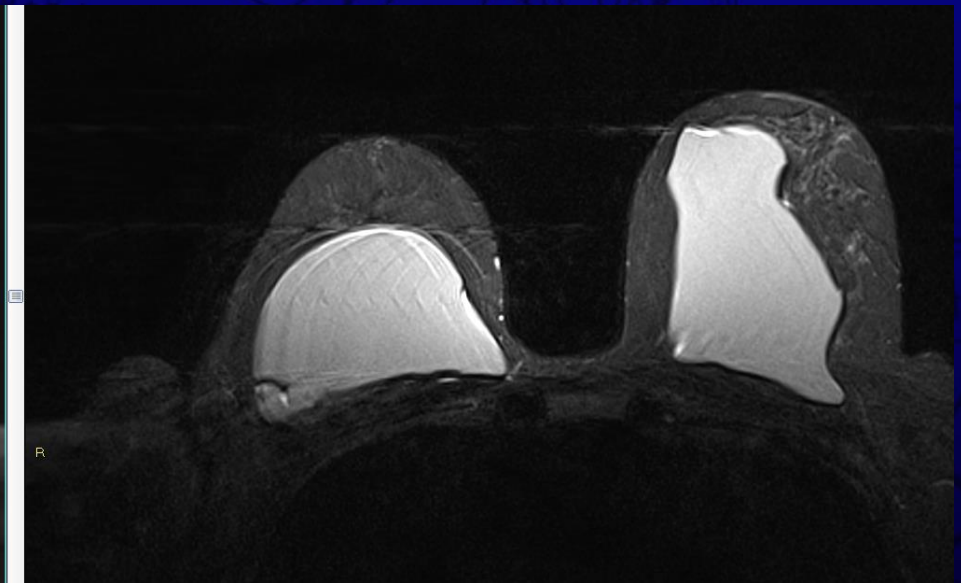
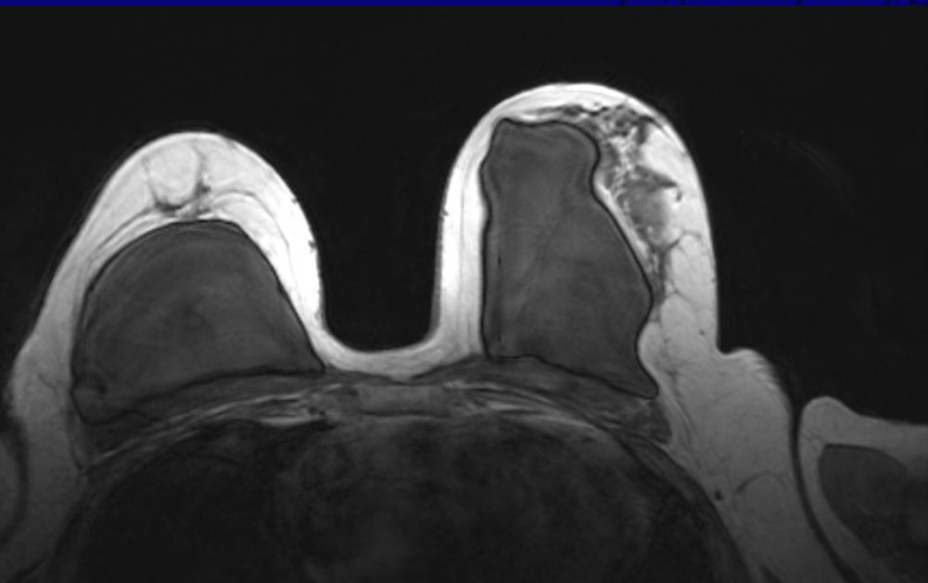


Caso P4

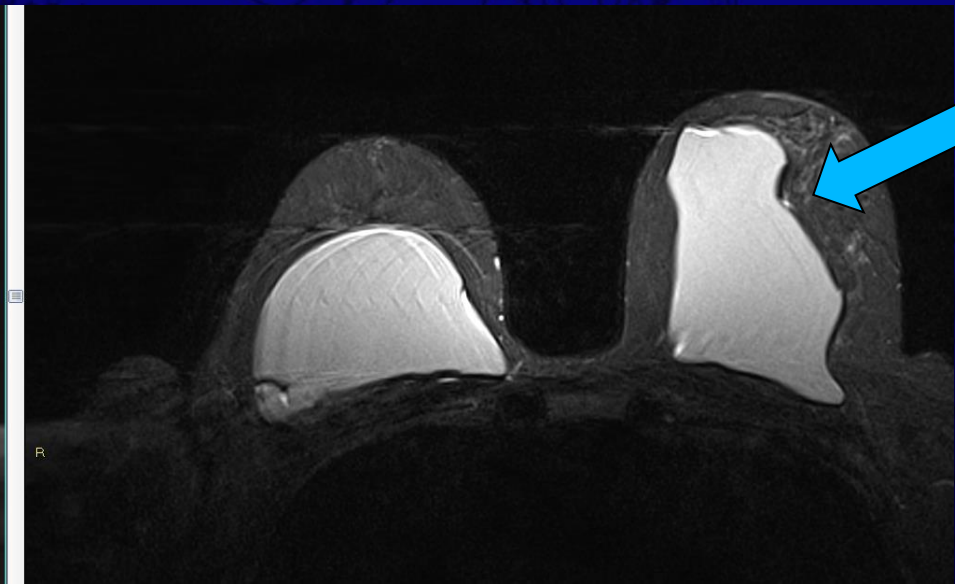
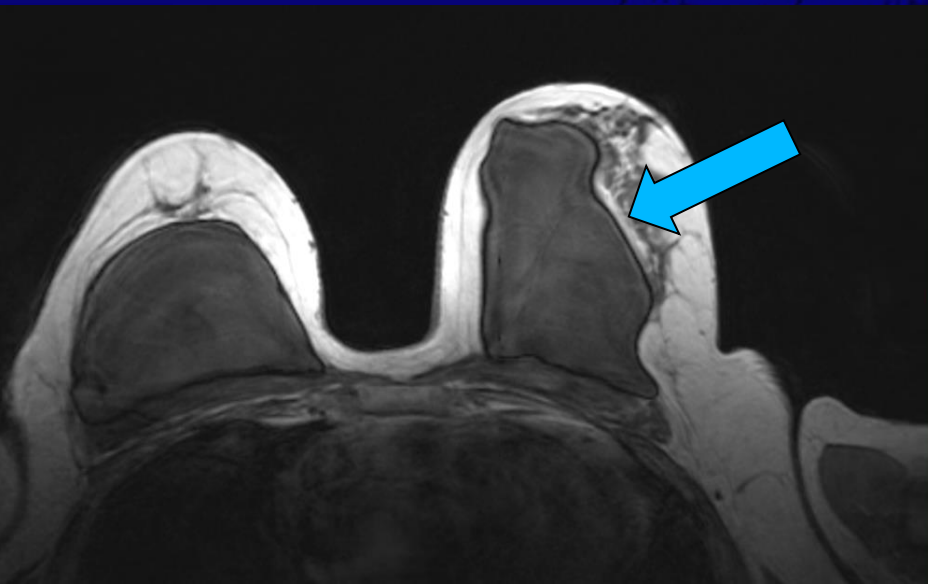


72 aa.

Protesi additiva in esiti di QUART al QSE destro nel 2002.



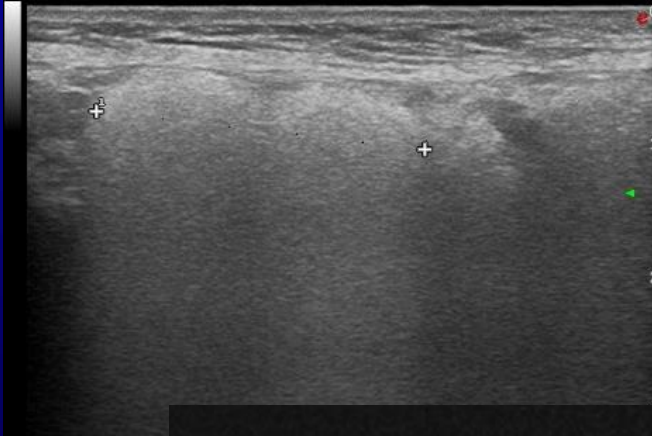
*Retroghiandolare con asimmetria
Protesi sinistra ruotata senza falda fluida
Solo ecografie precedenti date negative per rottura*



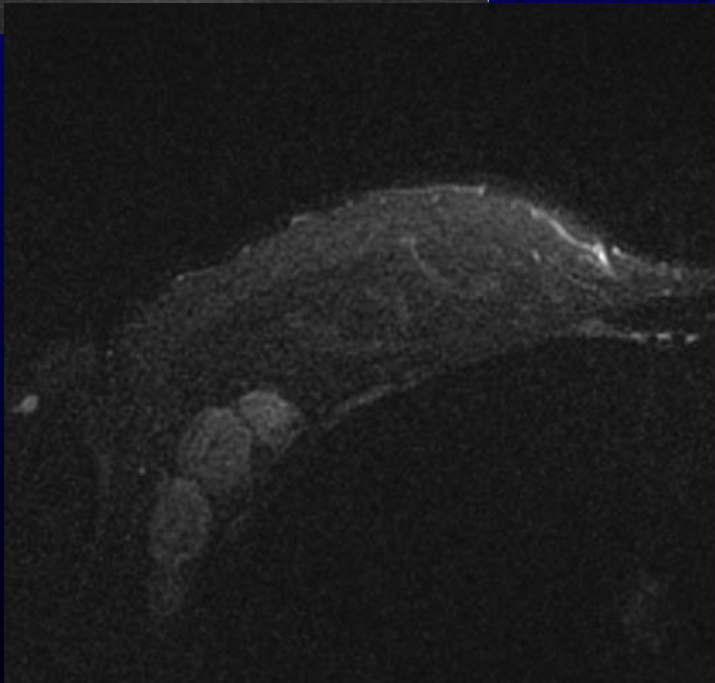
Caso P5

The background features a large, faint watermark of the seal of the University of Medellín. The seal is circular and contains a central figure of a woman in classical attire, holding a torch in her right hand and a branch in her left. The text 'UNIVERSITAS STUDIORUM MEDIANENSIS' is visible around the perimeter of the seal.

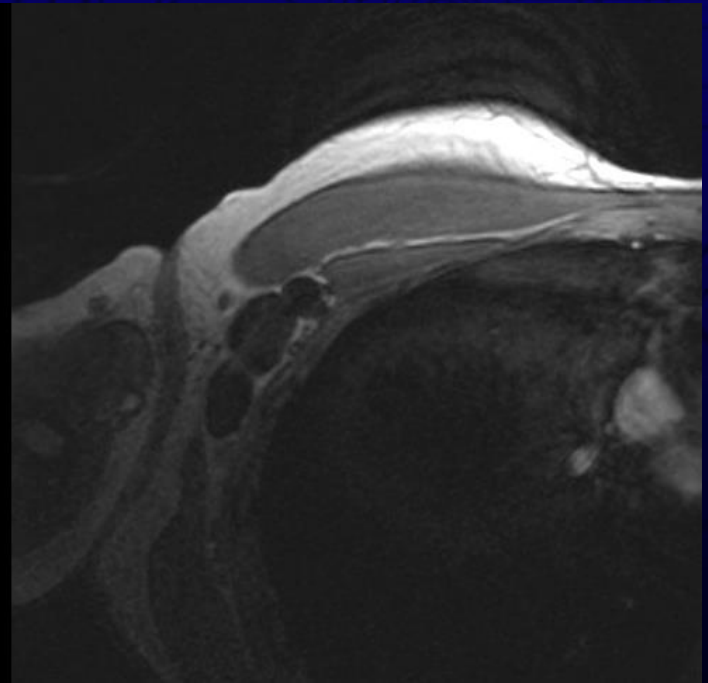
*Progressiva sostituzione impianto per rottura
Effetto ecografico a tempesta di neve a sede ascellare*



*Linfoadenopatie
con silicone*



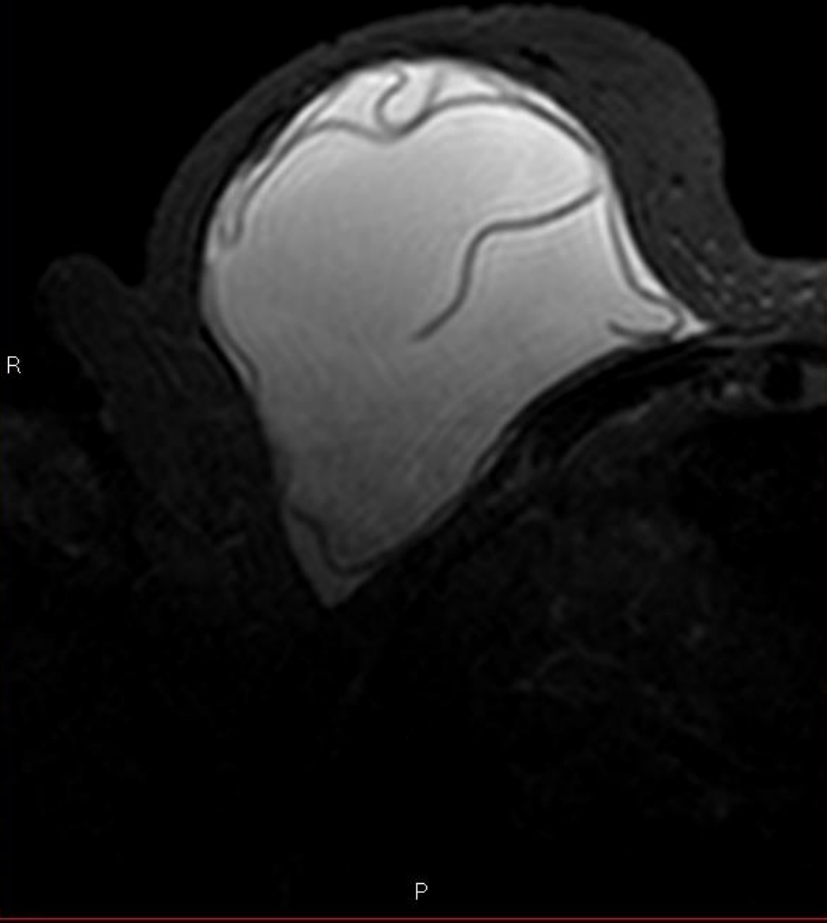
R



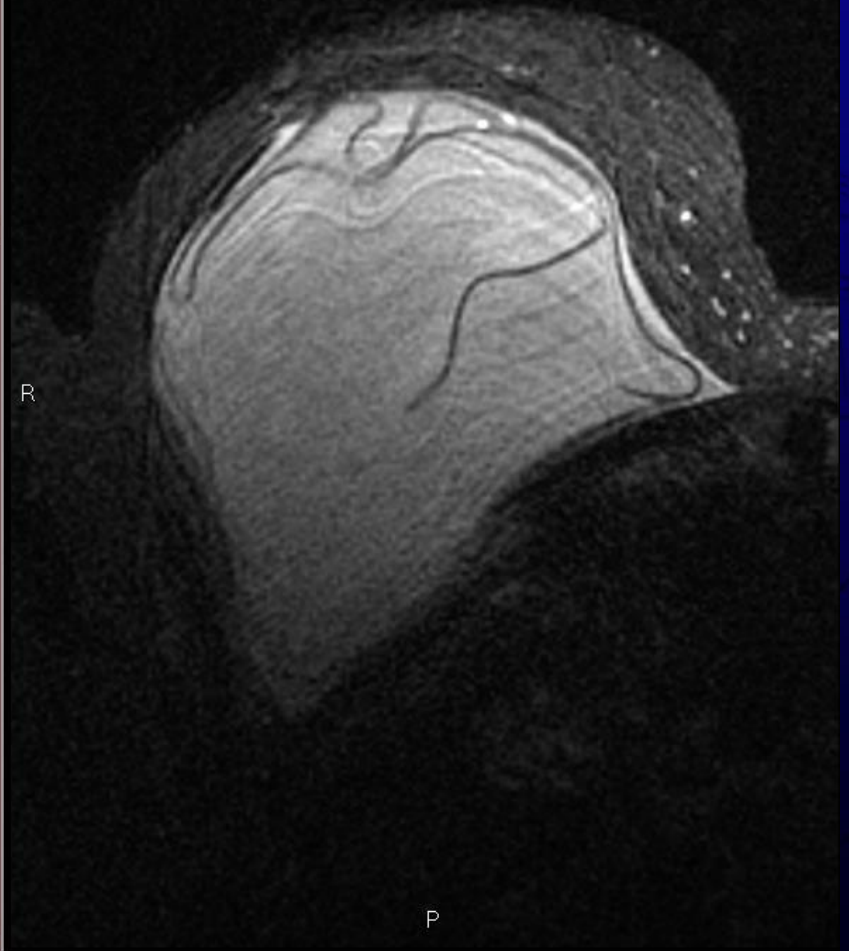


*Casi P
flash*

< 3-17 >



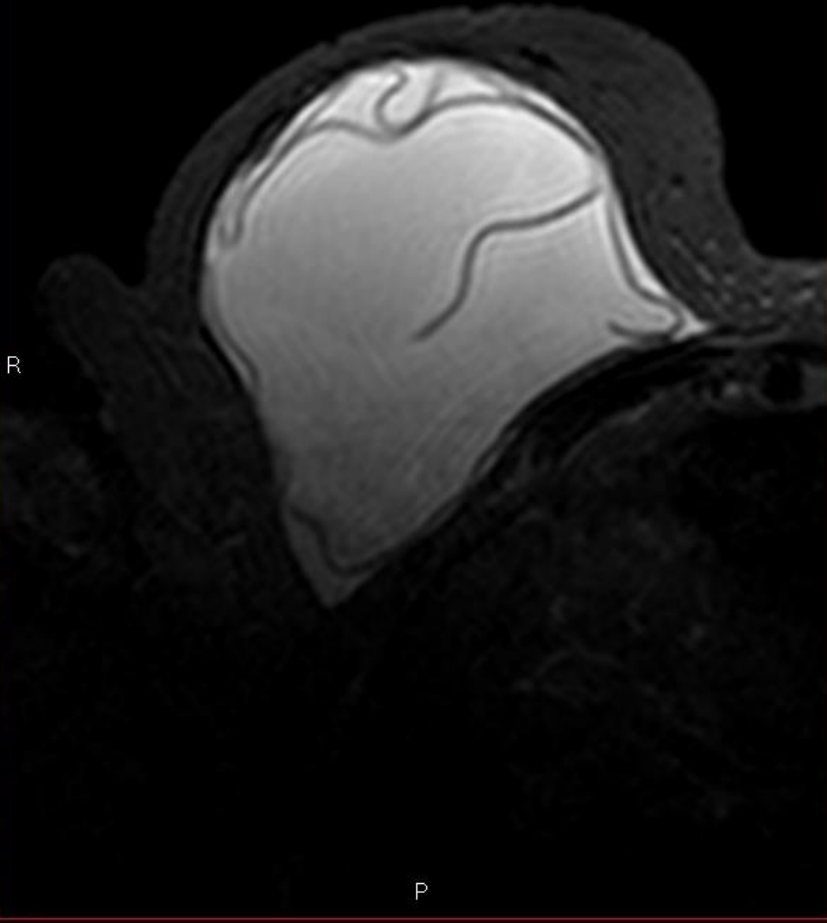
< 2-23 >



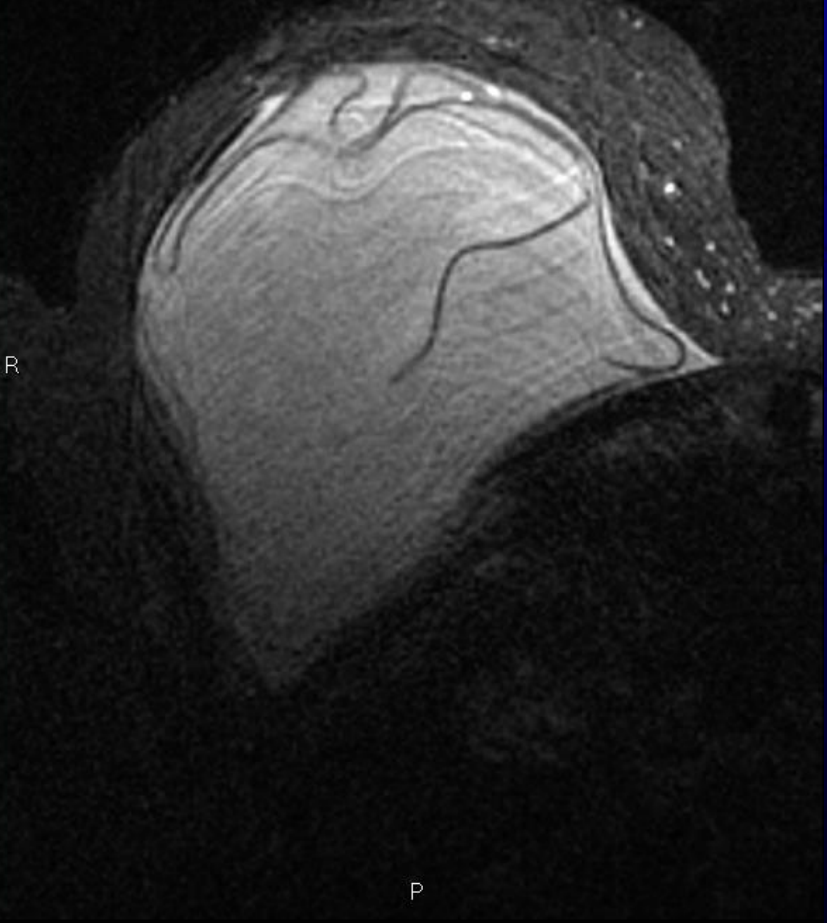
ROTTA



< 3-17 >




< 2-23 >



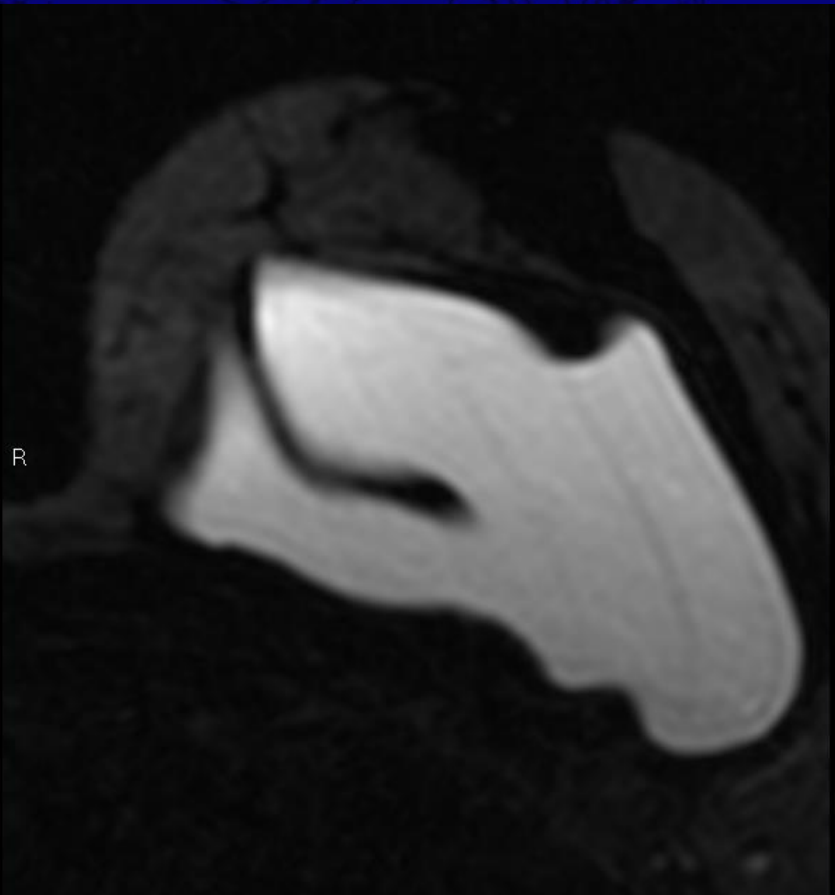
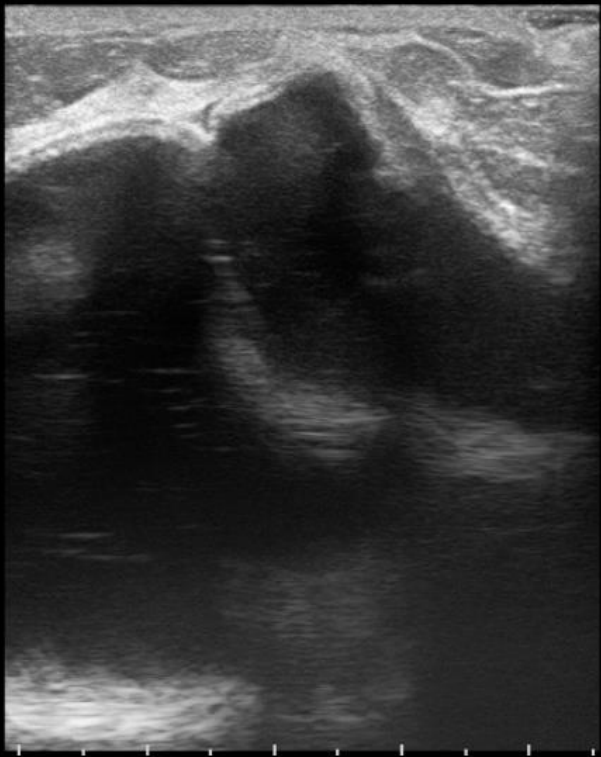
Zoom

Anteprima film Anteprima rapporti Visualizzatore\Vi

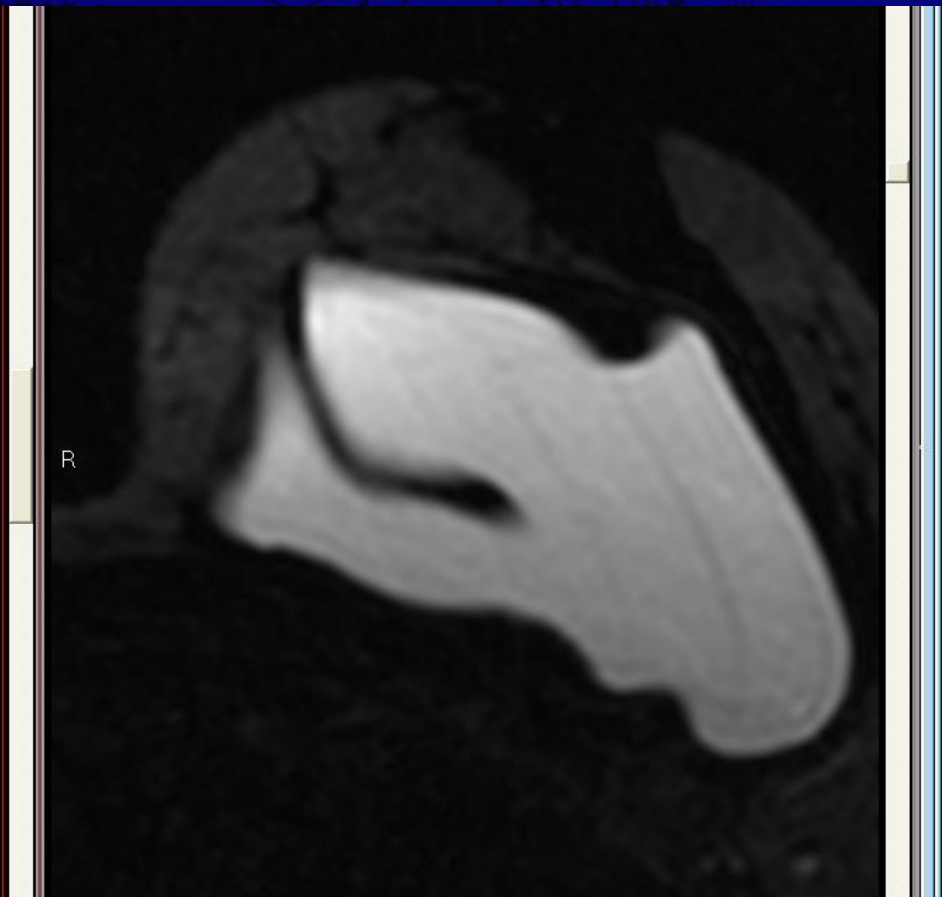
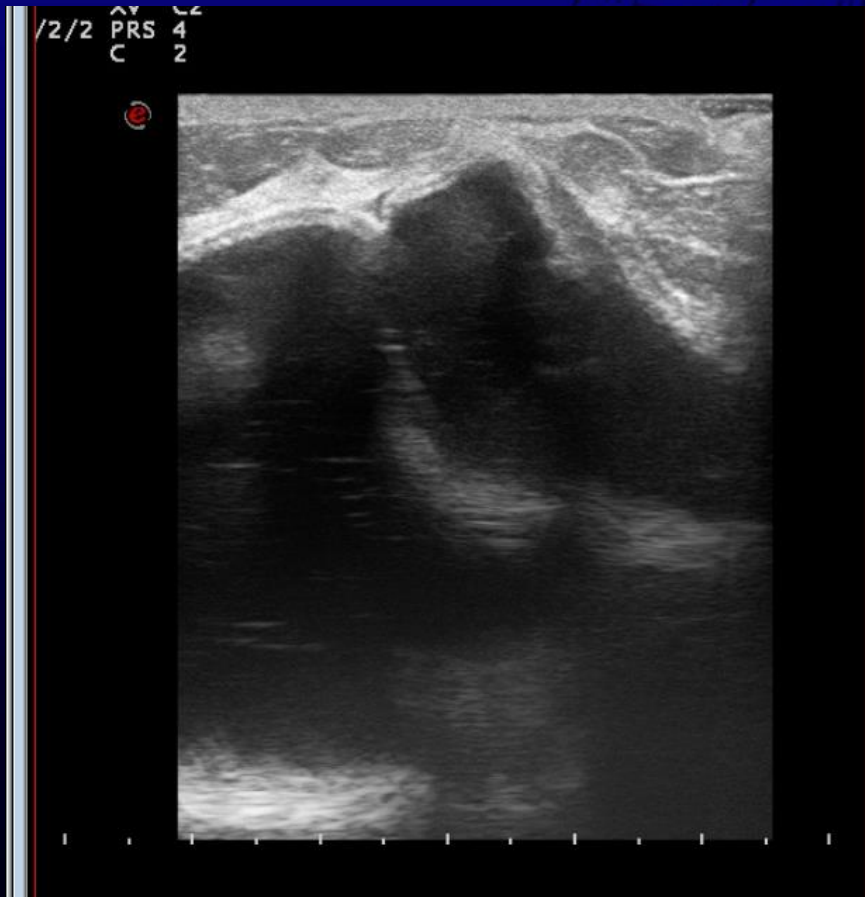

NUM



12/2
PRIS 4
C 2



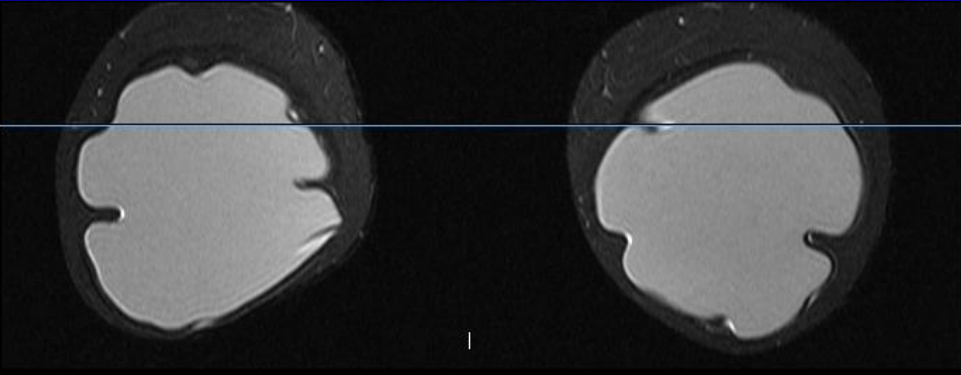
NON ROTTA



< 4 - 16 >

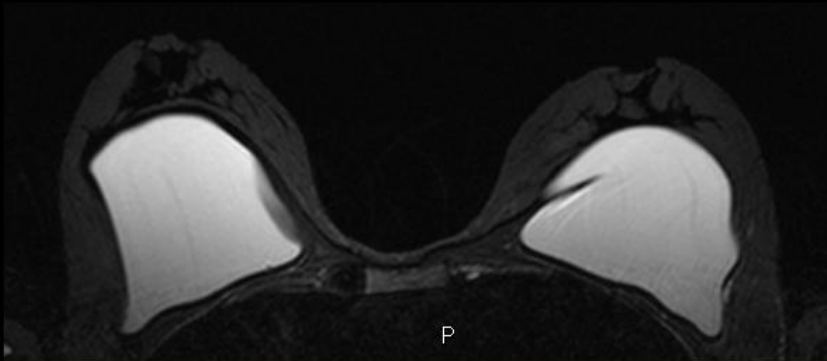
R

36



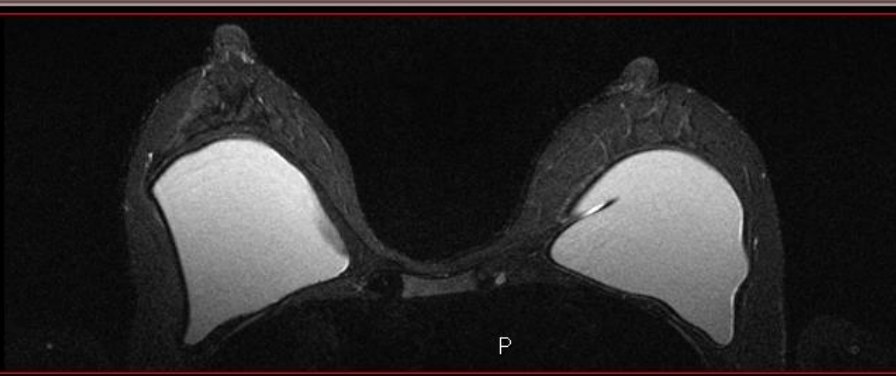< 3 - 24 >

R



< 2 - 36 >

R

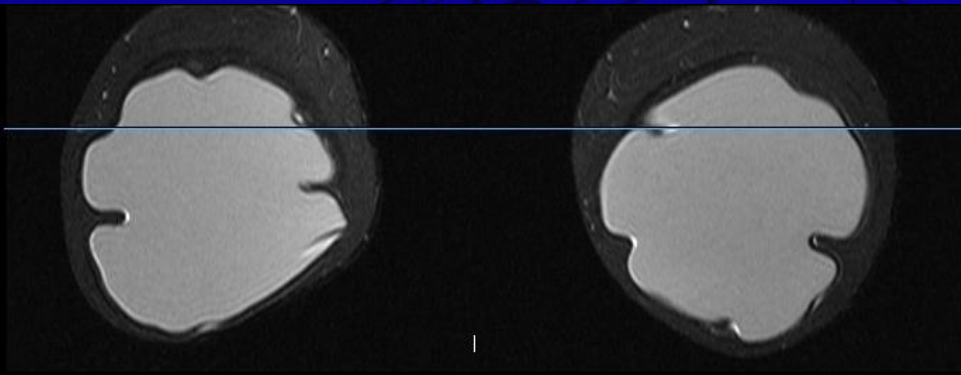


NON ROTTA

< 4 - 16 >

R

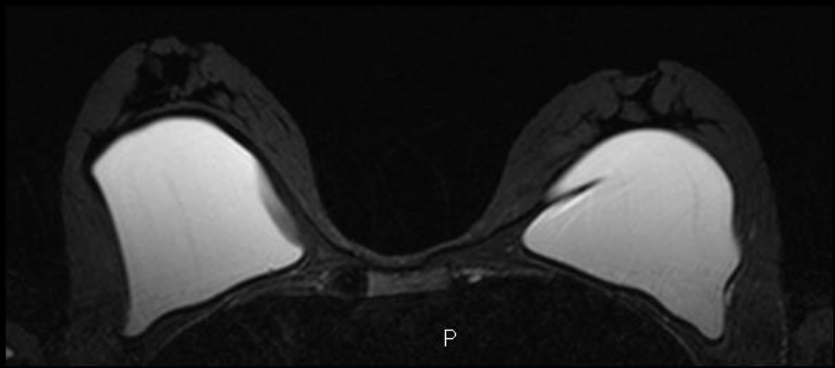
36



< 3 - 24 >

R

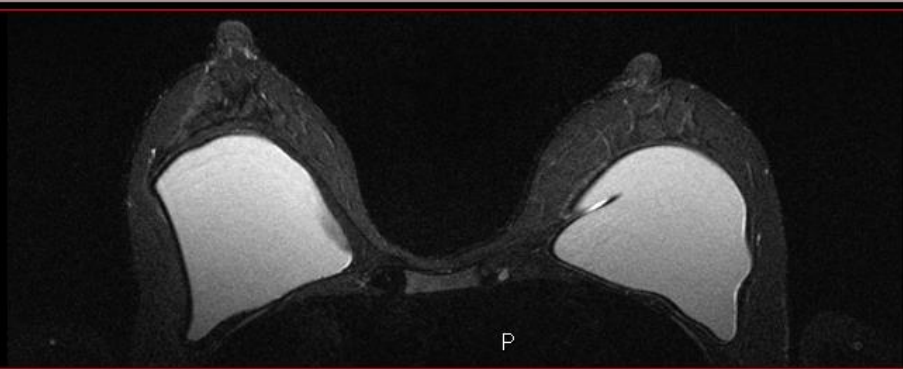
P



< 2 - 36 >

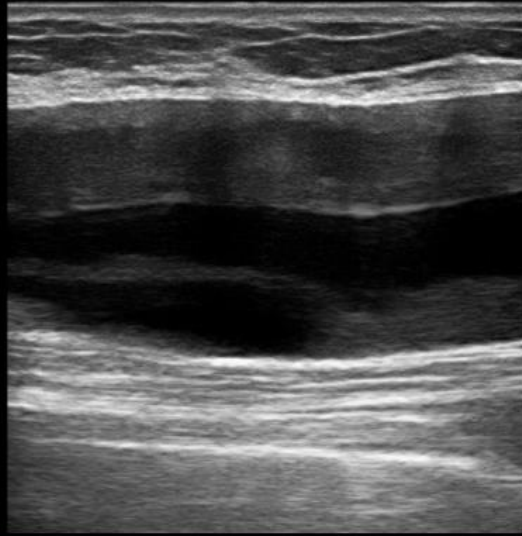
R

P



4 MAMMELLA 13 LA523

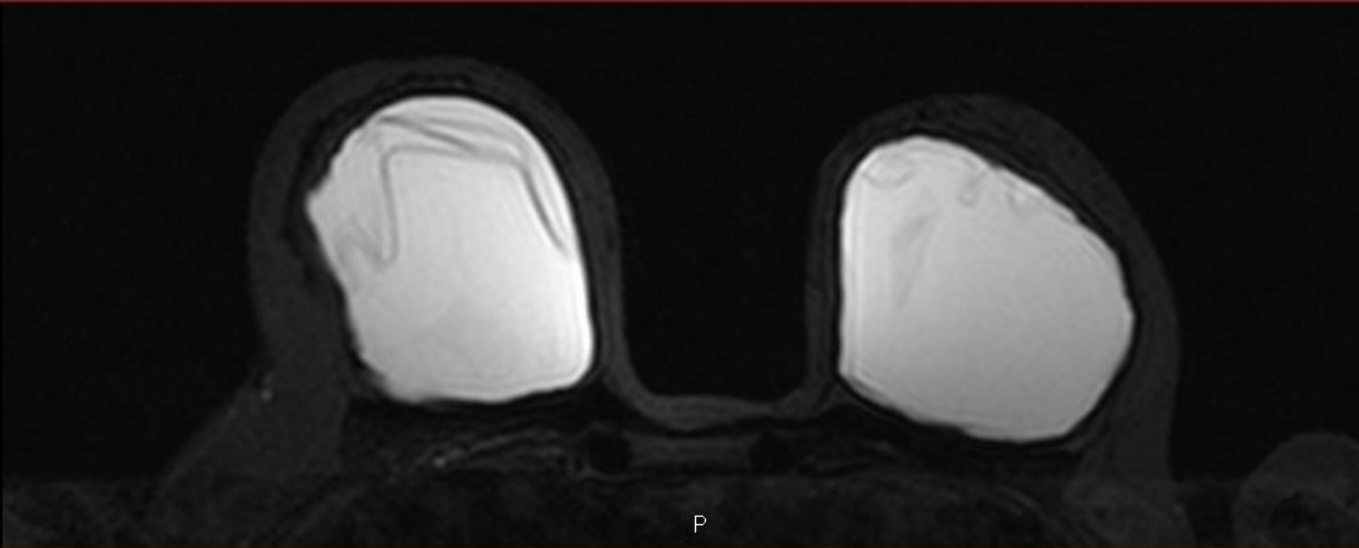
<1-1>



0
1
2
3
4
5

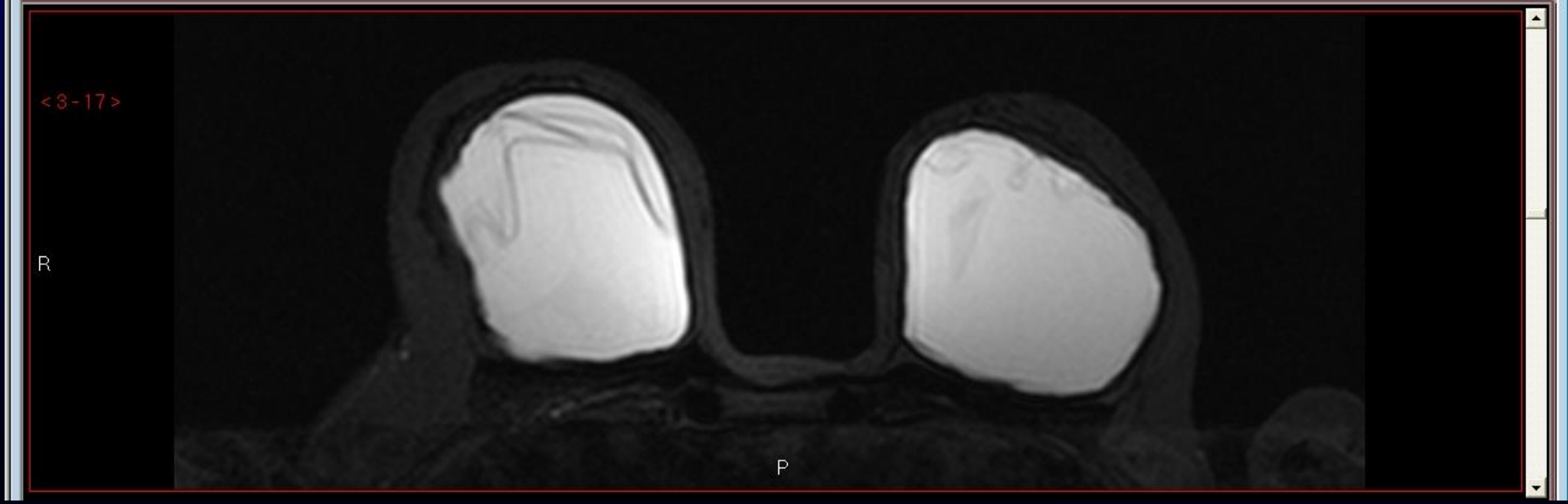
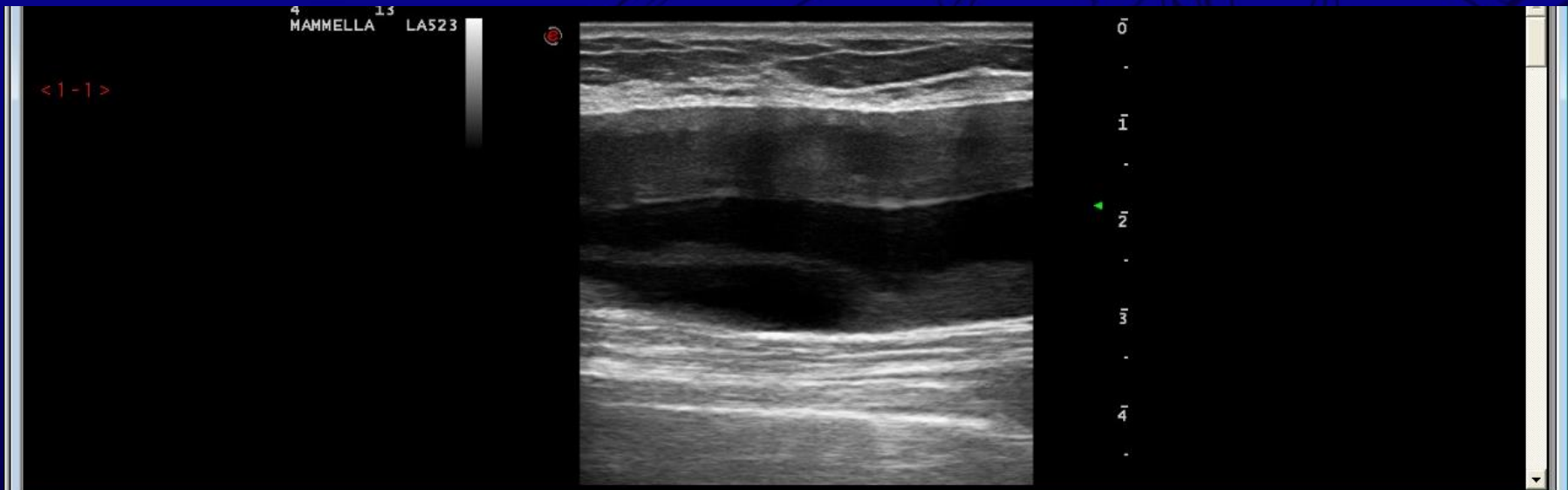
<8-17>

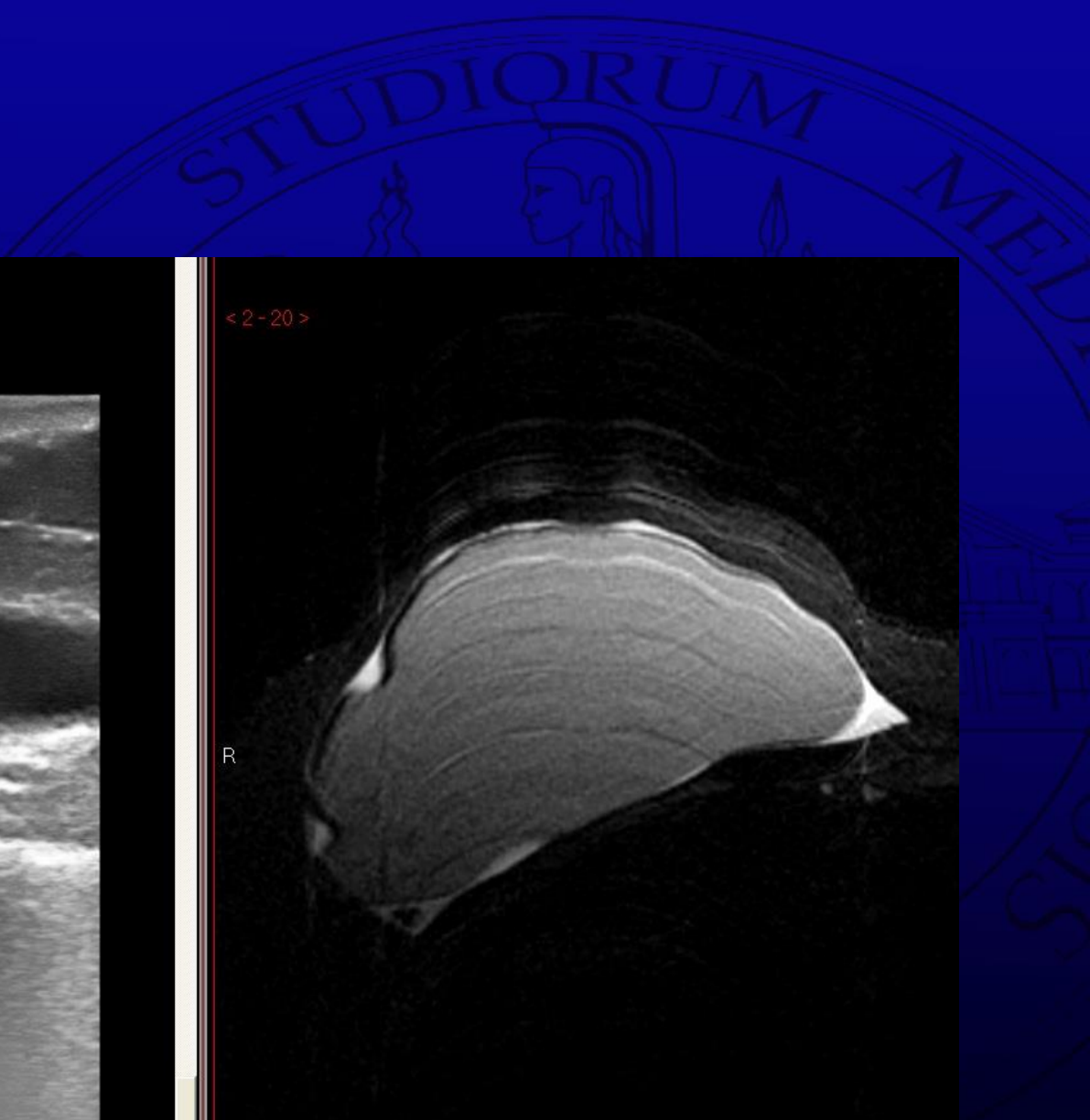
R



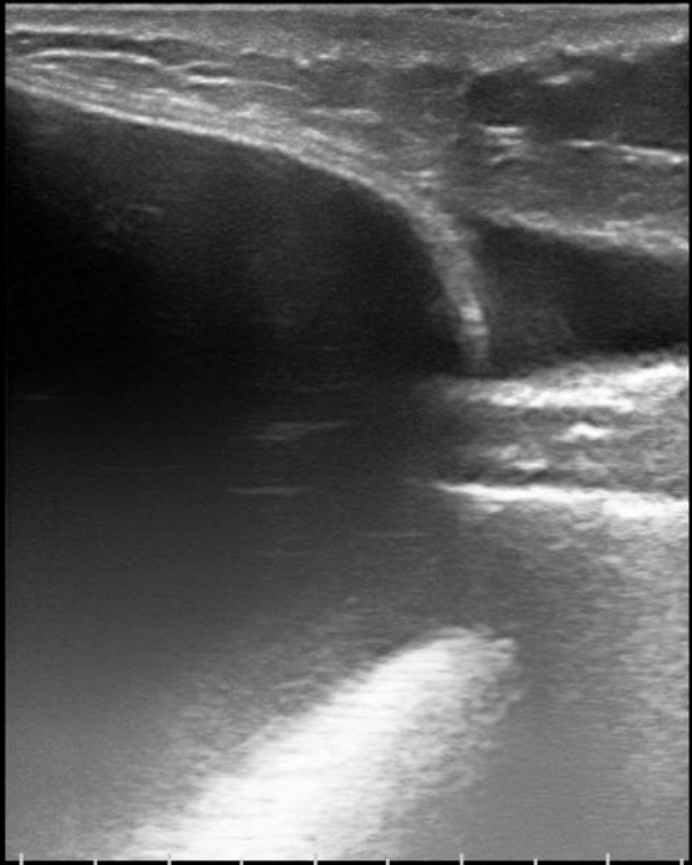
P

ROTTA



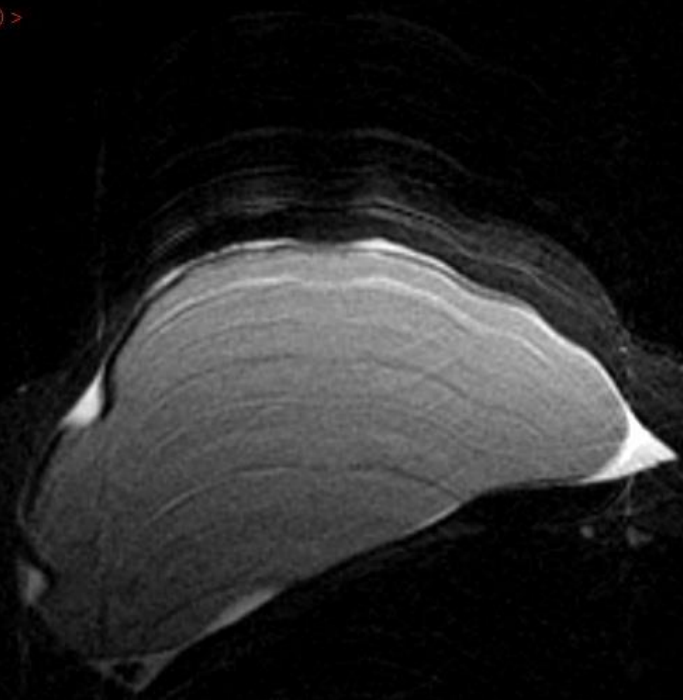


G 98%
KV C3
PRS 4+
C 0



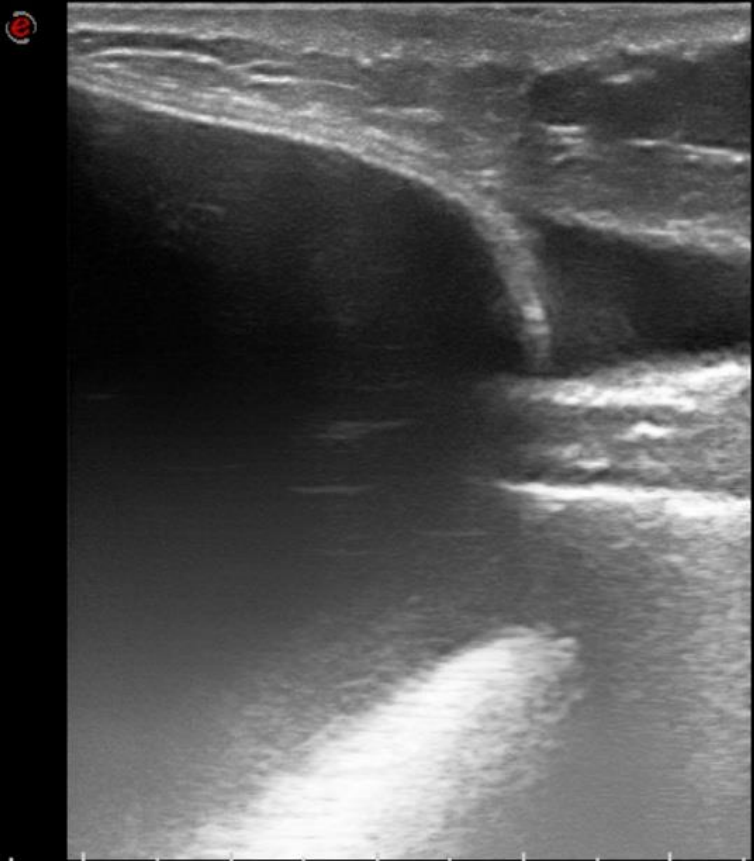
< 2 - 20 >

R



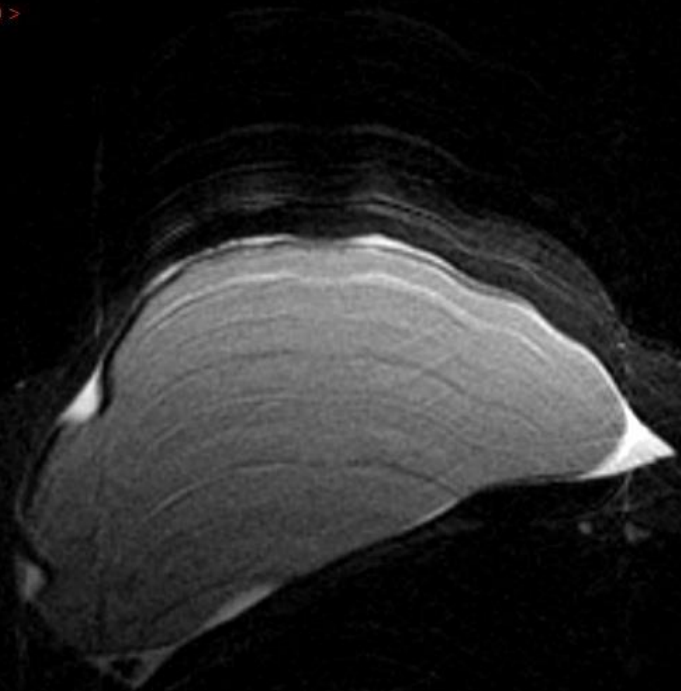
NON ROTTA

G 98%
KV C3
PRS 4+
C 0



< 2-20 >

R



Caso S1

The background features a large, faint watermark of the University of Melbourne seal. The seal is circular and contains the Latin text 'UNIVERSITAS STUDIORUM MELBOURNENSIS' around the perimeter. In the center of the seal is a figure, likely a personification of Wisdom or Truth, holding a torch in one hand and a book in the other. The figure is surrounded by architectural elements, including a building and a tree.



23aa.

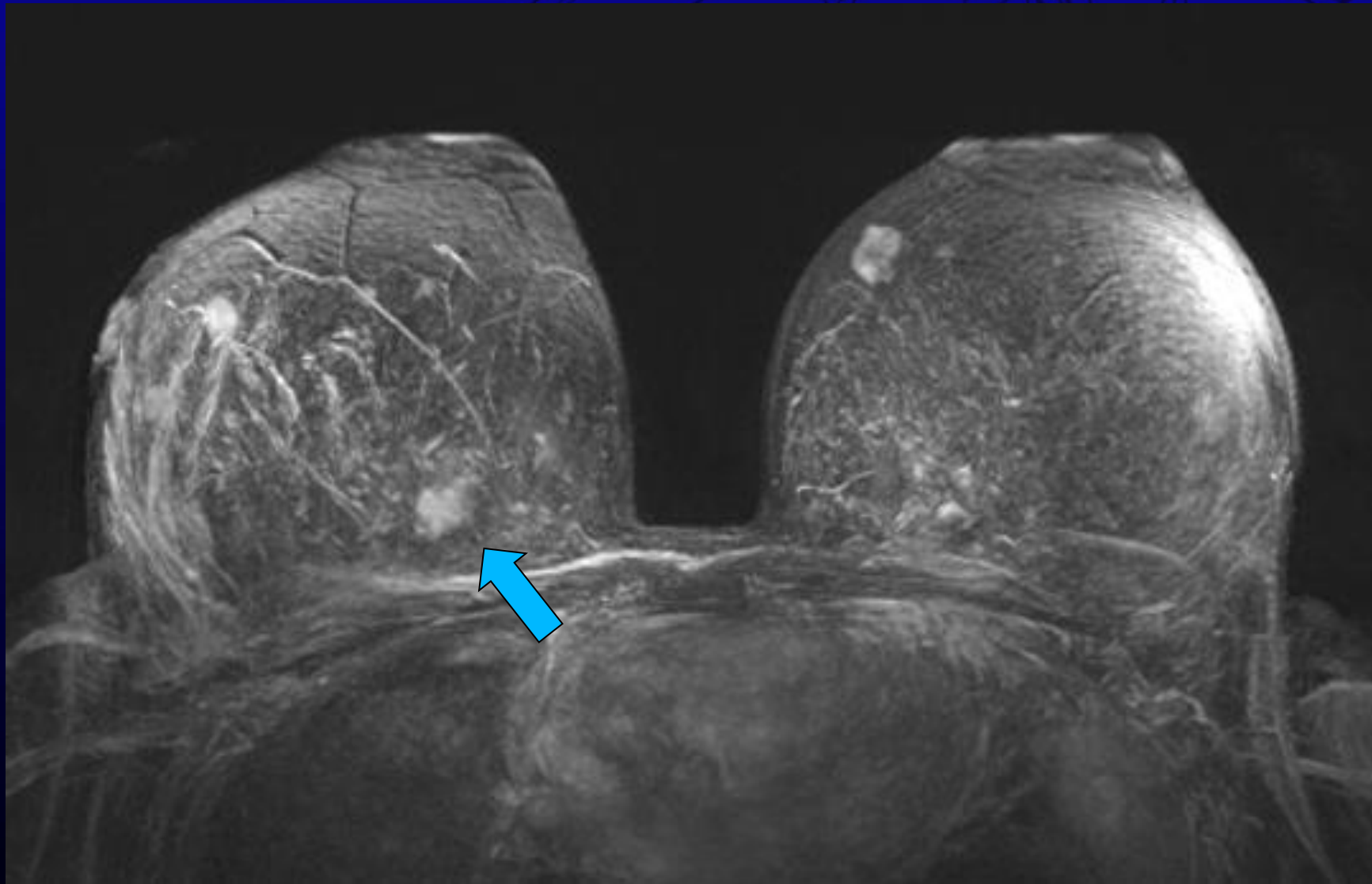
Progressa exeresi fibroadenoma destro di 4cm.

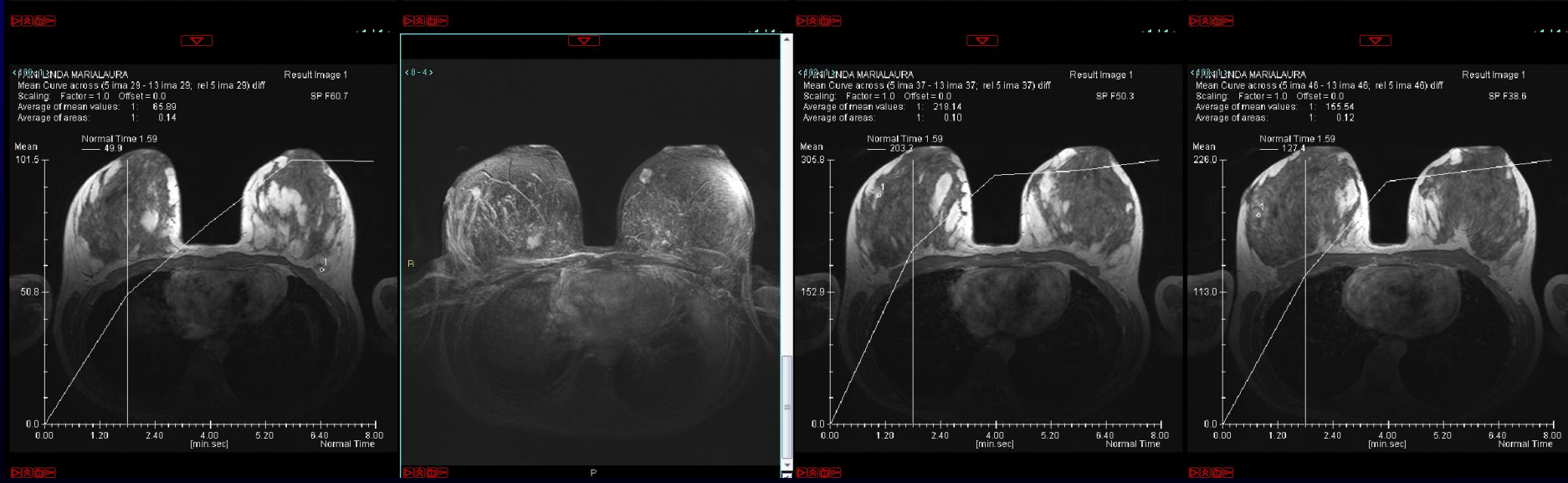
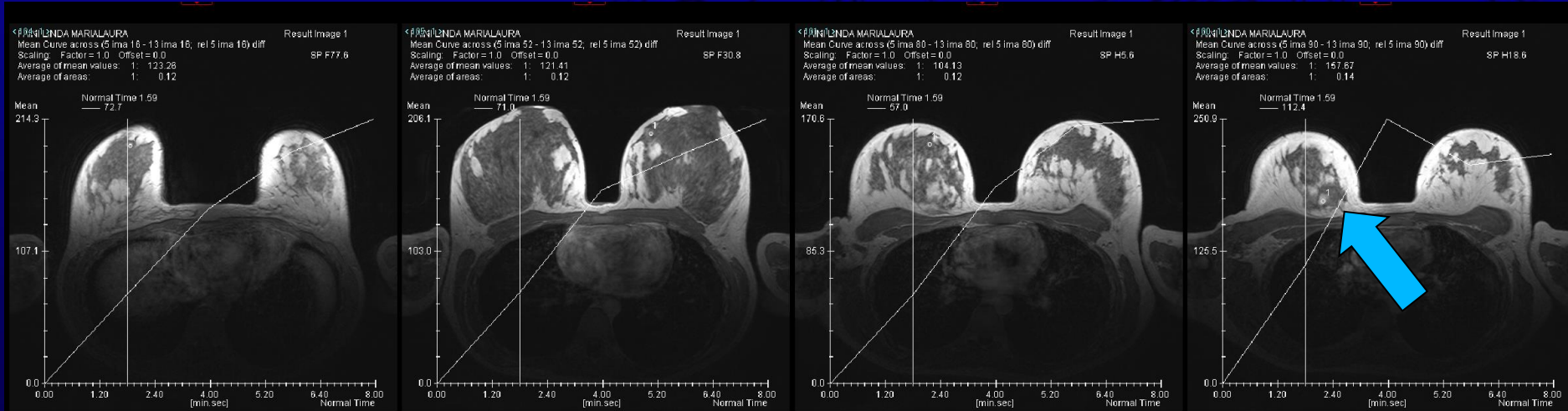
Familiarità (zia materna e paterna a 50aa)

Controllo di nodulo aumentato dimensionalmente al QSI

Richiesta non indicata!

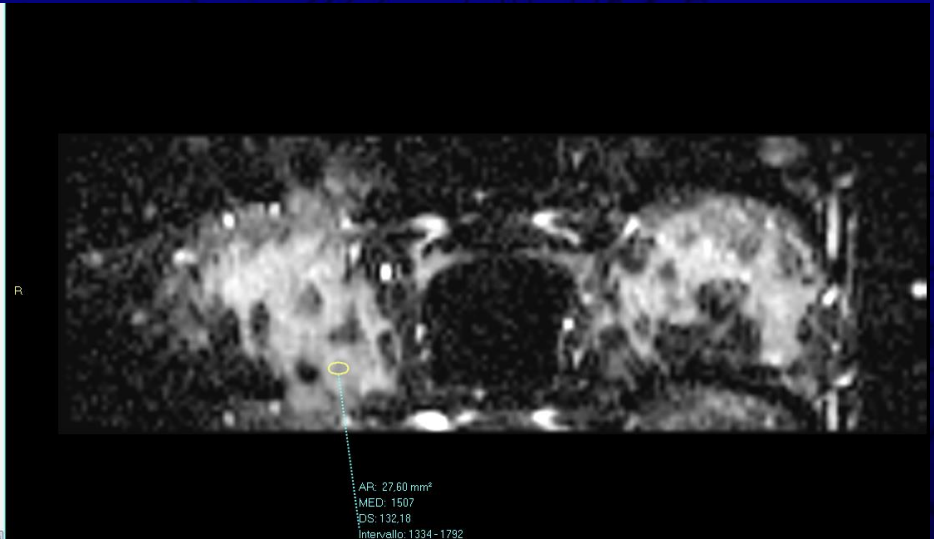
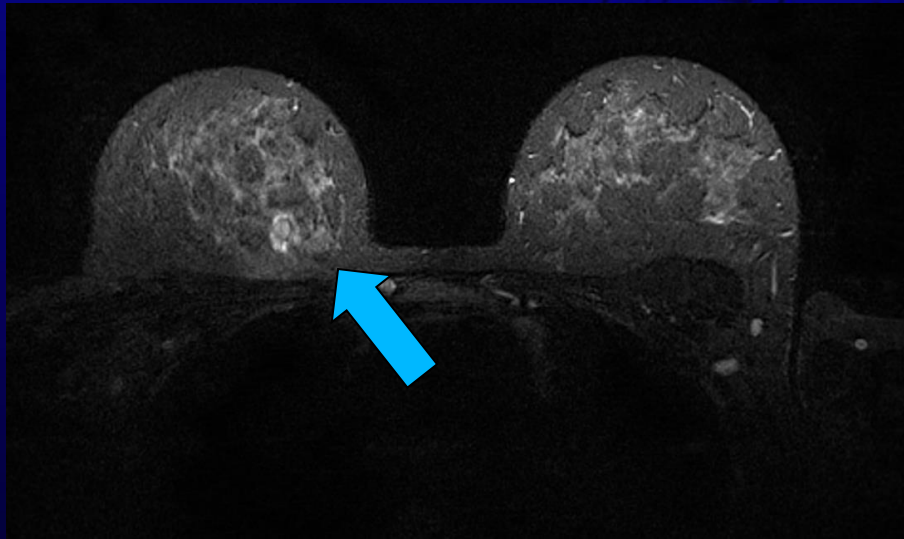
Maximum intensity projection I T1 sottratta





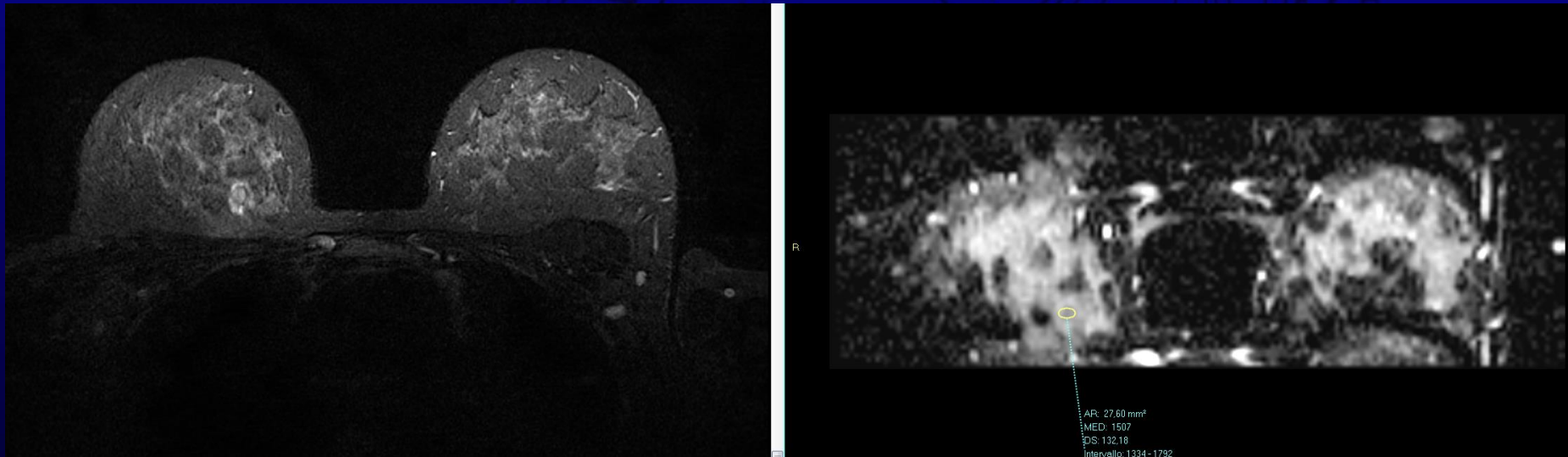
STIR

Mappa ADC
= elevati valori



STIR

Mappa ADC



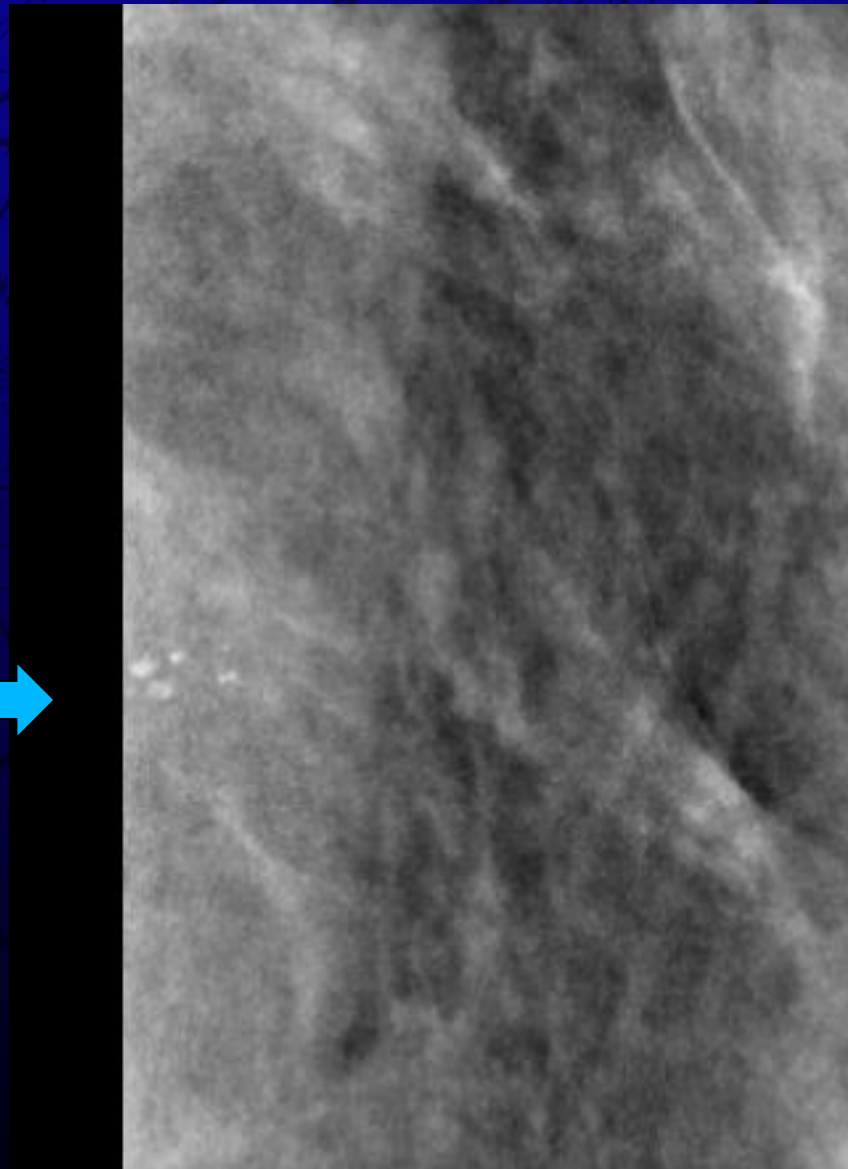
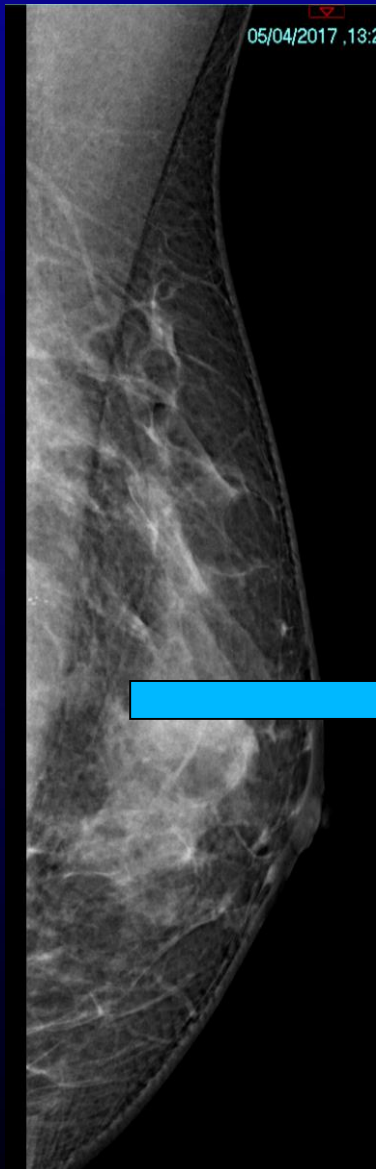
- *Lesioni benigne bilaterali*
- *Formazione probabilmente benigna a destra, verosimile fibroadenoma proliferativo (mixoide)*
- *In considerazione del riferito incremento dimensionale si consiglia agobiopsia se in previsione exeresi chirurgica (BI-RADS 3)*

Caso B1



43 aa.

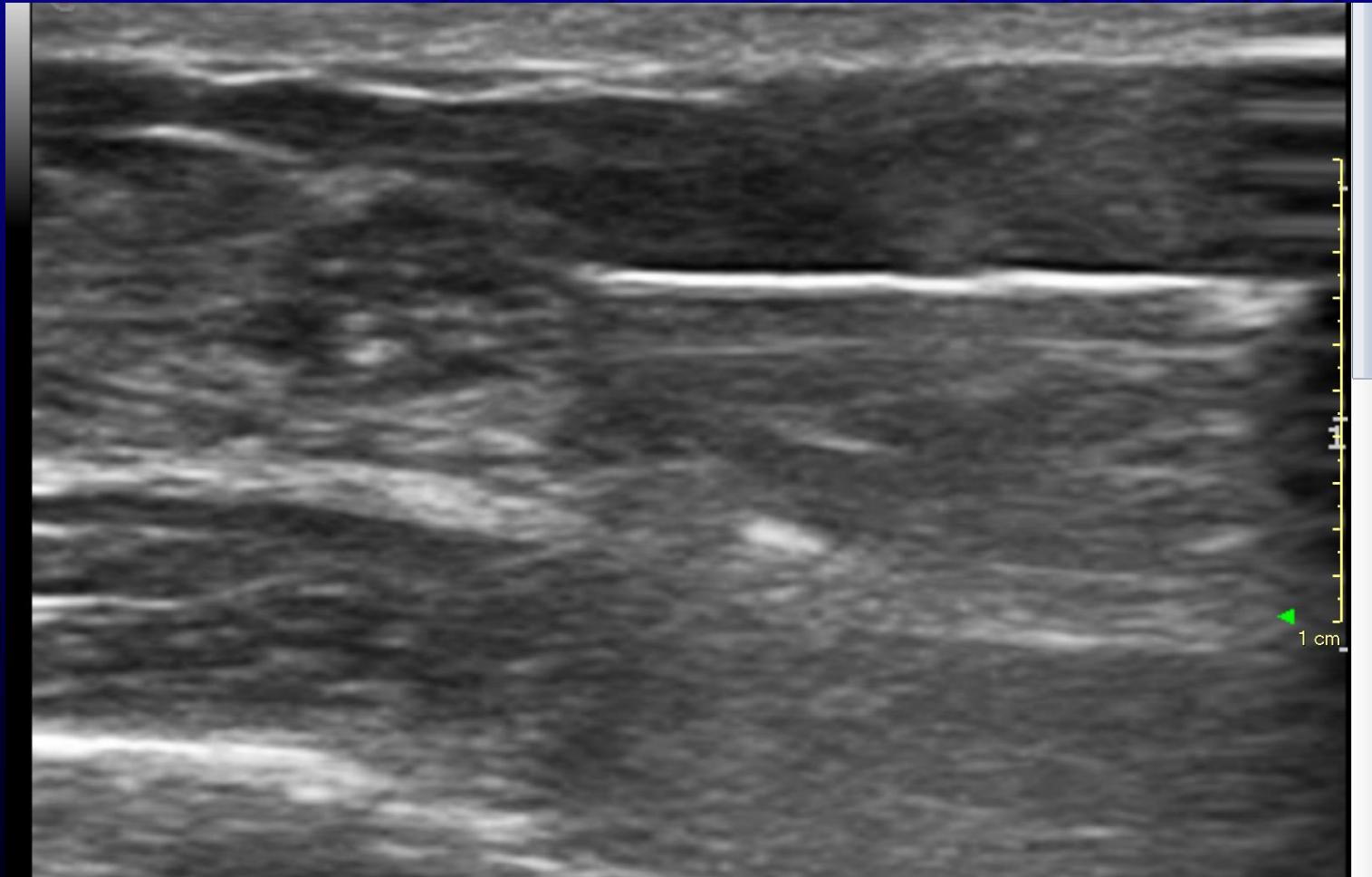
Micro nuova insorgenza prepettorali esterne

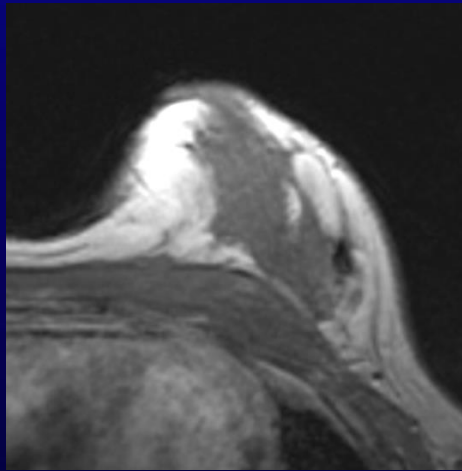


43 aa.

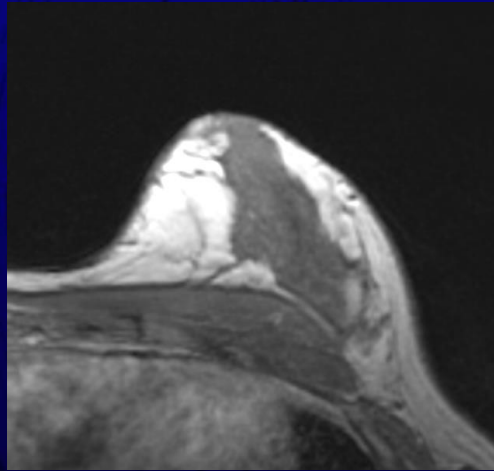
Micro nuova insorgenza prepettorali esterne

Bio eco trucut = ADH

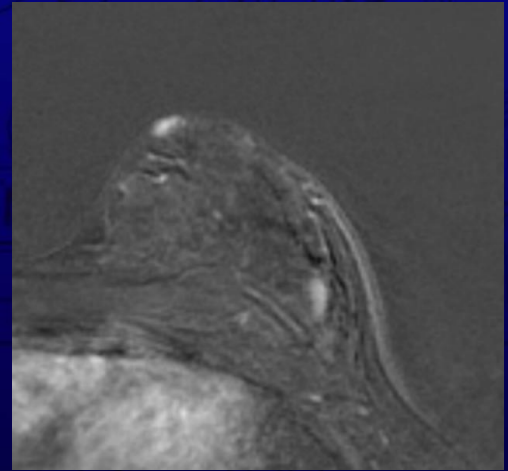




T1 pre

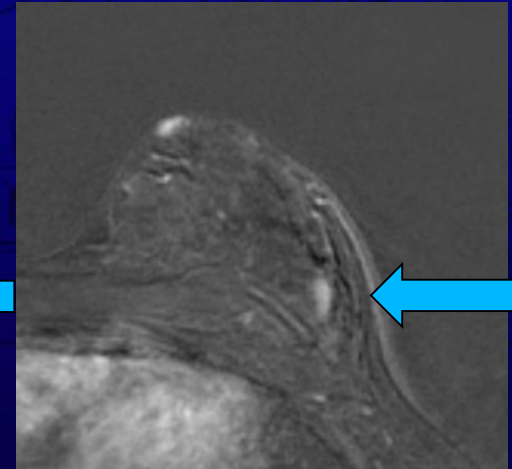
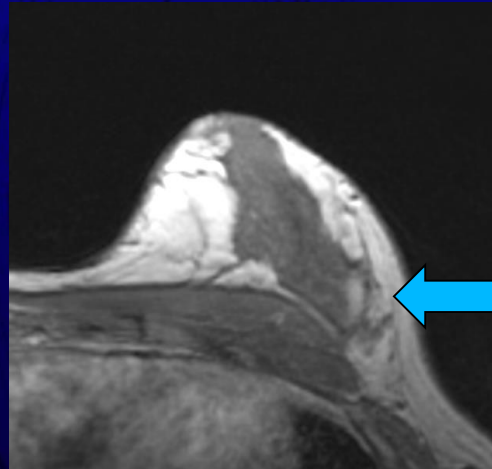
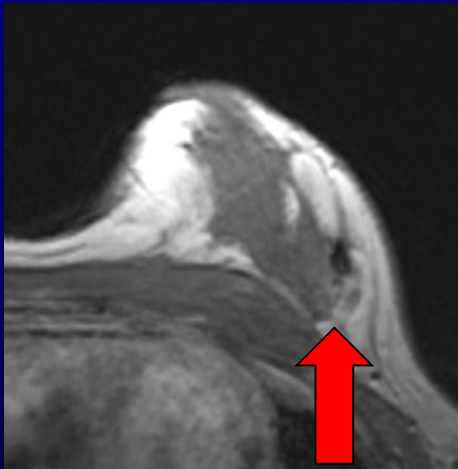


T1 post



T1 sub

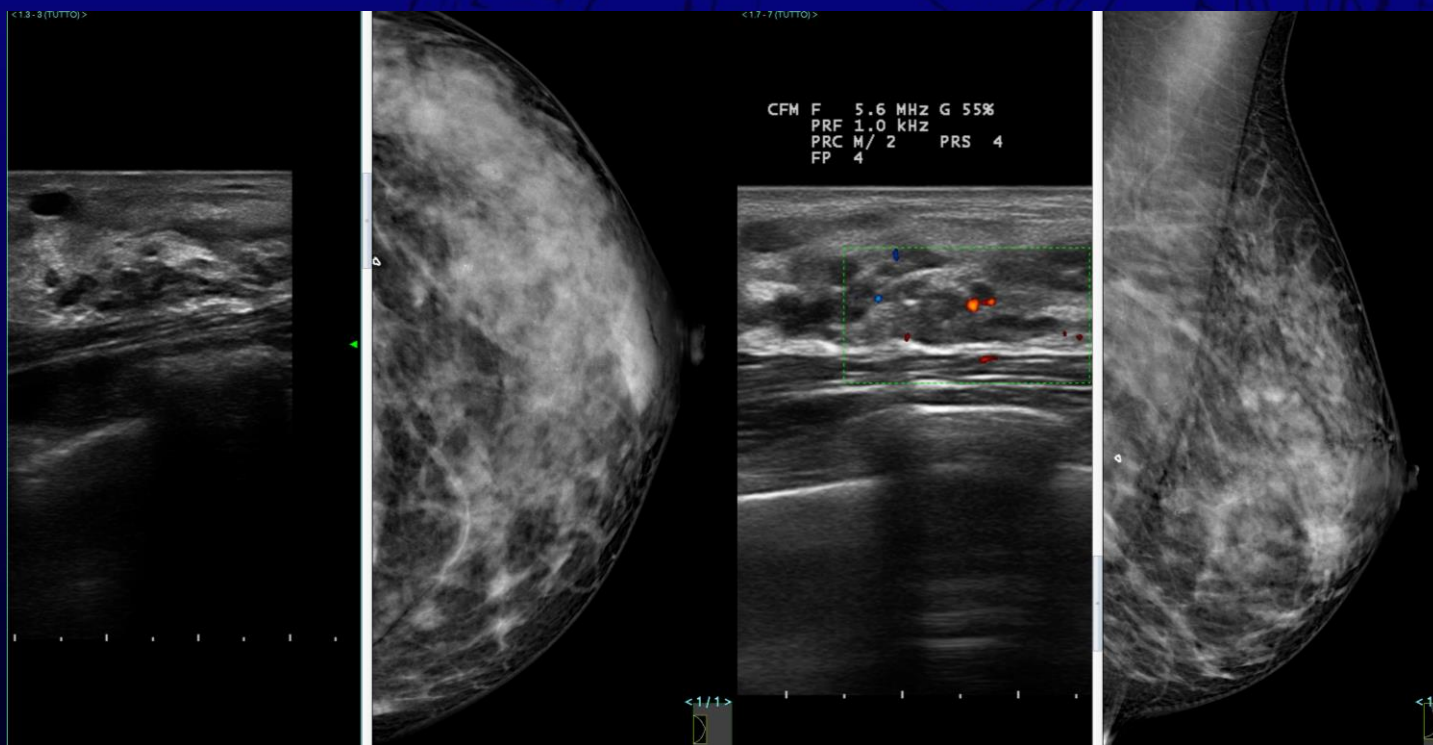
RM= *ematoma* e accanto *lesione non mass* con c.e. di 10mm
BI-RADS 4
Chirurgia DCIS alto grado



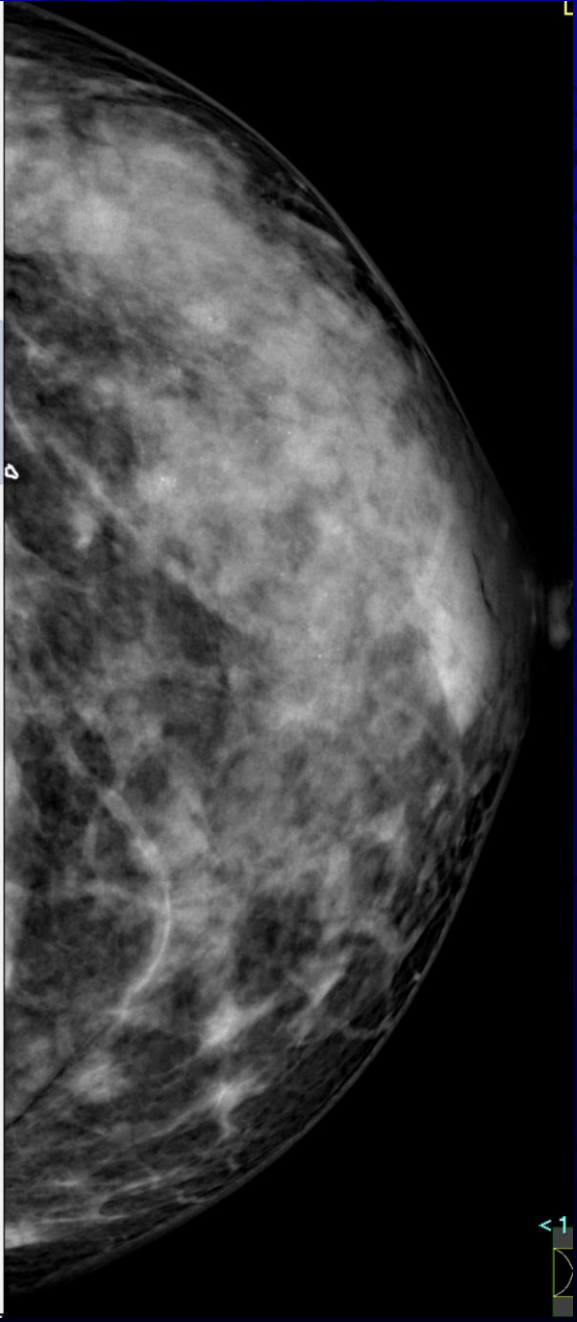
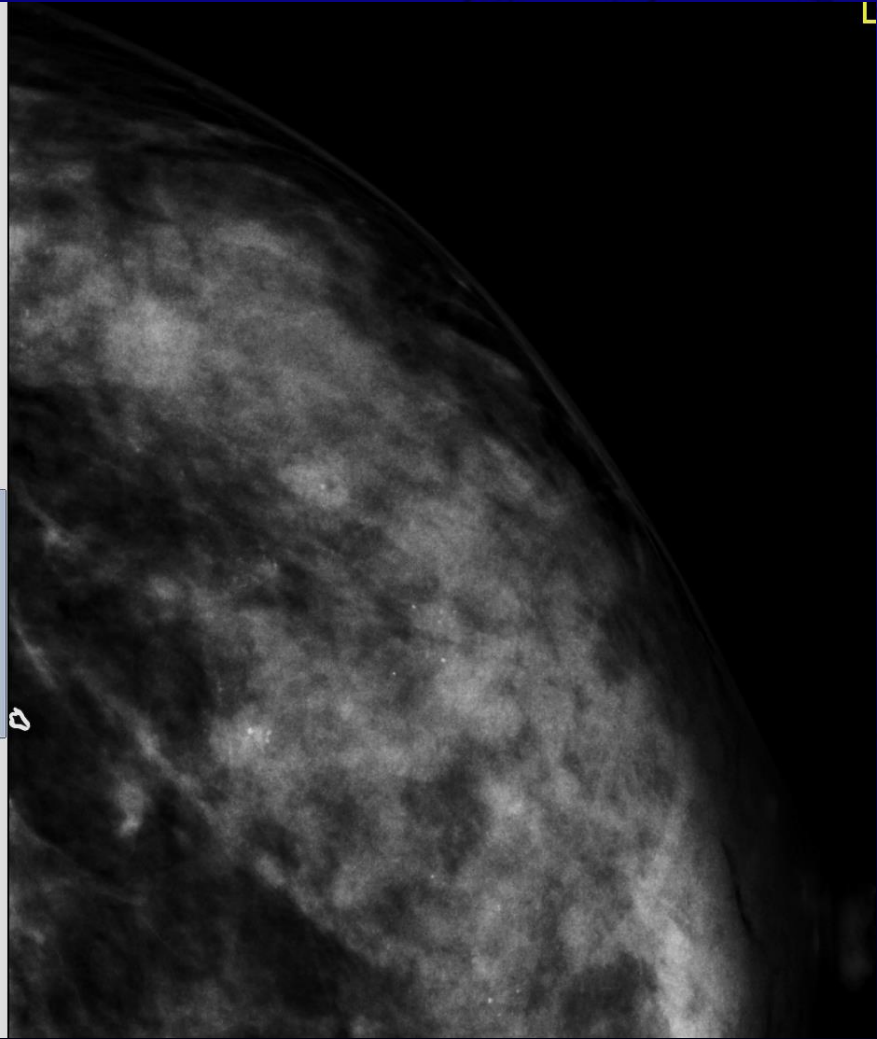Caso B2



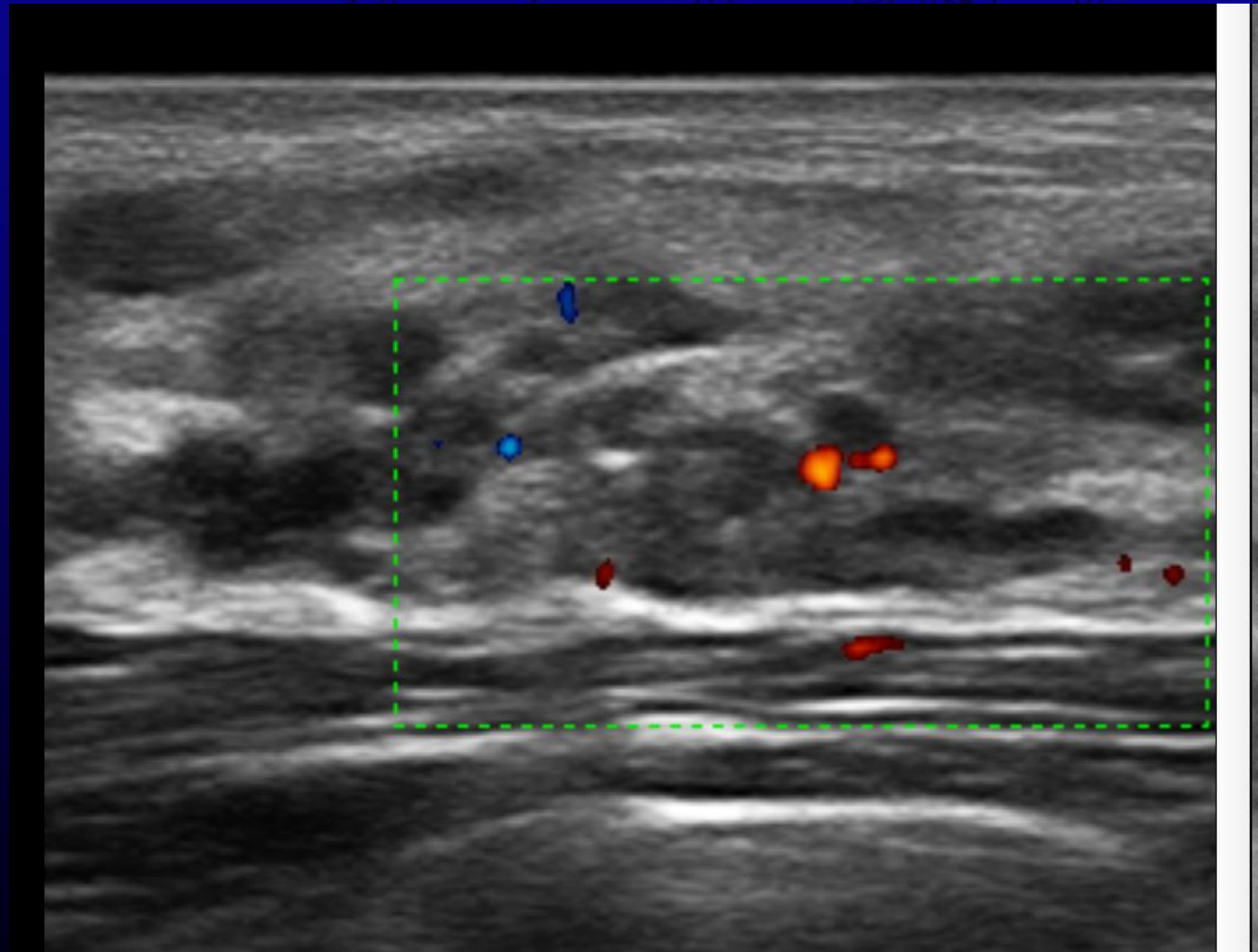
45aa
Progressiva exeresi papilloma a sinistra.
Asintomatica



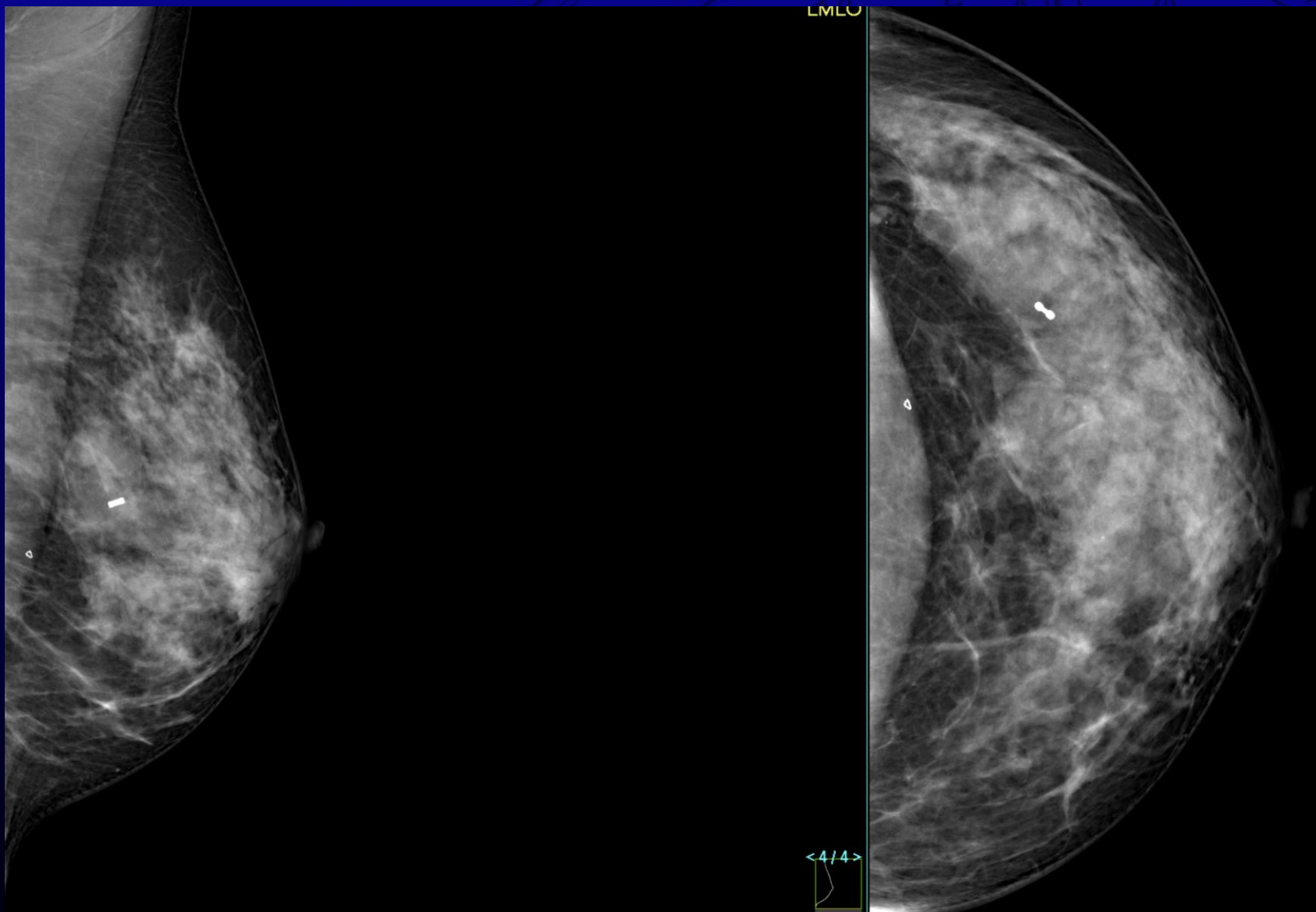
Microcalcificazioni ai QQEE di sinistra



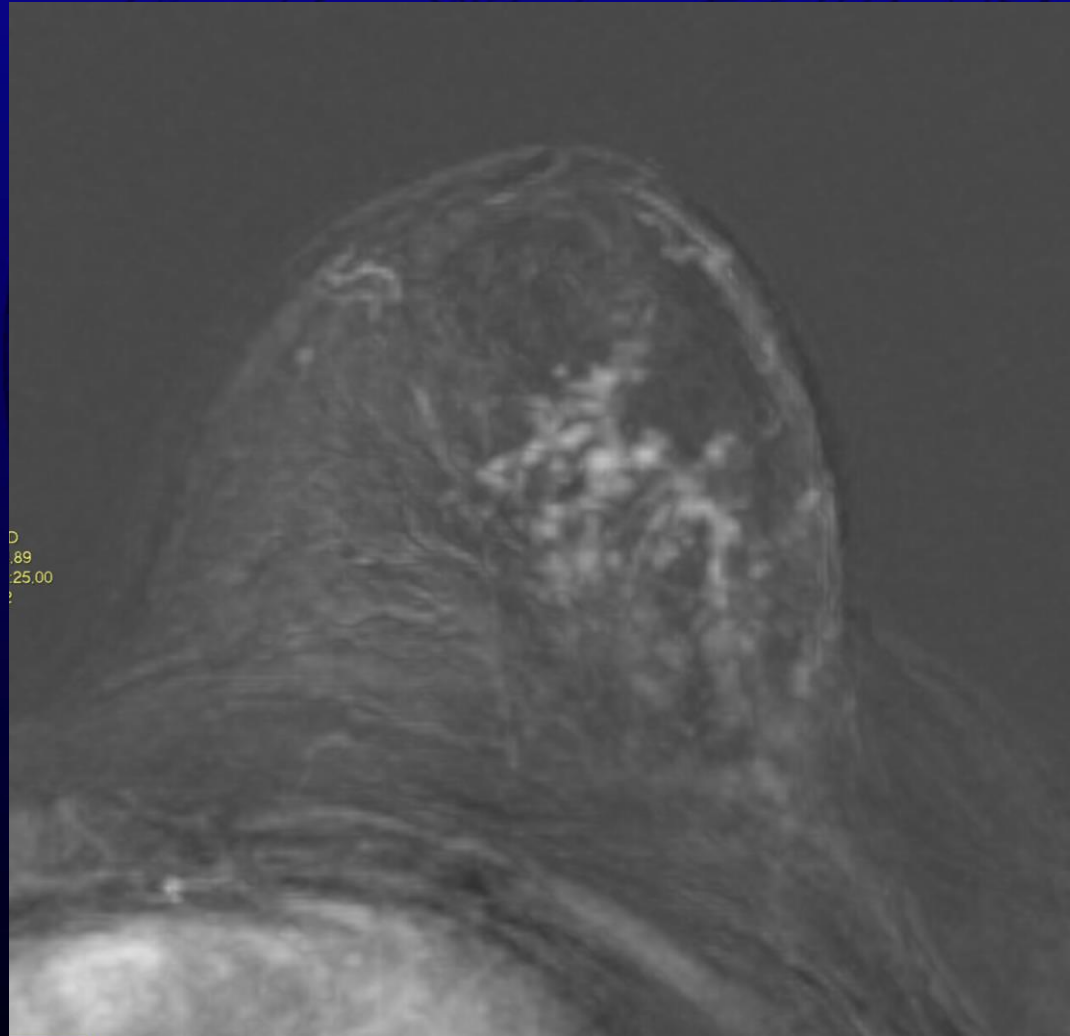
Minime e diffuse alterazioni intraduttali all'ecografia



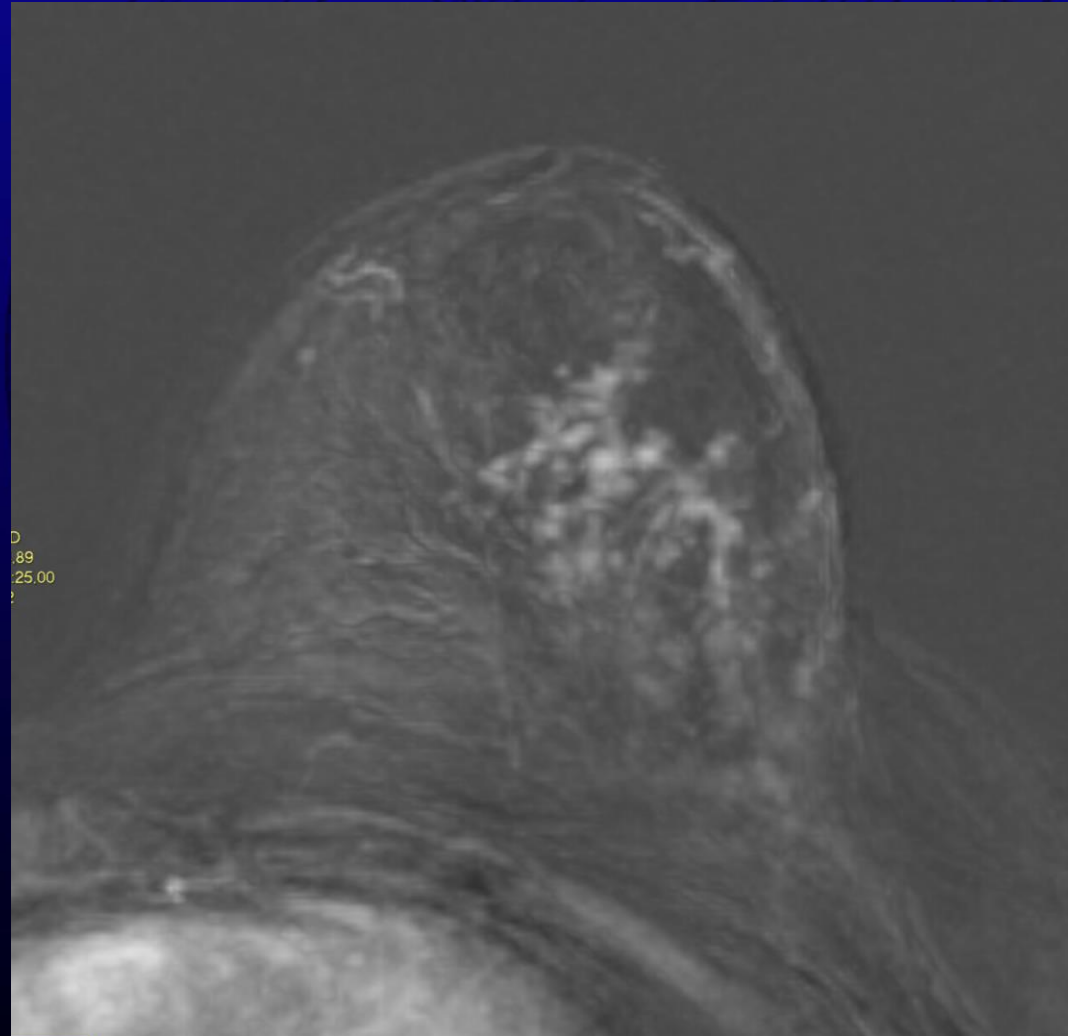
bio multiple papillomatosi B3



RM – Sequenza T1 post sottratta



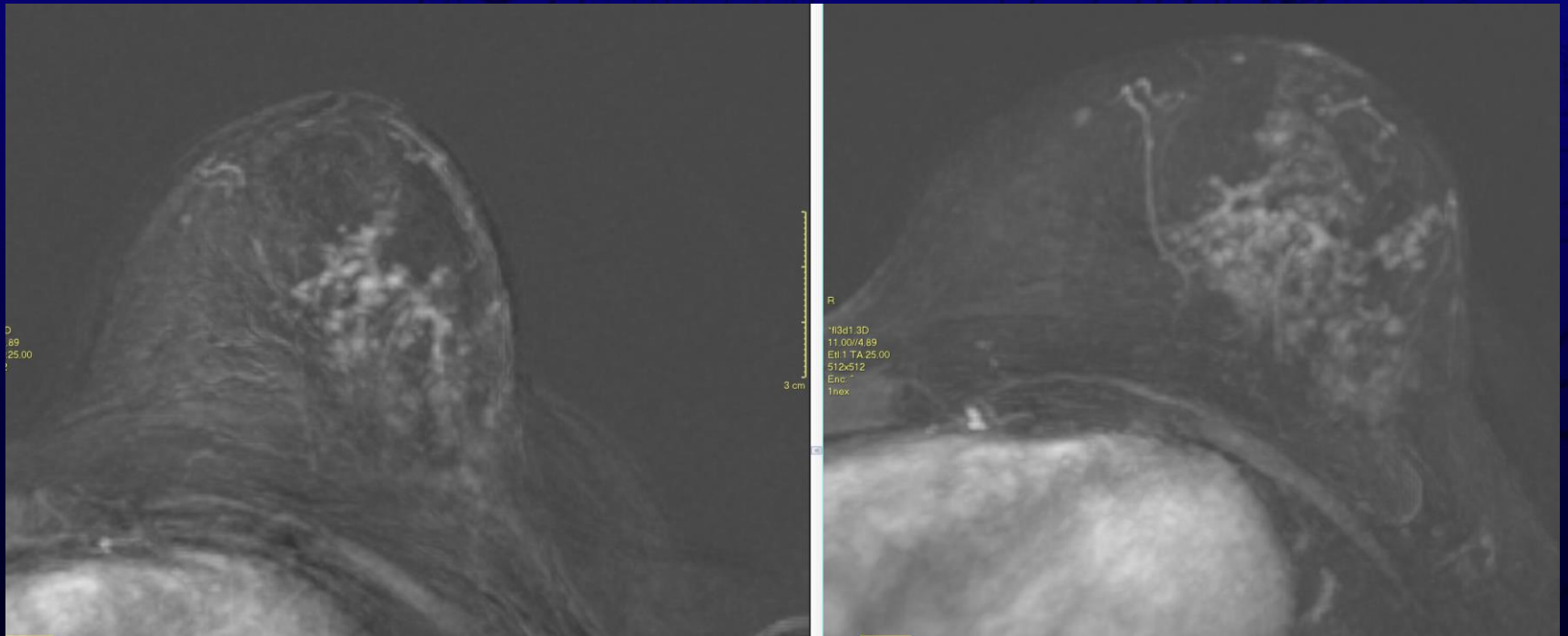
Non mass enhancement segmentale al QIE



Non mass con aumento di estensione

2013

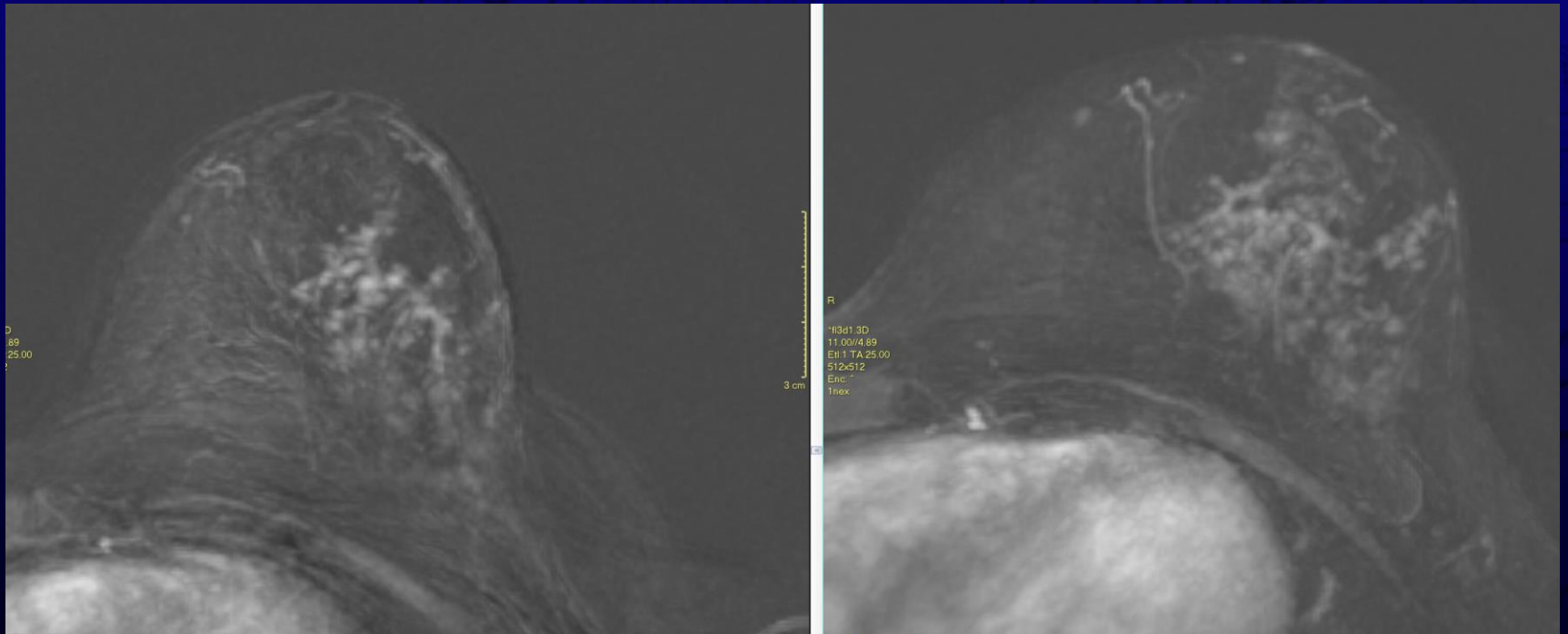
2016



Non mass con aumento di estensione

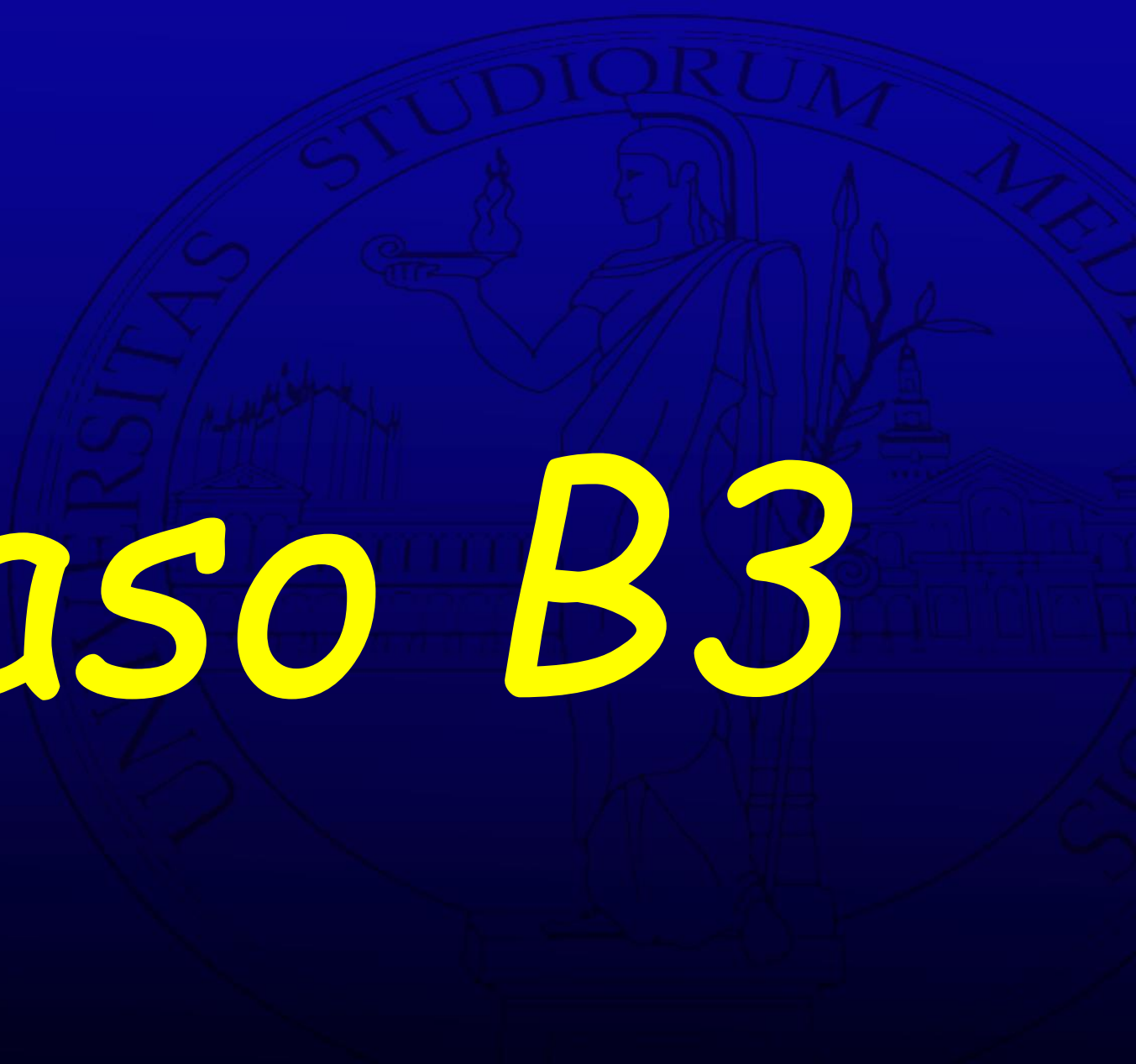
2013

2016



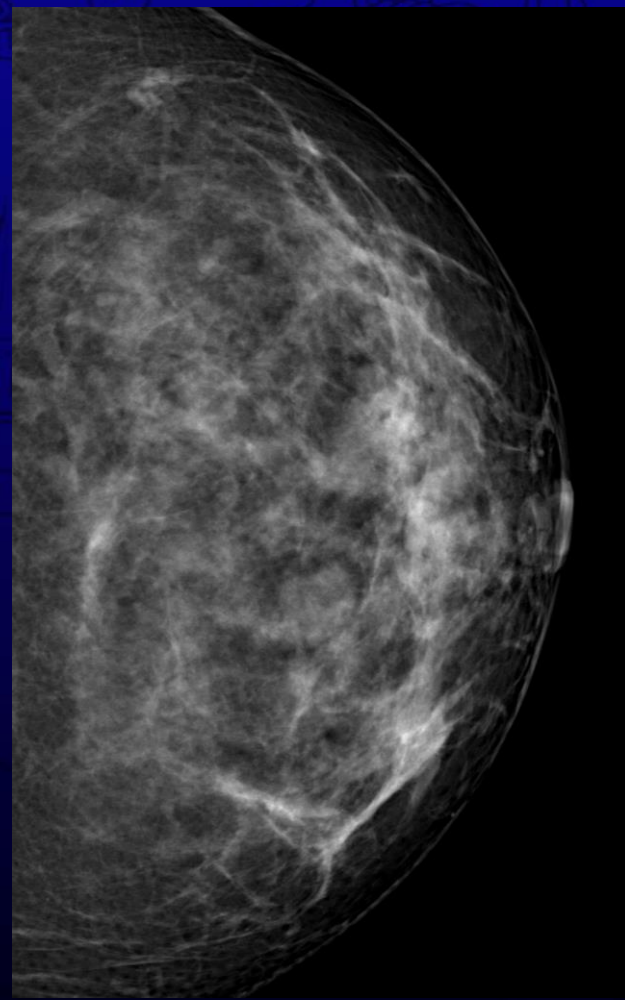
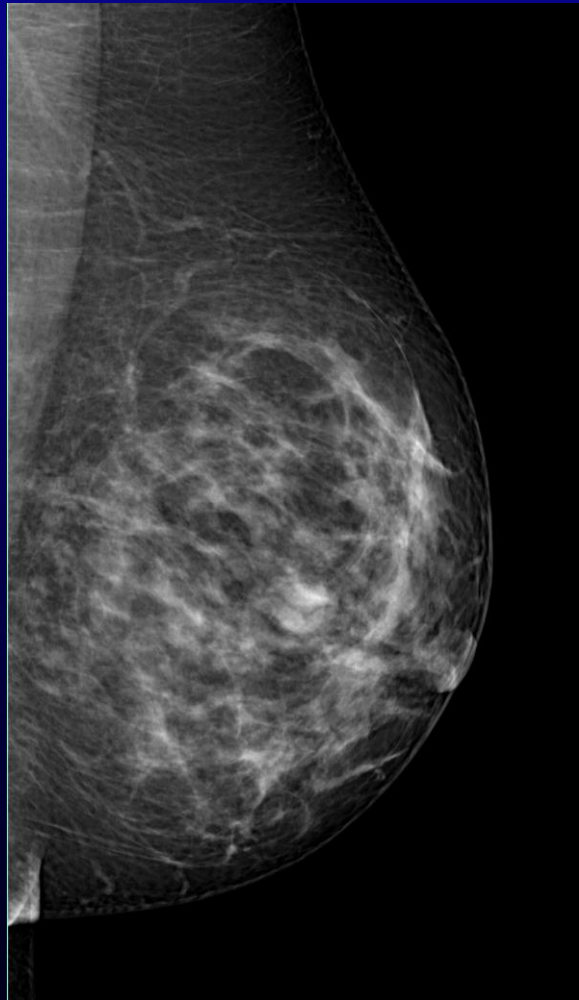
chir = LIN1, ADH, papillomi

Caso B3

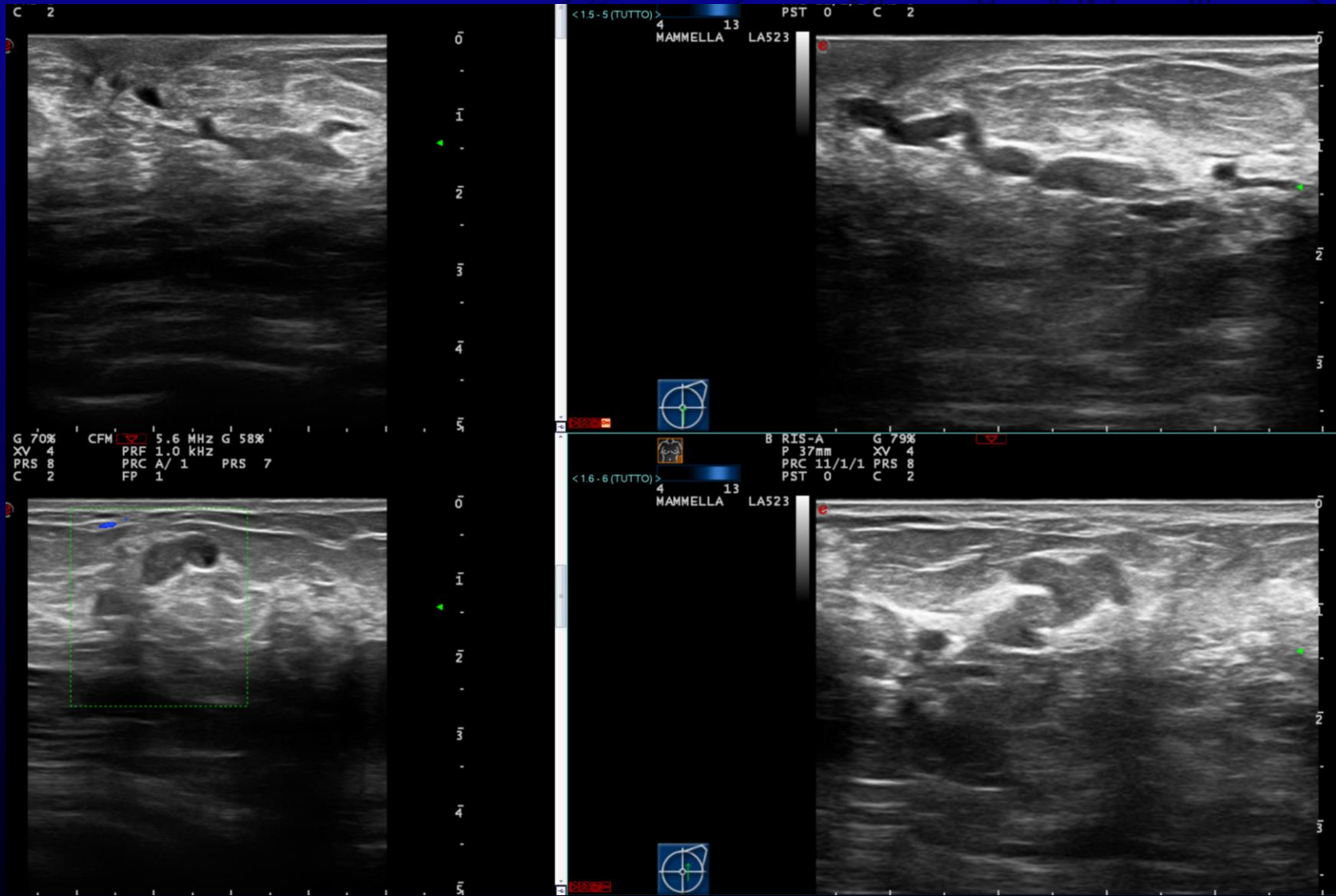


49 aa.

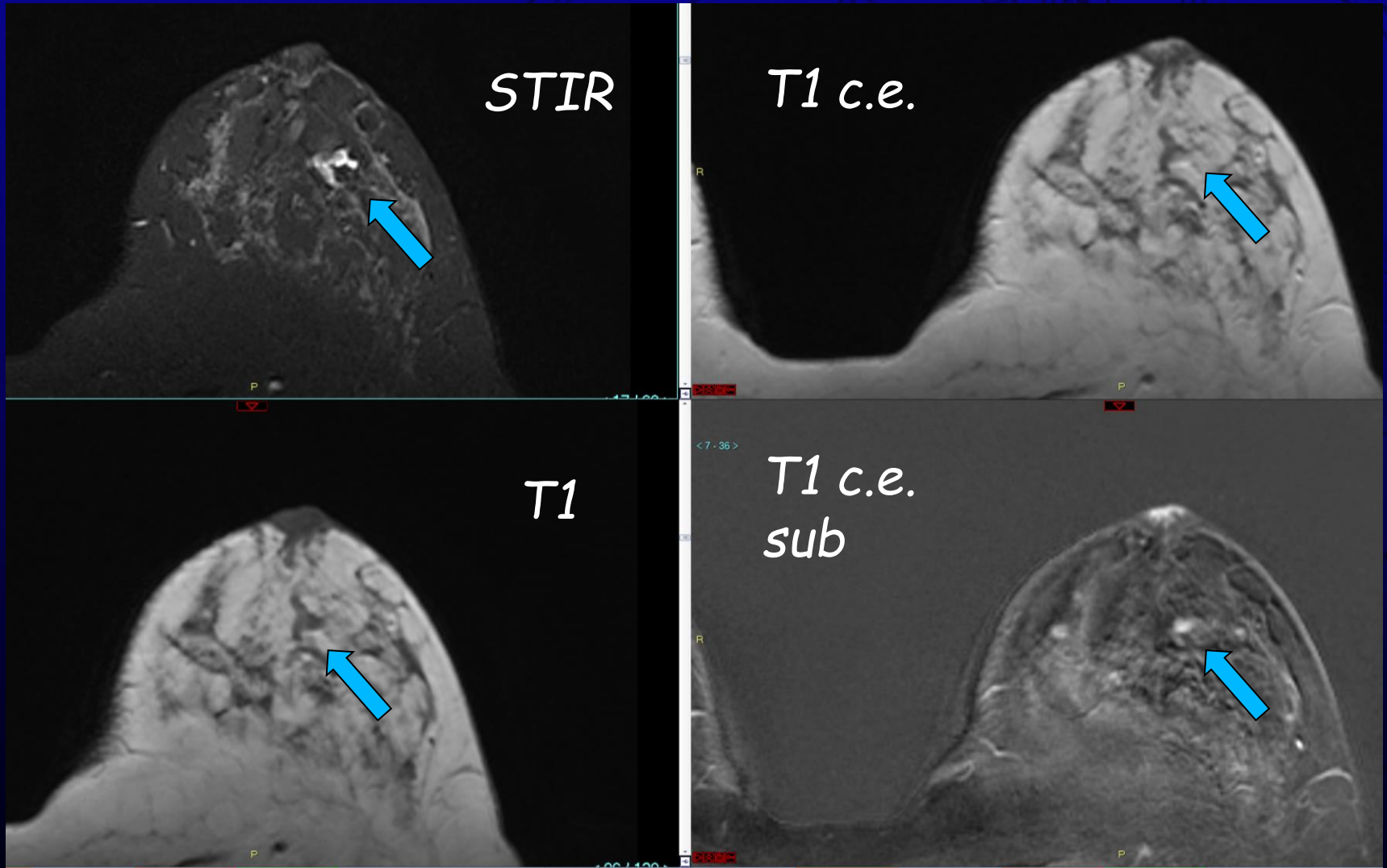
Secrezione monolaterale monorifiziale siero-ematica sinistra

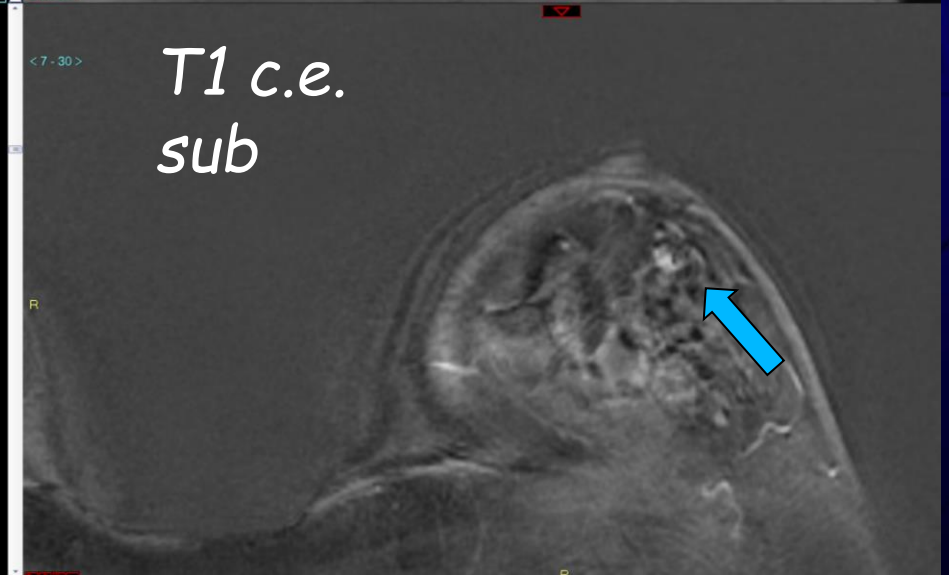
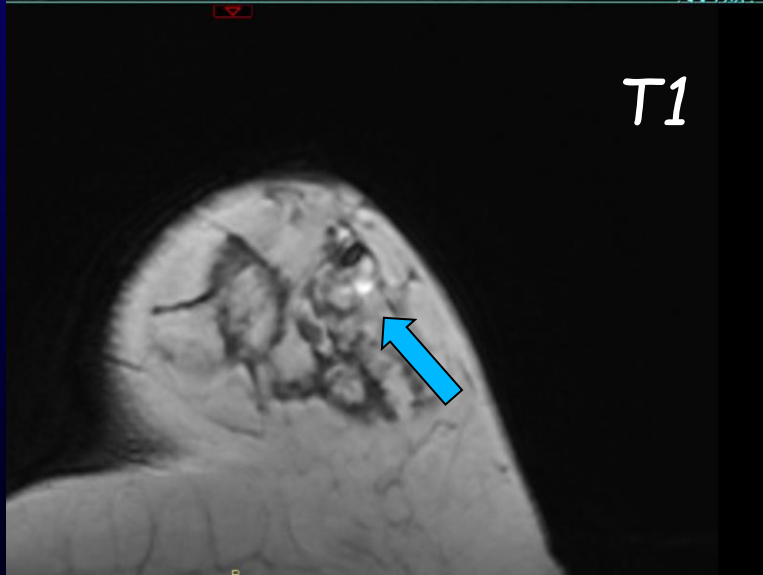
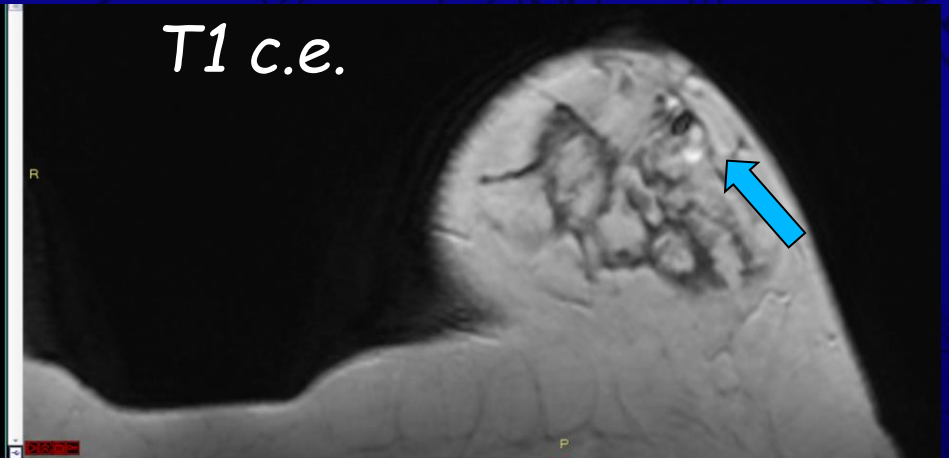
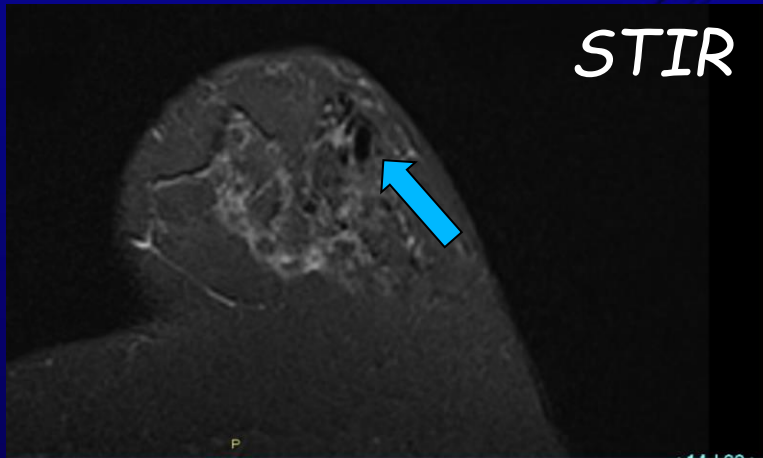


*Plurime alterazioni intraduttali;
bio eco = papilloma*



RM per valutazione estensione malattia in previsione di exeresi

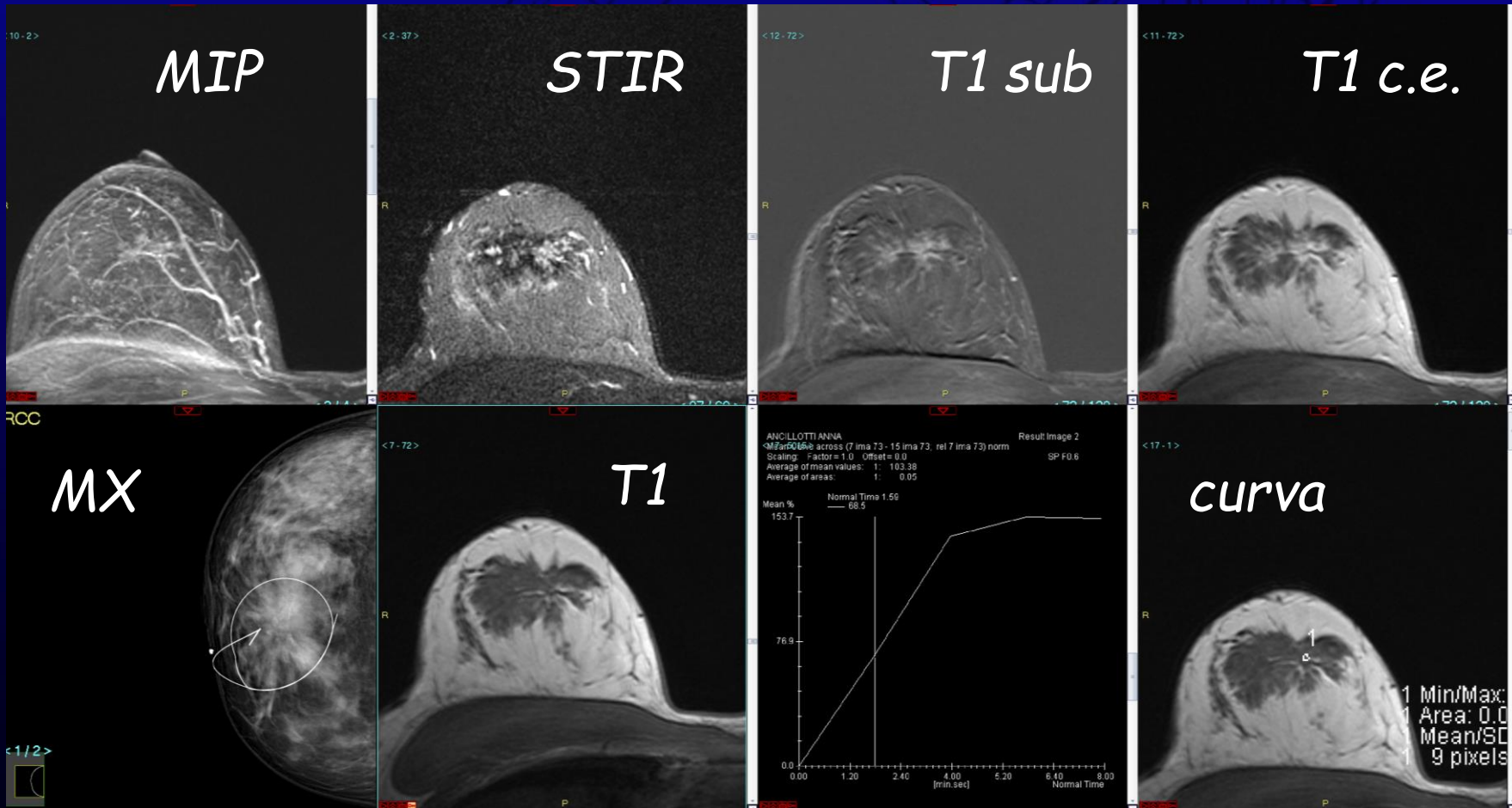




Caso B4



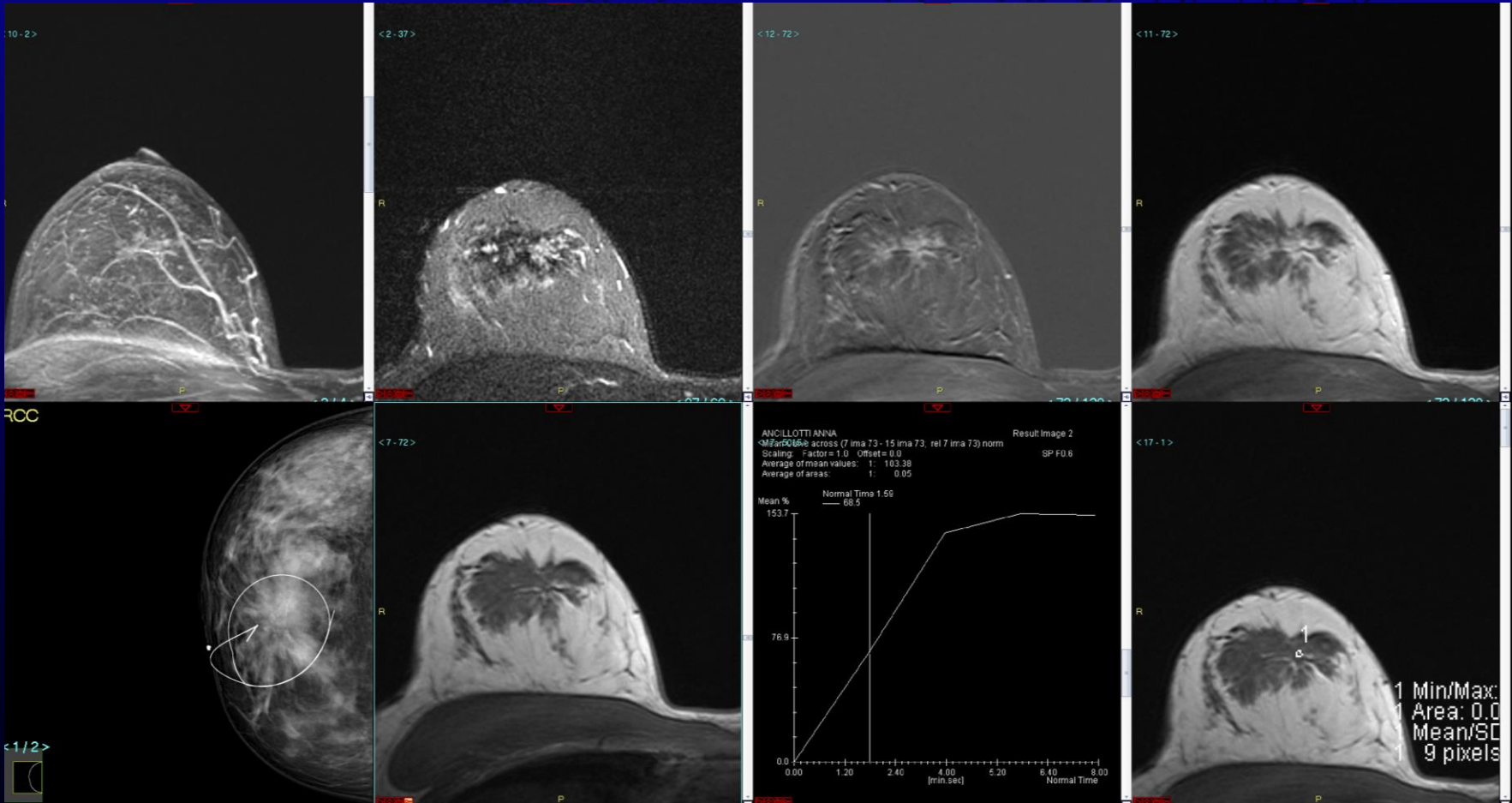
44aa
Bio ecoguidata radial scar



44aa

Bio ecoguidata radial scar

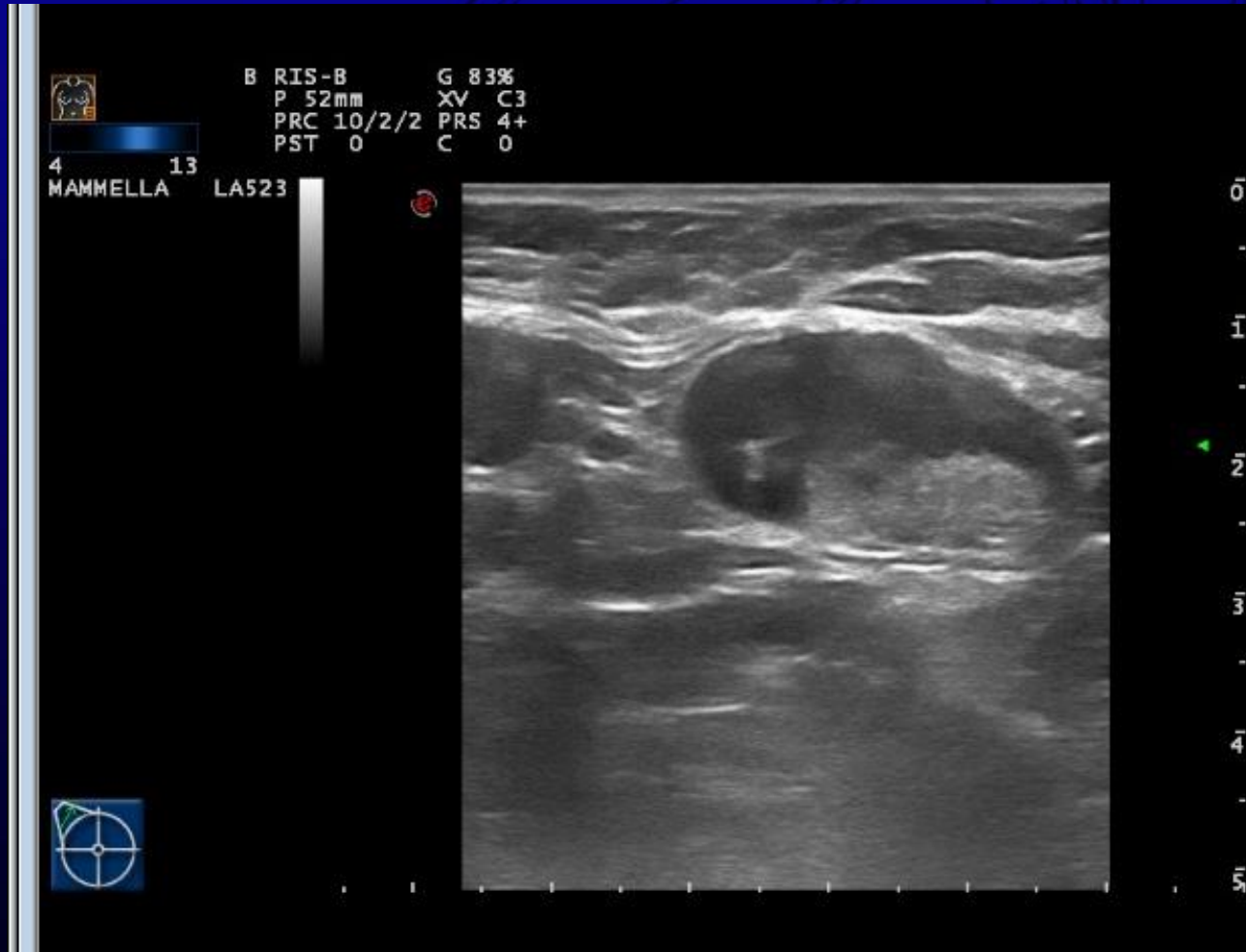
Chir radial scar + ADH



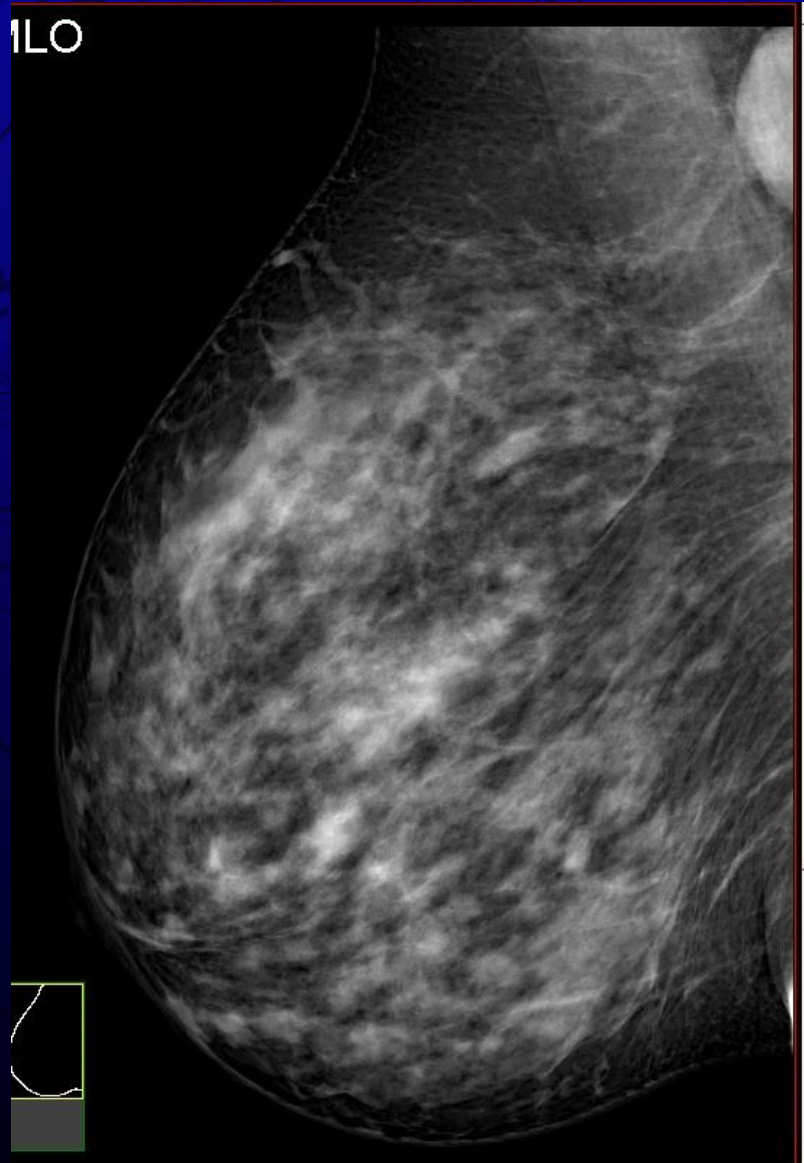
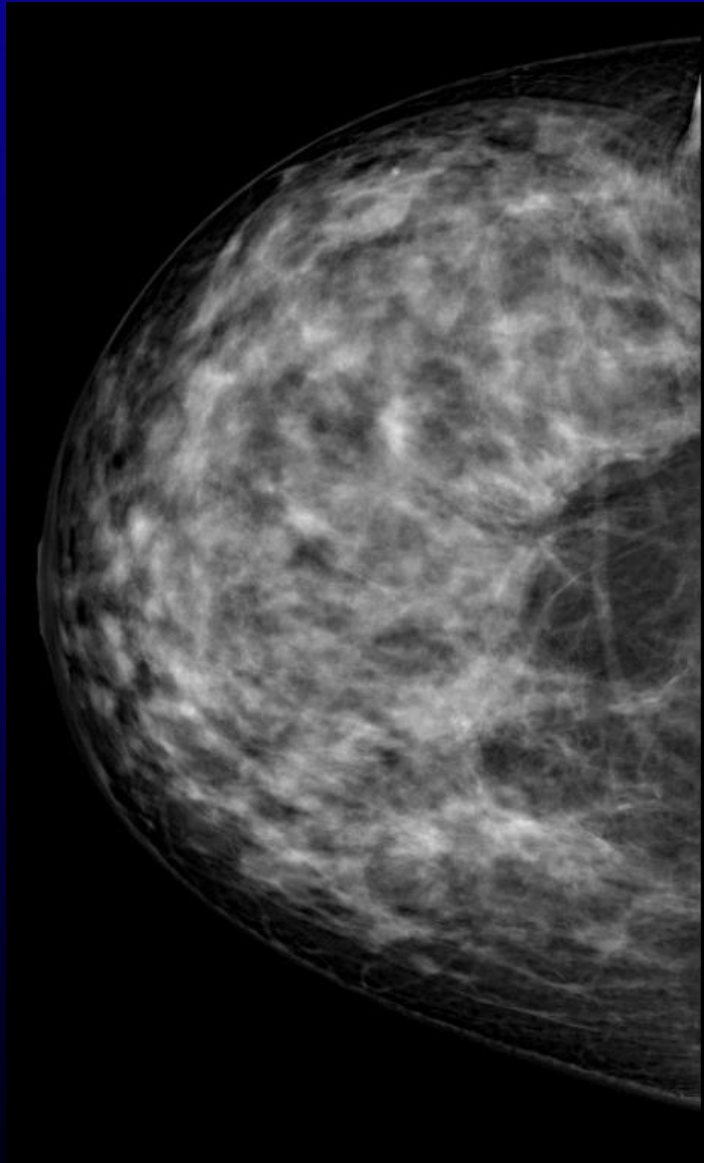
Caso C1



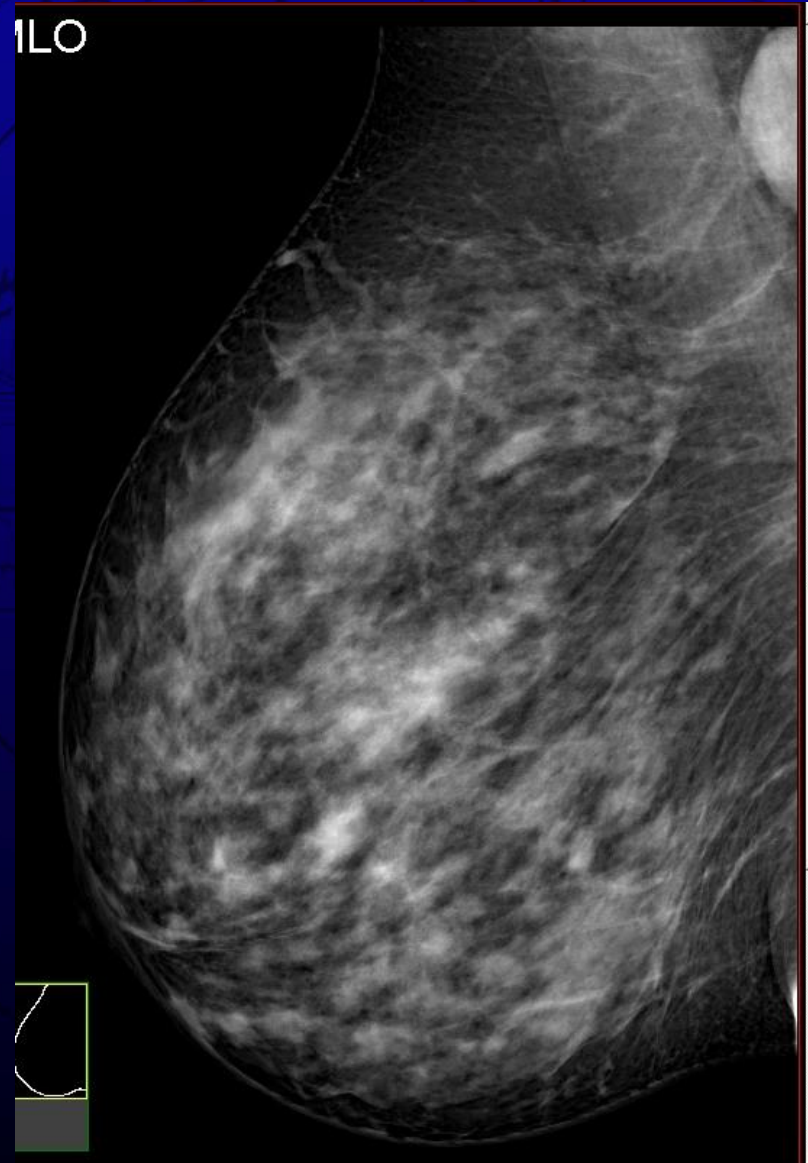
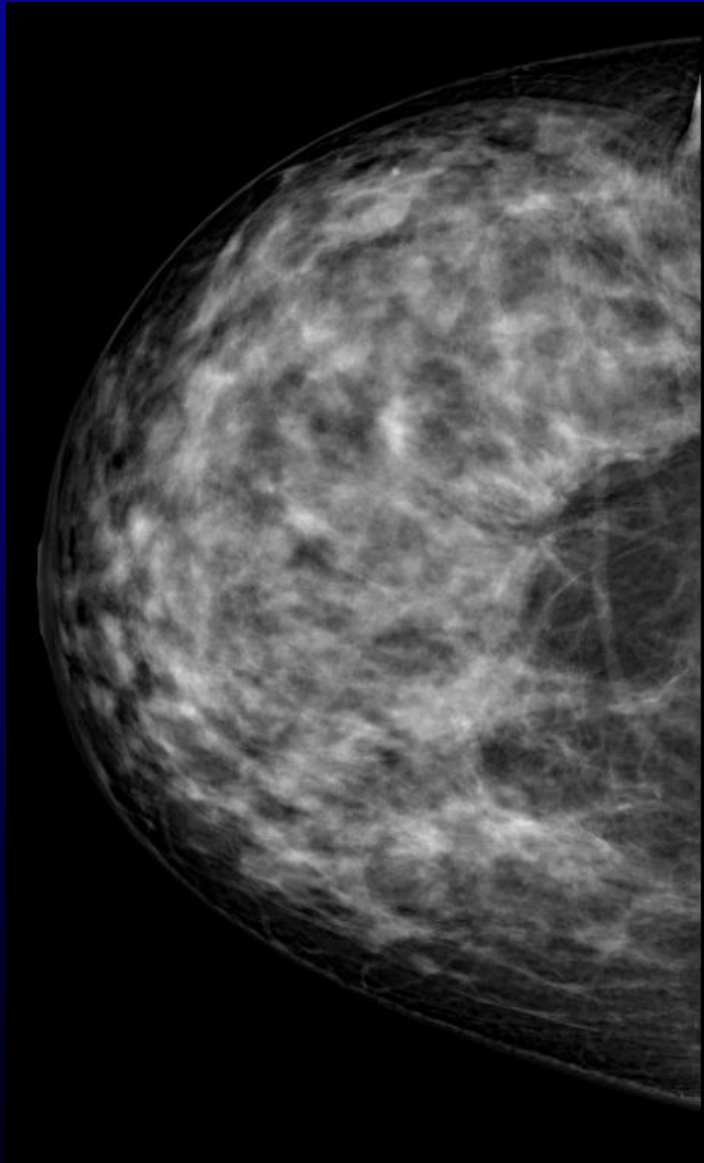
47aa ecografia per nodulo ascellare



Agobiopsia = metastasi primitività mammaria

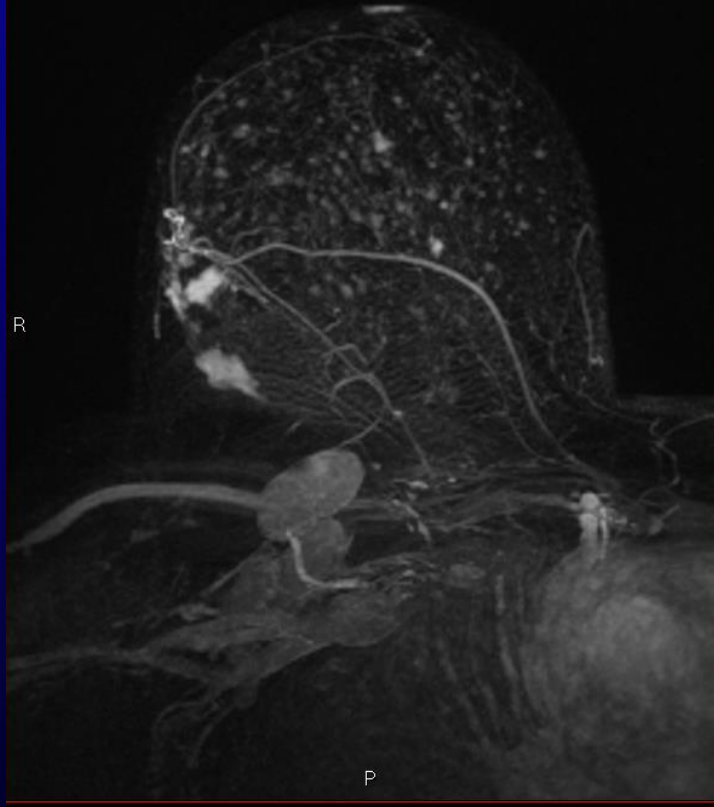


Mammografia negativa ed seconda ecografia negativa



<8-1>

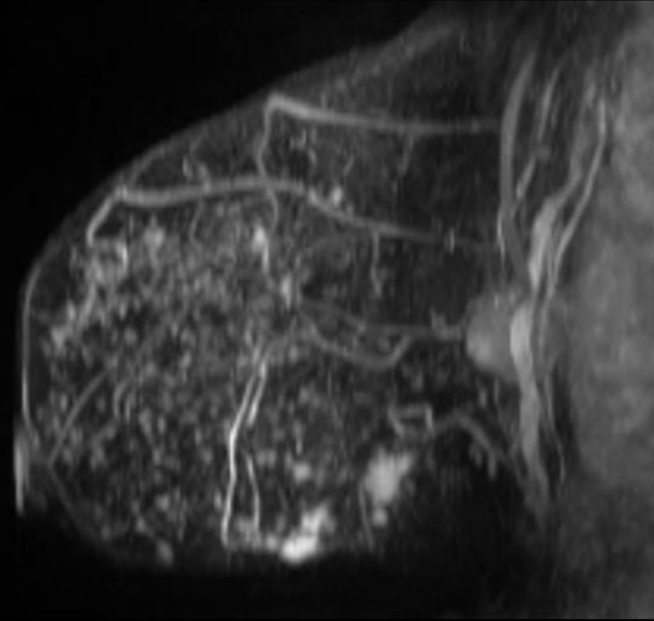
R



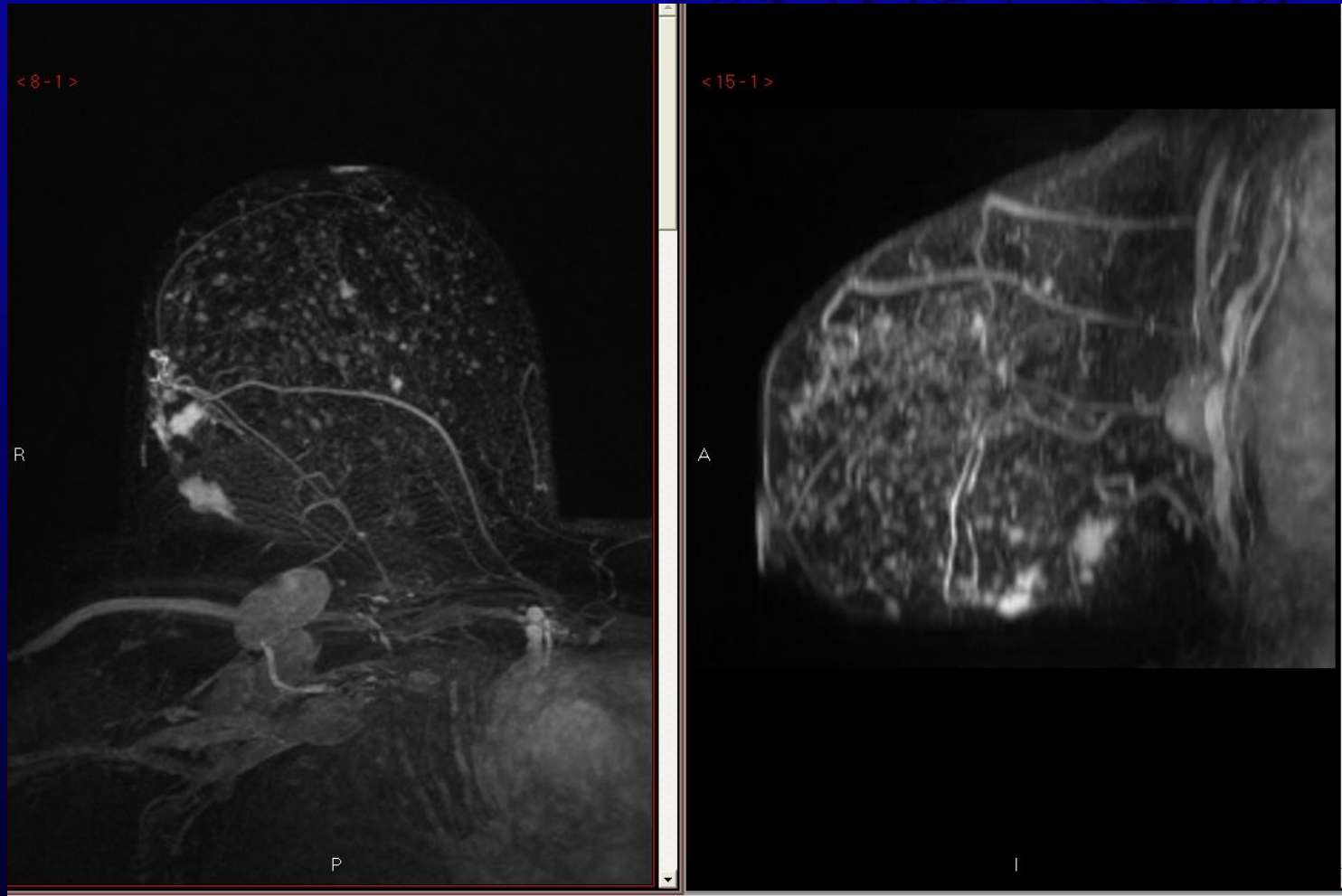
P

<15-1>

A

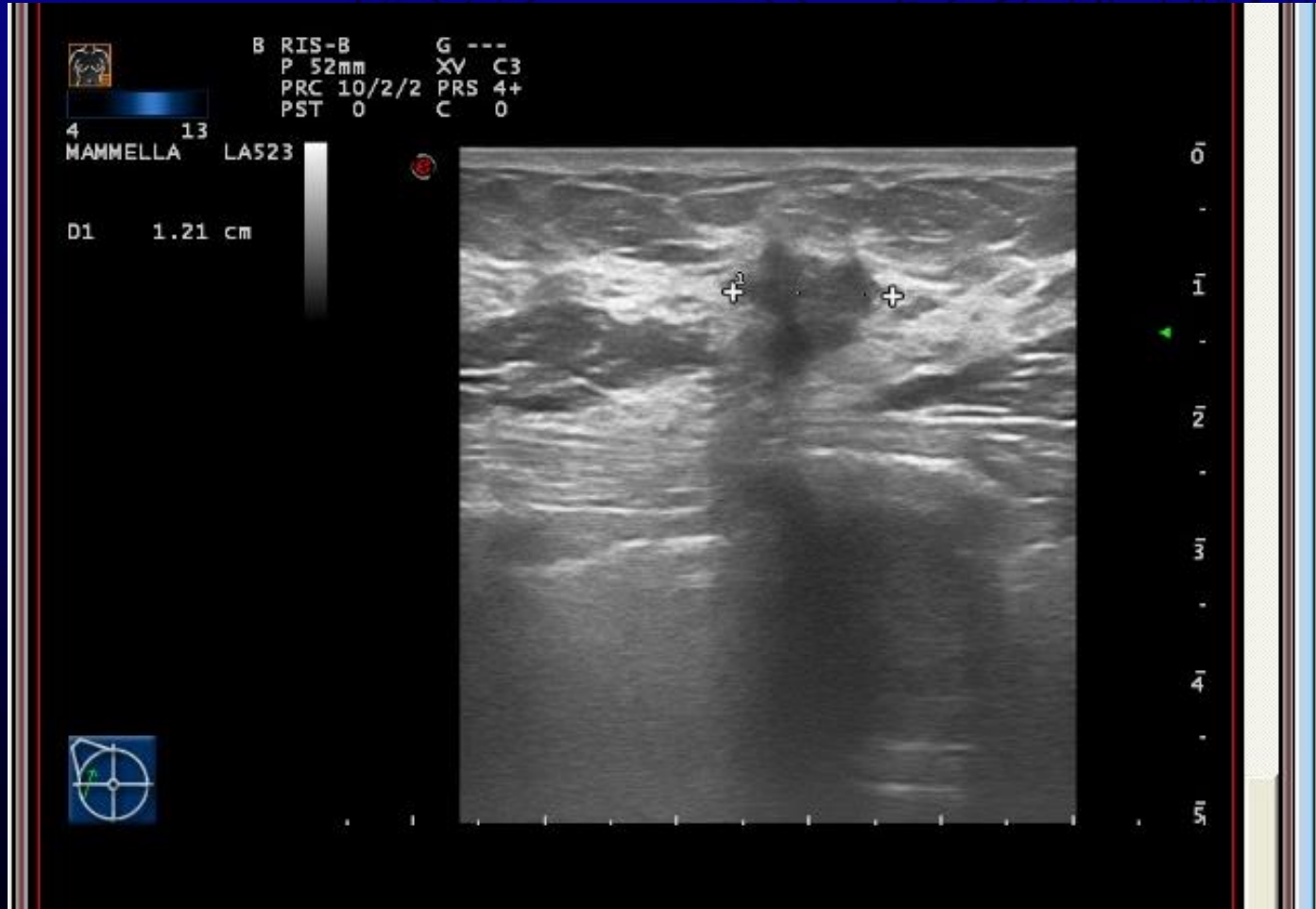

I

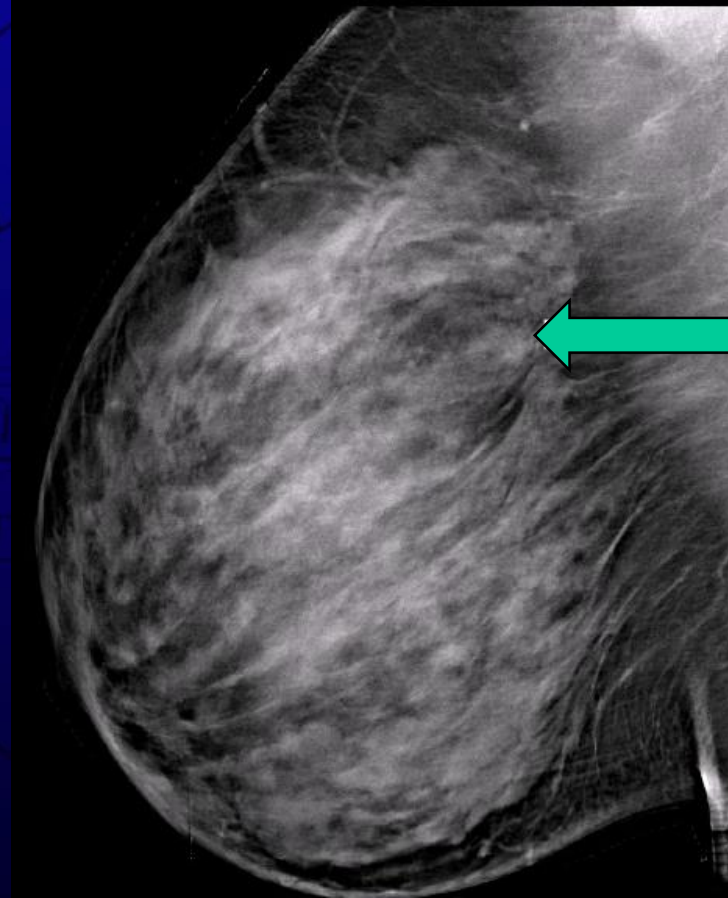
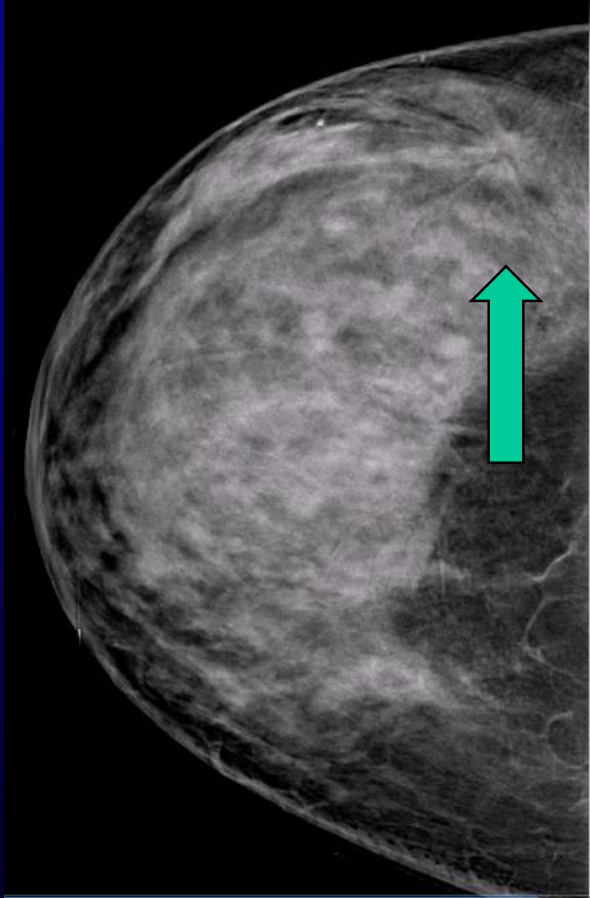


*Plurime lesioni tipo mass, multifocali, BI-RADS 5
Al QIE destro + Linfadenopatie*

Second look dopo RM
Agobiopsia
CDI



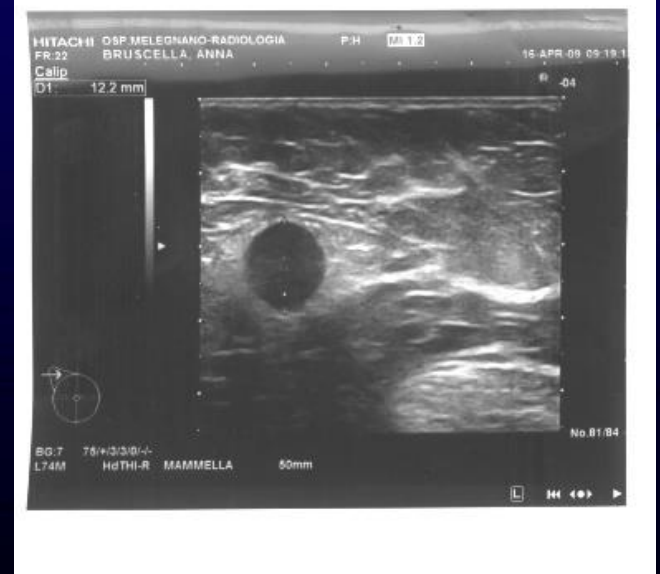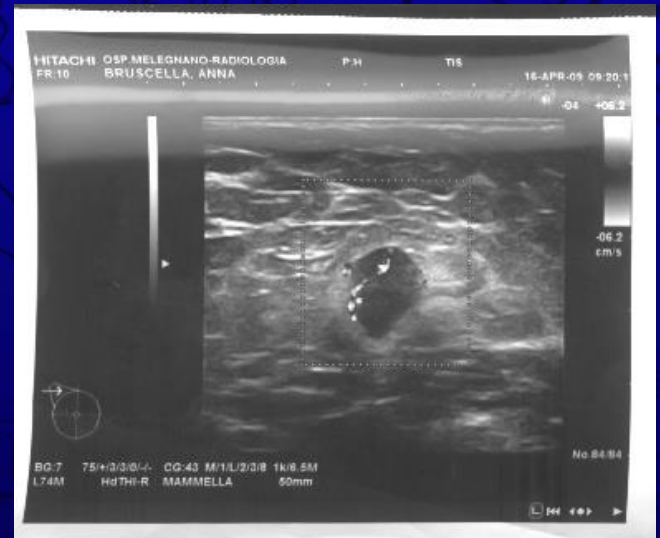Nota: e la Tomosintesi?



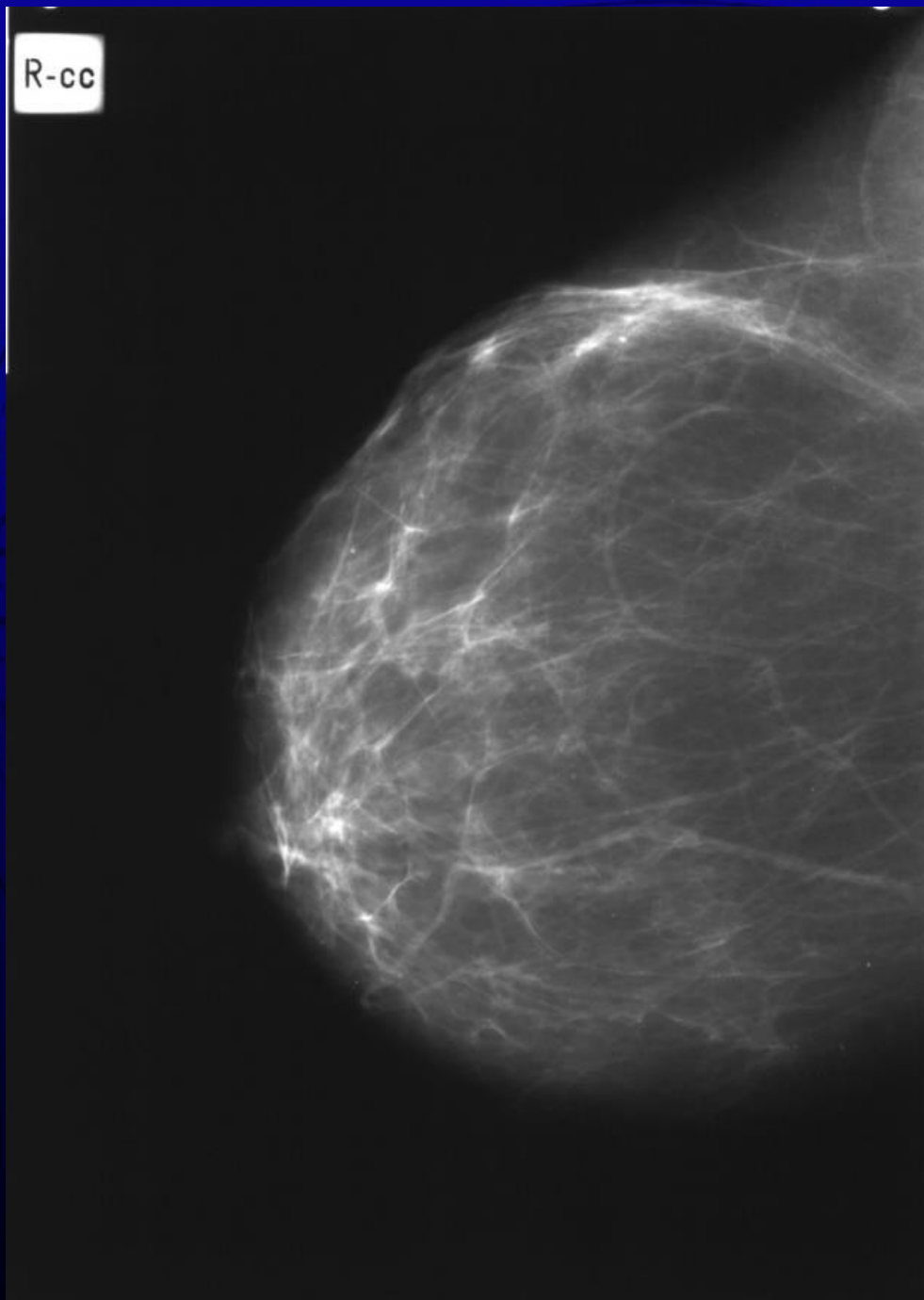
Caso C2



*Paziente di 59 anni
Mammografia screening negativa
Ecografia spontanea linfadenopatia*

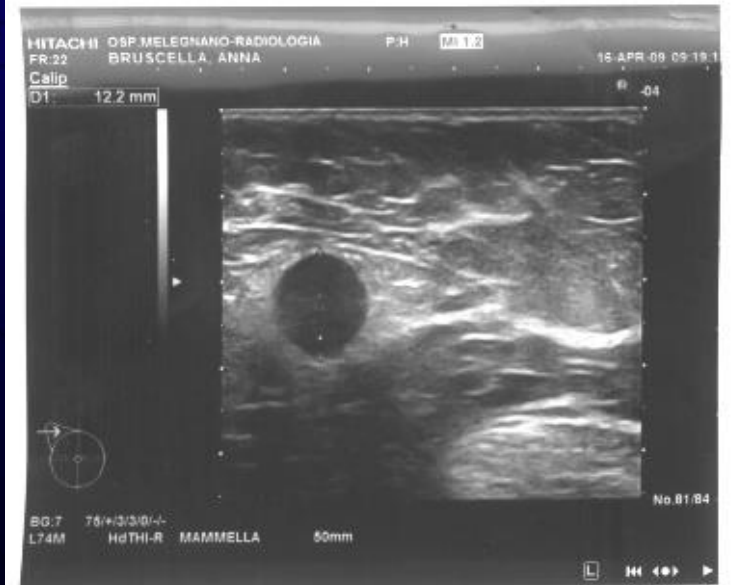
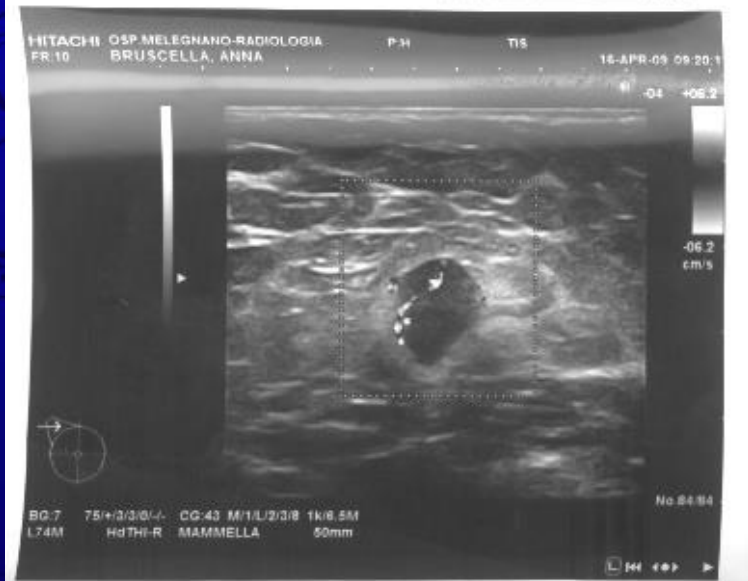


Mammografia



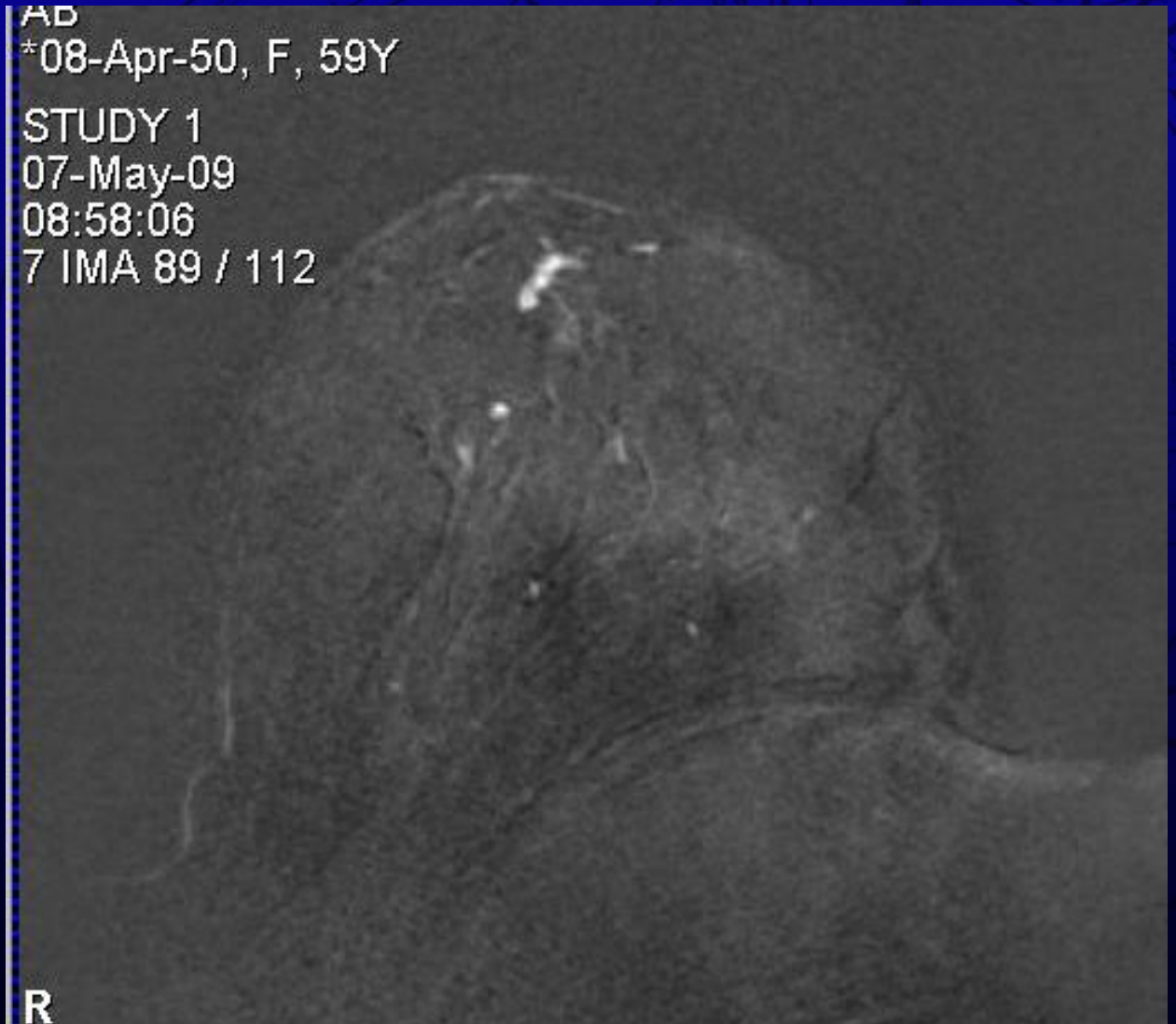*Agobiopsia /cito
LN:*

Mts da primitività mammaria



*RM: lesione
retroareolare
di 7 mm*

AD
*08-Apr-50, F, 59Y
STUDY 1
07-May-09
08:58:06
7 IMA 89 / 112



R

*RM: lesione
retroareolare
di 7 mm:
Agobiopsia
eco in second
look = CDI*

